

# Trisomy 18 and trisomy 21 mosaicism in a Down's syndrome patient

I M Thomas, R Sayee, Lincolon Shavanthi, Hegde Sridevi

## Abstract

**A male child with typical features of Down's syndrome and mosaicism of two trisomic cell lines, trisomy 18 (84%) and trisomy 21 (16%), is reported. Non-disjunction or anaphase lag of chromosomes 18 and 21 could be the cause.**

(J Med Genet 1994;31:418-419)

Mosaicism occurs in 10% of autosomal trisomies.<sup>1</sup> Double autosomal trisomy could be the result of double non-disjunction or anaphase lag or non-disjunction and anaphase lag during early embryonic mitotic division. Only two cases of trisomy 18/trisomy 21 have been reported so far.<sup>2,3</sup> This is the first report of double trisomy of this type in Down syndrome's from India.

## Case report

A 2½ year old boy, the first child of non-consanguineous parents, suspected of having Down's syndrome, was referred for chromosomal analysis. He had typical features of Down's syndrome except for a long nose.

On clinical evaluation the following were observed: weight 12 kg, height 91 cm, head circumference 44 cm, chest circumference 49 cm, and the internipple distance 11 cm.

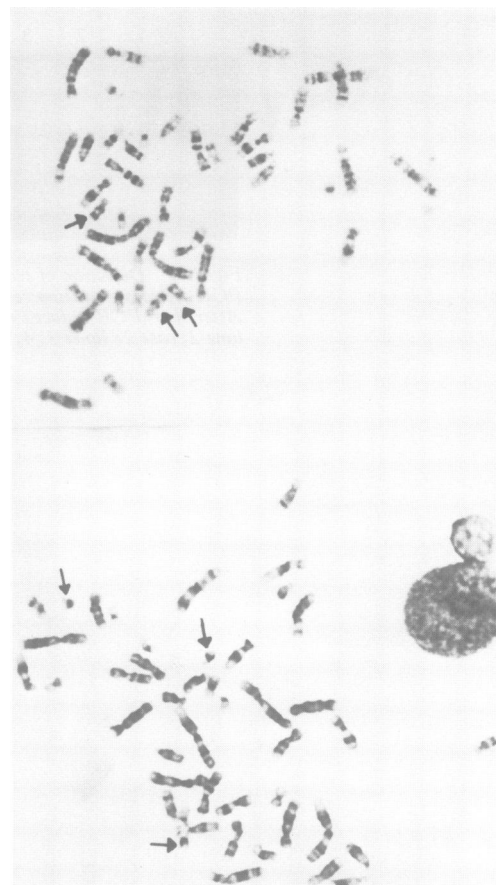
The Down's syndrome features were: muscular hypotonia, joint laxity, distension of the abdomen, flat occiput, upward slanting palpebral fissures, hypertelorism, highly arched palate, dry and rough skin, bilateral clinodactyly of the fifth fingers, and increased distance between the first and second toes.

Features of trisomy 18 observed included some of the features in common with Down's syndrome like growth retardation, poor sucking reflex, hypotonia, flat feet, slightly broader big toes, and prominent heel.

The dermatoglyphics were: bilateral simian crease, ulnar loop in hypothenar areas, a wide *atd* angle, and a single crease on the fifth finger. The finger print patterns were: ulnar loop on all the right hand fingers; the left thumb, middle, and little fingers had ulnar loops, the index finger had spiral whorl, and the ring finger had concentric whorl.

Malformations of the internal organs and rocker bottom feet were not present. All developmental milestones were delayed.

At conception his mother and father were aged 35 and 38 years. The pregnancy was uncomplicated and he was born by caesarean section. Family history was not significant.



Metaphase spreads of trisomy 18 (above) and trisomy 21 (below) from the proband. Arrows indicate the relevant chromosomes.

## CYTOGENETIC INVESTIGATIONS

GTG banded preparations of the proband showed 47 chromosomes in all the spreads. The patient's karyotype was 47,XY,+18/47,XY,+21. A total of 100 metaphase spreads was analysed out of which 84 cells were 47,XY,+18 and 16 were 47,XY,+21 (figure). Chromosomal analysis could not be done on the parents because of non-cooperation. A cell line is not available from this patient.

## Discussion

Mosaicism in Down's syndrome with trisomy 18 and trisomy 21 cell lines has been previously reported.<sup>2,3</sup> Marks *et al*<sup>2</sup> found trisomy 18 (20%)/trisomy 21 (80%) in lymphocytes, while Jenkins *et al*<sup>3</sup> observed trisomy 18 (18%) and trisomy 21 (82%) in lymphocytes but only trisomy 21 in fibroblasts. The suggested mechanisms leading to double trisomy mosaicism are (1) non-disjunction of both chromosomes 18 and 21; (2) anaphase lag of chromosomes 18

Division of Human Genetics, Department of Anatomy, St John's Medical College, Bangalore 560 034, India  
I M Thomas  
R Sayee  
L Shavanthi  
H Sridevi

Correspondence to Dr Thomas.

Received 26 November 1993  
Accepted for publication 13 December 1993

and 21; or (3) non-disjunction and anaphase lag of either chromosome 18 or 21. The proband's mother's age (35) could be a factor for non-disjunction.

The dermatoglyphic feature of trisomy 18 is a high frequency of arches on the fingertips. Dermatoglyphic features of Down's syndrome are a high frequency of ulnar loops on the fingertips, distal axial triradius, patterns on the hypothenar areas, and a simian crease. The last two features are also observed in trisomy 18. Dermatoglyphic features of trisomy 21 have been observed in the proband (ulnar loops on the fingers of the right hand; bilateral simian creases; distal axial triradius and pattern in the hypothenar area).

Trisomy 18 is a lethal condition, but in this

case because of the presence of trisomy 21 cell lines the expression of trisomy 18 has most probably become milder and survival longer. In spite of 84% of trisomy 18 the proband shows the Down's syndrome phenotype. This may be because he could have a variable percentage of trisomy 18 and 21 in his other tissues. The existence of genes for non-disjunction in humans is controversial and this case could provide evidence for this gene.

- 1 Warburton D, Yu C, Stein Z. Mosaic autosomal trisomy in cultures from spontaneous abortions. *Am J Hum Genet* 1979;30:609-18.
- 2 Marks JF, Wiggins KM, Spector BJ. Trisomy 21-trisomy 18 mosaicism in a boy with clinical Down's syndrome. *J Pediatr* 1967;71:126-8.
- 3 Jenkins MB, Kriel RL, Boyd C, Barnwell B. Trisomy 21 with 47,+18 lymphocyte cell line: double mitotic non-disjunction. *J Med Genet* 1978;15:395-8.