

- ³ Lurie IW, Lazjuk GI, Gurevich DB, Usoev SS. Genetics of the +9p syndrome. *Hum Genet* 1976;32:23-33.
- ⁴ Moteji T, Watanabe K, Nakamura N, Hasegawa T, Yanagawa Y. De novo tandem duplication 9p(p12-p24) with normal GALT activity in red cells. *J Med Genet* 1985;22:64-6.
- ⁵ Pison H, Sele B, Salvat J, Pasquier D, Jalbert H, Jalbert P. Mécanismes de formation des duplications à propos d'une

observation de duplication 10q22-q25. *Ann Genet (Paris)* 1982; 25:137-40.

Correspondence and requests for reprints to Dr T Mattina, Clinica Pediatrica, Città Universitaria, Viale A Doria 6, 95125, Catania, Italy.

A case of de novo interstitial deletion 3q

NORIKO OKADA*, TOMOKO HASEGAWA†, MAKIKO OSAWA*, AND YUKIO FUKUYAMA*

*Department of Pediatrics, Tokyo Women's Medical College, Tokyo; and †Department of Clinical Genetics and Cytogenetics, Shizuoka Children's Hospital, Shizuoka, Japan.

SUMMARY A rare chromosome abnormality consisting of interstitial deletion 3q was found in a malformed girl. Chromosome analysis using G and Q banding showed deletion of bands 3q12→3q21: 46,XX,del(3)(pter→q12::q21→qter). The clinical features of the proband included severe psychomotor retardation, craniofacial asymmetry, hypertelorism, epicanthus, high arched palate, progressive scoliosis, multiple skin pigmentations, and renal abnormalities. The parents had normal karyotypes.

Case report

The proband, an eight year old girl, was the first child of unrelated, healthy parents, both of whom were 24 years of age at the time of her birth. She was born after an uncomplicated 40 week pregnancy and the delivery was normal. Her birth weight was 2600 g, length 47 cm, head circumference 30 cm, and chest circumference 30.5 cm. Mild asphyxia was present at birth. The umbilical cord was only 28 cm in length and weighed 400 g. Severe developmental retardation was present: she had head control at five months, sat alone at 20 months, and walked without support at seven years old. At the age of eight years she was unable to speak any meaningful words. Scoliosis was observed at the age of three months and developed into progressive, double structural scoliosis, despite conservative therapy (fig 1). It was convex to the left in the thoracic area and to the right in the lumbar area. She could maintain a standing position, but found it impossible to avoid bending forward. She had considerable growth

retardation. At eight years of age her height was 103.5 cm (-4.3 SD), weight 17.2 kg (-2.0 SD), head circumference 51.5 cm (-0.14 SD), and chest circumference 60.5 cm (-0.05 SD). The craniofacial appearance was abnormal (fig 2). Her head showed plagiocephaly with increased right frontal and left occipital diameter, but there was no palpable ridge along any cranial suture. Her face was asymmetrical and midfacial dysplasia was present. She had hypertelorism, epicanthic folds, a high arched palate, and a long pointed chin. Mild generalised hypotonia and joint contractures were observed. Freckle-like pigmentations were scattered on the face and forearms. Dermatoglyphs showed no specific abnormalities. Intravenous pyelography showed a renal anomaly involving incomplete duplication of the collecting system on the right side. There was no abnormality of the other internal organs including the cardiovascular system. A muscle biopsy from the quadriceps femoris revealed only type II fibre atrophy. Abnormal laboratory findings included anaemia with iron deficiency and excess of serum IgG. Functional tests of the kidney, liver, and thyroid were normal. Serum level of transferrin was not decreased.

CYTOGENETIC FINDINGS

Chromosome analysis of the proband from peripheral lymphocytes showed deletion of the long arm of chromosome 3 (fig 3). Using high resolution G and Q banding, the deleted portion of chromosome 3 was found to be q12→q21:46,XX,del(3)(pter→q12::q21→qter). The karyotypes of the parents were normal. The origin of the chromosome abnormality of the proband could not be established, because Q heteromorphism of chromosome 3 in the proband showed no difference in size or staining intensity.

Received for publication 20 November 1985.

Revised version accepted for publication 20 February 1986.

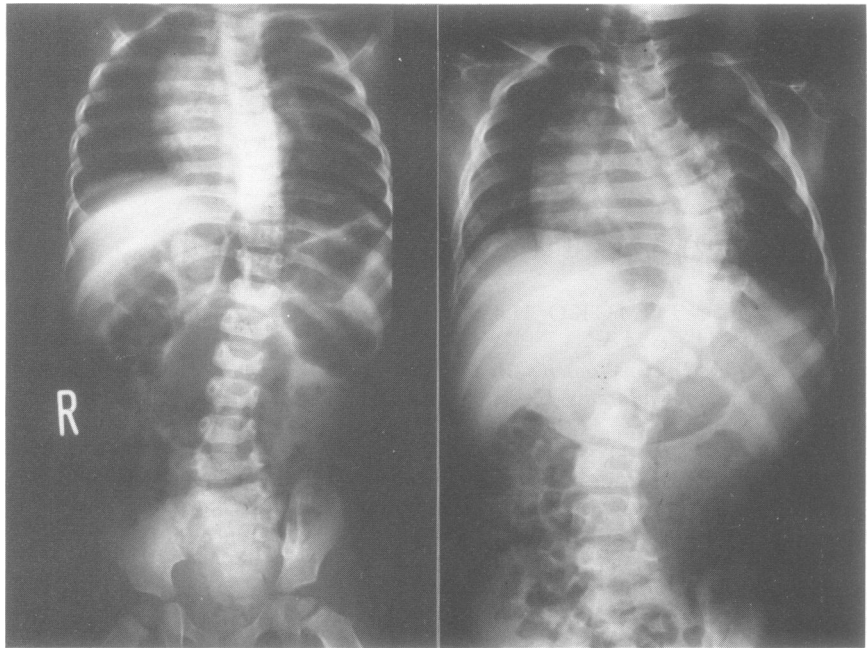


FIG 1 X rays of proband's spine. (Left) Taken at 18 months of age showing a 24° curvature to the left of the thoracic spine and a 15° curvature to the right of the lumbar spine, determined by Cobb's method. (Right) Taken at eight years of age showing a curvature of 57° in the thoracic spine and 57° in the lumbar spine. No other vertebral malformation was found.

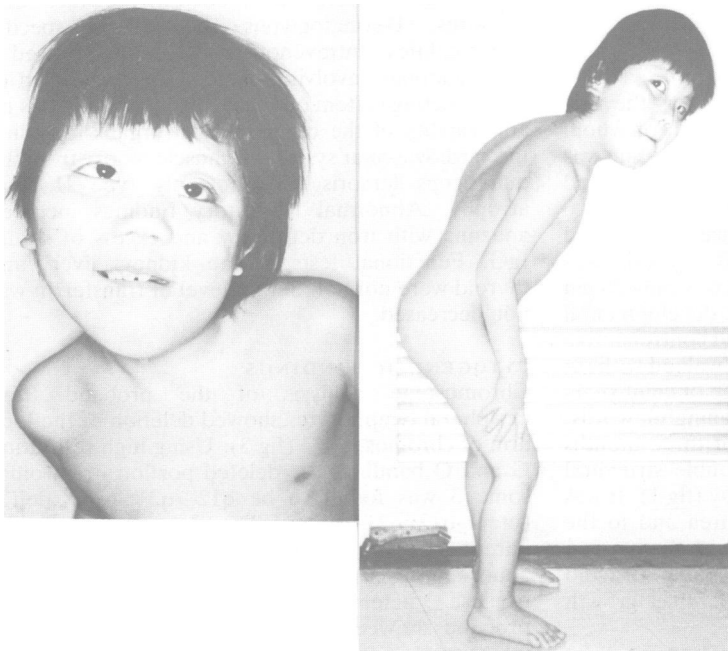


FIG 2 Clinical appearance of the proband at eight years of age. Note oval, asymmetrical face, long pointed chin, scattered pigmentations, multiple joint contractures, scoliosis, and leaning posture.

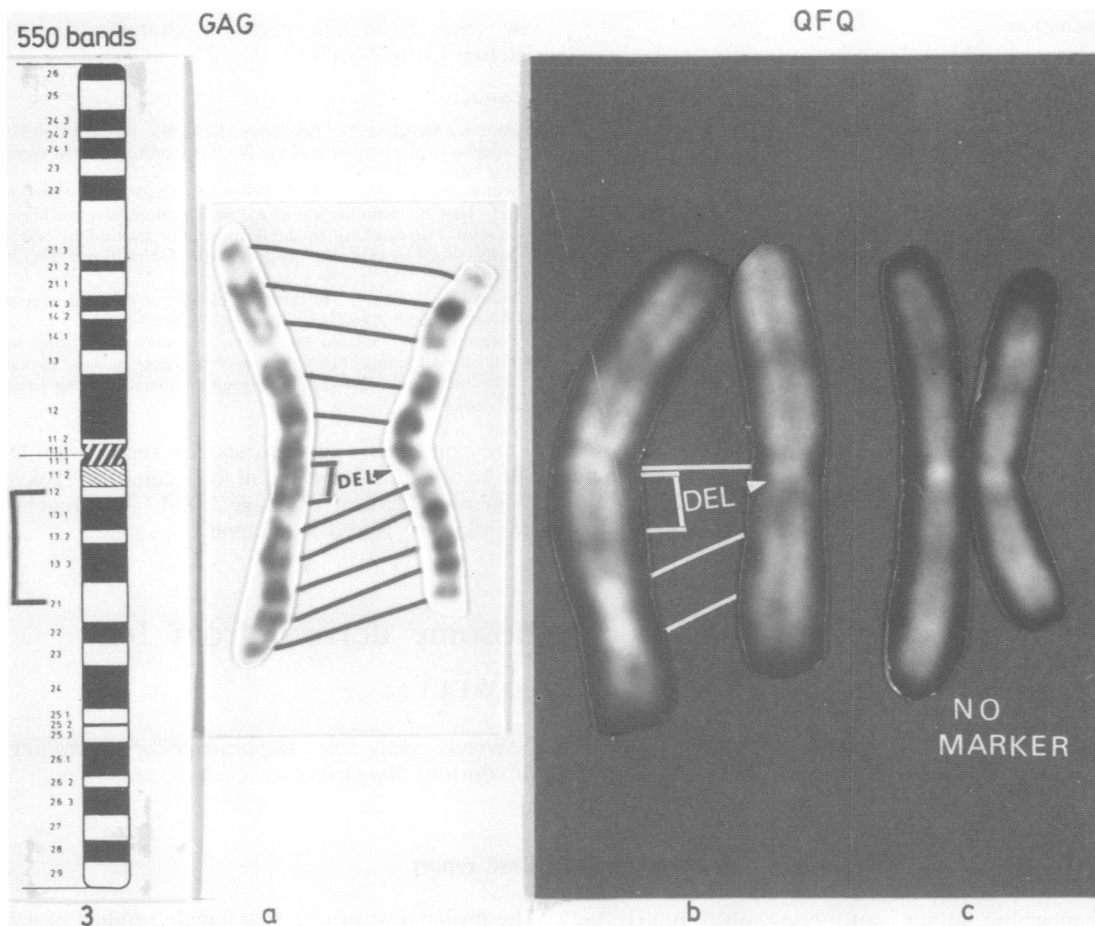


FIG 3 (a) High resolution G banding pattern showing a deletion of 3q12→q21, (b) Q banding pattern of the proband's chromosomes 3. (c) Absence of Q heteromorphic variant of chromosome 3 of the proband.

TABLE Main features of patients with partial deletion of chromosome 3q.

| | Present case | Arai <i>et al</i> ¹ | Williamson <i>et al</i> ² | Martolf and Ray ³ | Franceschini <i>et al</i> ⁴ |
|--------------------------|-----------------|---|--------------------------------------|---|--|
| Sex | F | M | M | F | F |
| Age (y) | 8 | 58 h | 13 | 1 | 20 |
| Birth weight (g) | 2600 | 1760 | 2039 | 2041 | |
| Gestational age | 40 w 3 d | 41 w 3 d | 36 w | 35 w | |
| Chromosome deletion | del(3)(q12→q21) | del(3)(q12→q21) | del(3)(q22·1→q24) | del(3)(q23→q25) | del(3)(q23→q26) |
| Growth retardation | + | + | + | + | + |
| Psychomotor retardation | + | + | + | + | + |
| Plagiocephaly | + | — | — | — | — |
| Midfacial dysplasia | — | + | + | + | + |
| Scoliosis | + | | | | |
| Joint contractures | + | | + | + | |
| Skin pigmentation | + | | | — | + |
| Renal anomaly | + | — | | | |
| External genital anomaly | — | + | | — | |
| Others | | Holoprosencephaly, cleft lip and palate | Syndactyly, abnormal dermatoglyphs | VSD, scaphocephaly, cleft lip, strabismus (right eye) | Brachydactyly, deafness |

Discussion

Only one case of similar deletion of bands 3q12→3q21 has previously been reported by Arai *et al.*¹ Other reports of 3q deletion had various deleted portions, such as 3q22.1→q24,² 3q23→q25,³ and 3q23→q26⁴ (table). The main clinical features of the present case were severe psychomotor retardation, craniofacial asymmetry, midfacial dysplasia, hypertelorism, epicanthus, high arched palate, long pointed chin, scoliosis, joint contractures, multiple skin pigmentations and renal anomaly. The case of Arai *et al.*¹ had different anomalies from our case including holoprosencephaly, arhinia, and cleft lip and palate. The proband survived only 58 hours after birth. This clinical inconsistency for the same chromosome deletion might be the result of individual difference of the recessive genes on the normal chromosome portion corresponding to the deletion or various environmental effects or both. There are still too

few cases to define common characteristics of deletion (3)(q12→q21).

References

- ¹ Arai K, Matukiyo H, Takazawa H. A case report of partial deletion of the long arm of the No 3 chromosome. *Med Genet Res* 1982;4:1-4.
- ² Williamson RA, Donlan MA, Dolan CR, Thuline HC, Harrison MT, Hall JG. Familial interstitial translocation of a portion of 3q into 11q resulting in duplication and deletion of region 3q22.1→q24 in different offspring. *Am J Med Genet* 1981;9:105-11.
- ³ Martsolf JT, Ray M. Interstitial deletion of the long arm of chromosome 3. *Ann Genet (Paris)* 1983;26:98-9.
- ⁴ Franceschini P, Silengo MC, Davi G, Bianco R, Biagioli M. Interstitial deletion of the long arm of chromosome 3 in a patient with mental retardation and congenital anomalies. *Hum Genet* 1983;64:97.

Correspondence and requests for reprints to Dr Noriko Okada, Department of Pediatrics, Tokyo Women's Medical College, 8-1 Kawata-cho, Shinjuku-ku, Tokyo 162, Japan.

Interstitial deletion and ring chromosome derived from 16q

CELESTE M KRAUSS*, DEBORAH CALDWELL†, AND LEONARD ATKINS†

*The Embryology-Teratology Unit, The Children's Service, and †the Department of Pathology, Massachusetts General Hospital, Harvard Medical School, Boston, Massachusetts, USA.

SUMMARY An interstitial deletion of 16q was identified in an infant with failure to thrive, dysmorphic facies, and congenital heart defects. The mother of this infant had a similar deletion of 16q with ring formation of a fragment presumed to be derived from the deleted portion of 16q. We discuss these cases and compare them to other reports of 16q deletions.

It has been suggested that there is a distinctive 'deletion 16q syndrome'¹ which is associated with 16q12.2→q13. We have studied two members of a family: the proband with 46,XX,del(16)(pter→q11.1::q13→qter) and her mother with 47,XX,del(16)(pter→q11.1::q13→qter)+r(16). Although the association of multiple congenital anomalies with deletions in this region is well known,²⁻⁷ this is the first report of an inherited 16q deletion.

*Present address: Cytogenetics Laboratory, Brigham and Women's Hospital/Harvard Medical School Department of Obstetrics and Gynecology, Boston, Massachusetts, USA.

Received for publication 16 December 1985.

Revised version accepted for publication 10 March 1986.

Case report

The proband was the 2.3 kg female product of a 22 year old G1 PO AbO woman. Gestation was thought to be 36 weeks, but the LMP date was not reliable. The pregnancy, delivery, and neonatal course were without complication. At three weeks of age, a 3/6 systolic ejection murmur was evaluated. Echocardiogram showed bicuspid aortic and pulmonic valves without severe obstruction. At four months the proband had failure to thrive with poor feeding tolerance resulting in vomiting and diarrhoea; her weight at this time was 3.5 kg (50th centile for a newborn infant),⁸ the length was 57.5 cm (50th centile for two months old), and the head circumference was 36 cm (50th centile for two weeks old). She was a small, dysmorphic child. The craniofacial features were remarkable for midfacial hypoplasia, a high forehead with prominent metopic ridge, a broad flat nasal bridge, and a small nose with anteverted nostrils. The intercanthal distance was 2.5 cm (97th centile) and the outer canthal distance 6.5 cm (75th centile). The palpebral fissures had an antimongoloid slant, the ears were low set and