

# Autosomal dominant simple microphthalmos

Enzo Maria Vingolo, K Steindl, Renato Forte, Luigi Zompatori, Alessandro Iannaccone, Antonella Sciarra, Giuseppe Del Porto, Mario Rosario Pannarale

## Abstract

**Congenital bilateral microphthalmos is a rare malformation of the eye, which ranges from extreme to mild reduction of total axial length. Microphthalmos may occur as an isolated ocular abnormality or as part of a systemic disorder, and different classifications of the condition have been attempted.**

**We describe a large pedigree with 14 persons in four generations affected with bilateral microphthalmos without other ocular or systemic signs. An autosomal dominant trait with complete penetrance is proposed. Five subjects underwent a complete ophthalmological evaluation. The total axial length was measured by A scan ultrasonography in all persons. Ultrasonography showed a reduction of the total axial length (range 18.4–19.7 mm) and a reduced vitreous cavity length (range 11.4–13.5 mm) in all investigated patients. All the patients had microcornea (range 8–9.7 mm). No other ocular anomalies or associated systemic malformations were found.**

**A review of published reports also suggests that simple, partial, posterior, pure microphthalmos and nanophthalmos are similar clinical entities sharing total axial length and vitreous cavity length reduction. Therefore, the term simple microphthalmos is proposed to identify these clinical conditions.**

(J Med Genet 1994;31:721-725)

Congenital bilateral microphthalmos is a rare malformation of the eye and ranges from mild to extreme reduction of total axial length (TAL). Microphthalmos may occur as an isolated ocular abnormality, and different classifications of this condition have been attempted. Simple microphthalmos,<sup>1,2</sup> pure microphthalmos,<sup>3</sup> partial microphthalmos,<sup>1</sup> posterior microphthalmos,<sup>4-7</sup> and nanophthalmos<sup>8-29</sup> are terms used to describe a non-syndromic clinical pattern in which the eye is essentially normal except for its short TAL. In the past, the diagnosis was based on clinical signs.<sup>3-8-11-13-16-19-21-24-25-28</sup> The introduction and recent improvement of ultrasonographic techniques<sup>2-4-7-14-17-20-22</sup> has allowed a more precise diagnosis, contributing to an accurate assessment of the anterior-posterior segment ratio of the eye.<sup>2,14</sup>

Most cases of non-syndromic microphthalmos are sporadic<sup>15-23-29</sup> and only a few familial cases with autosomal recessive inheritance have been described.<sup>5-7-13-18-20-23-26</sup> Ped-

igrees with autosomal dominant inheritance have been reported by François,<sup>30</sup> Romano *et al*,<sup>31</sup> and Hussel,<sup>32</sup> but in these families the affected subjects were often mentally retarded. Only Bateman<sup>8</sup> observed a three generation family with non-colobomatous microphthalmos dominantly inherited with incomplete penetrance and variable expressivity, the clinical features ranging from unilateral microphthalmos to clinical bilateral anophthalmos. Sjögren and Larsson<sup>23</sup> also described one large and two small pedigrees with autosomal dominant inheritance, although male to male transmission was not observed.

We describe a five generation pedigree with 14 subjects affected with bilateral microphthalmos not associated with other ocular or systemic signs. After Sjögren and Larsson's first report in 1949,<sup>23</sup> this is, to the best of our knowledge, the second description of a large pedigree showing autosomal dominant inheritance with complete penetrance. This study also prompted a review of published reports to verify if microphthalmos and nanophthalmos are the same clinical entity.

## Materials and methods

The pedigree, shown in fig 1, with 14 affected subjects in five generations, was ascertained from a proband affected with simple microphthalmos. Four further family members were investigated as follows. (1) Detailed medical history to identify: age of onset; ocular signs or symptoms that have been associated with the disorder; ocular medical and surgical procedures; systemic disorders. (2) Ophthalmological evaluation involved: best corrected far and near visual acuity (BCVA) with Pannarale's astigmatic charts<sup>33</sup>; assessment of motility and binocularity; examination of the anterior segment by slit lamp biomicroscopy; intraocular pressure by applanation tonometry and, automatically, by Keeler Pulsair (Keeler Instruments Inc, Broomell, USA); fundus examination by binocular indirect ophthalmoscopy and biomicroscopy; TAL, anterior chamber depth, lens thickness, and length of the vitreous cavity were measured on the anteroposterior axis with A scan ultrasonography. Particularly, the Ophthalmoscan Mini-A (Alcon/Biophysic, Clermont-Ferrand, France) was used with a transducer probe with a contact technique, except for the anterior chamber depth which was measured with the immersion technique. Two measurements were performed for each eye. The eye length was expressed in mm, using different ultrasound velocities: 1532 m/s in the anterior chamber, 1641 m/s in the lens, and 1532 m/s in the vitreous.<sup>14</sup> Anterior chamber depth was calculated from the

Institute of Ophthalmology, University of Rome 'La Sapienza', Italy  
E M Vingolo  
R Forte  
L Zompatori  
A Iannaccone  
M R Pannarale

Medical Genetic Section, Experimental Medicine Department, University of Rome 'La Sapienza', Italy  
K Steindl  
A Sciarra  
G Del Porto

Correspondence to Dr Forte, Via del Calice 42, I-00178 Rome, Italy.

Received 9 December 1993  
Revised version accepted for publication 30 March 1994

Table 1 Summary of the clinical and biometric findings in five patients with simple microphthalmos

Pedigree No	Age	Sex	Eye	Visual acuity	Refraction	Ocular status	A scan ultrasonographic data*				
							CD MV 11.34 (SD 0.42)	ACD 2.91 (SD 0.31)	LT 4.3 (SD 0.29)	VCL 15.26 (SD 0.69)	TAL 23.37 (SD 0.75)
III-5	59	M	R	LP	UN	Nystagmus, glaucoma, corneal opacification	8	UN	UN	UN	UN
			L	LP	UN	Nystagmus, glaucoma, corneal opacification	8.6	UN	UN	UN	UN
III-6	65	M	R	LP	UN	Nystagmus, glaucoma, corneal opacification	9.5	UN	UN	UN	UN
			L	LP	UN	Nystagmus, glaucoma, corneal opacification	9.7	UN	UN	UN	UN
IV-5	31	M	R	HM	+9+2/95	Hypertensive uveitis, cataract, thickened choroid	8	2.6	4.2	12.6	19.4
			L	HM	+8+1.5/80	Hypertensive uveitis, cataract, thickened choroid	8	2.6	4.2	12.1	18.9
IV-12	27	F	R	0.7	+4+2/110	Hypertensive uveitis, cataract, thickened choroid	8.8	2	4.3	13.4	19.7
			L	0.4	+3+1.5/80	Hypertensive uveitis, cataract, thickened choroid	8.9	2	4.2	13.5	19.7
V-8	11	F	R	1	+3/100	Normal	8	2.8	4.2	11.4	18.4
			L	1	+4.5/80	Normal	8	2.8	4.2	11.4	18.4

\* All measurements are expressed in millimeters. LP=light perception. HM=hand motion. UN=undefined. MV=mean normal reference values. CD=corneal diameter. ACD=anterior chamber depth. LT=lens thickness. VCL=vitreous cavity length. TAL=total axial length.

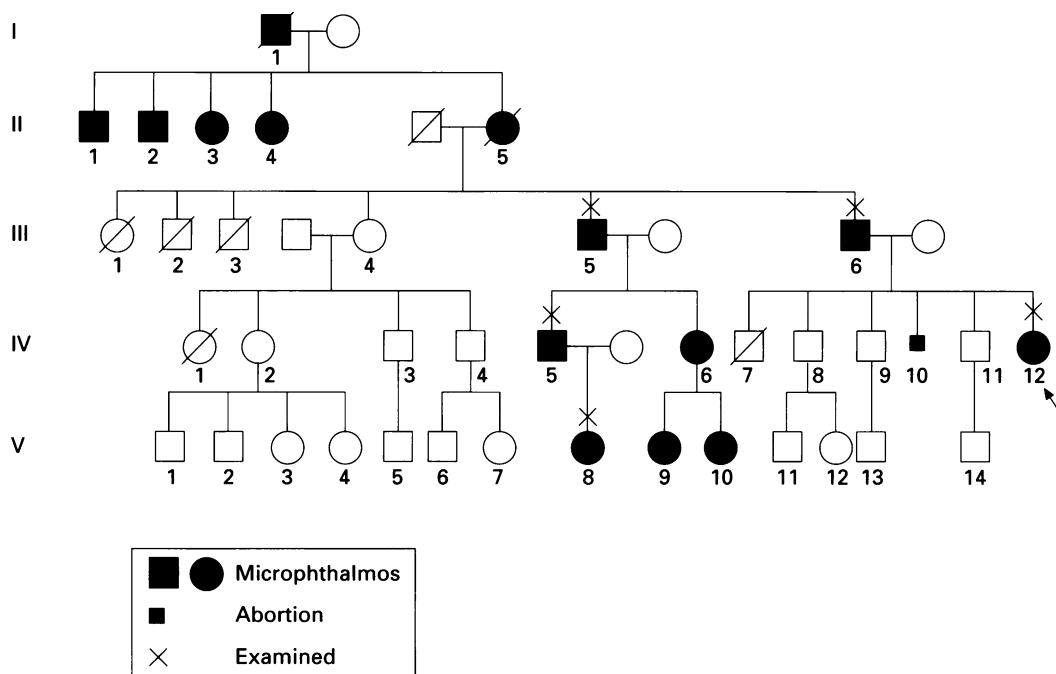


Figure 1 Pedigree with simple microphthalmos showing autosomal dominant inheritance with complete penetrance.

posterior edge of the corneal spike to the leading edge of the anterior lens spike; lens thickness was measured from the leading edge of the anterior lens spike to the leading edge of the posterior lens spike. Anterior segment length was measured from the anterior edge of the corneal spike to the posterior edge of the lens spike. The vitreous cavity length (posterior segment) was calculated from the leading edge of the posterior lens spike to the leading edge of the retinal spike. Ultrasonographic normal ocular values from François and Goes<sup>14</sup> and Weiss *et al*<sup>2</sup> were considered for comparison.

### Results

The five generation pedigree reported here shows autosomal dominant inheritance of the disease with complete penetrance (fig 1). Five affected subjects, ranging between 8 and 64 years of age, have been examined clinically; the diagnosis of simple microphthalmos has been ultrasonographically confirmed in three cases,

whereas coarse nystagmus precluded ultrasonographic evaluations in the remaining two cases (patient III-5 and III-6). No patient showed systemic symptoms or signs. The ophthalmological data for each patient are summarised in table 1.

#### PATIENT III-5

This 59 year old male had onset of his first symptoms in the first decade of life. He experienced complications of glaucoma and progressive loss of visual acuity. Light perception in OU occurred at about 15 and jerk nystagmus ensued. Anterior segment examination showed a reduced corneal diameter (RE: 8 mm; LE: 8.6 mm); other ophthalmological evaluations were precluded by corneal opacification. Ultrasonography was not performed because of the jerk nystagmus.

#### PATIENT III-6

This 65 year old male presented virtually the same clinical history and condition as patient

Table 2 Comparison of the biometric data of simple microphthalmos

Reference	Biometric findings					Lens:eye ratio	Inheritance	Diagnosis
	CD	ACD	LT	VCL	TAL			
3	NR	NR	Normal	NR	16-18.5	NR	NR	Nanophthalmos
19	5-5.5	NR	Normal	NR	19	NR	NR	Nanophthalmos
9	10	NR	NR	NR	13-17	NR	NR	Nanophthalmos
11	<11.1	<2.45	NR	NR	NR	NR	NR	Nanophthalmos
13	NR	NR	NR	NR	15-16.25	NR	AR	Nanophthalmos
17	10-10.7	NR	NR	NR	15-18	11-32%	NR	Nanophthalmos
10	NR	NR	NR	NR	15-20	NR	NR	Nanophthalmos
4	NR	3-6.7	4.1	7.04	14.81	NR	NR	Posterior microphthalmos
25	NR	NR	NR	NR	NR	NR	NR	Nanophthalmos
20	10.5	1.7-2.54	5.1-6.26	(7.7-9.4)*	16.2-16.5	NR	AR	Nanophthalmos
22	9.5-11	1-2.7	4.2-7.26	(9.3-10.54)*	14.5-20.5	4-25%	NR	Nanophthalmos
5	10.5-11.5	3.5-3.7	3.9-4	9.1-10	16.7-17.5	NR	AR	Posterior microphthalmos
8	NR	NR	NR	NR	NR	NR	AD	Non-colobomatous microphthalmos
28	11.5	NR	NR	NR	16	NR	NR	Nanophthalmos
6	11-11.9	2.9-3.6	4-4.5	8.1-9.2	15.4-16.8	NR	AR	Posterior microphthalmos
27	NR	NR	5.64-5.58	NR	21	7%	NR	Nanophthalmos
16	NR	NR	NR	NR	NR	NR	NR	Nanophthalmos
18	11	1.2-2.5	4.1-4.6	(9.3-12.2)*	16.1-17.5	NR	AR	Nanophthalmos
7	11	3-3.5	Normal	NR	14.2-15.17	NR	AR	Posterior microphthalmos
2	10.5-11.5	Normal	Normal	10.5-13	17-20.8	NR	NR	Simple microphthalmos
12	NR	NR	4.2-4.6	NR	15.7-20.5	NR	NR	Nanophthalmos
24	NR	NR	NR	NR	15.5-20.3	NR	NR	Nanophthalmos
21	NR	NR	NR	NR	19	NR	NR	Nanophthalmos
This study	8-9.7	2-2.8	4.2-4.3	11.4-13.5	18.4-19.7	UN	AD	Simple microphthalmos

CD=corneal diameter. ACD=anterior chamber depth. LT=lens thickness. VCL=vitreous cavity length. TAL=total axial length. AR=autosomal recessive.

AD=autosomal dominant. NR=not reported.

(\*)measurements obtained by us on available data.

III.5. Ultrasonography was not performed for the same reasons above.

#### PATIENT IV.5

This 31 year old male had onset of first symptoms of recurrent ocular hypertension and redness at the age of 10. The diagnosis of the disease was established in the first year of life, as was the presence of microcornea. His best corrected visual acuity was hand movements in OU. Slit lamp examination showed a complicated posterior spongoid-like cortical cataract in both eyes. No fundus abnormalities were ophthalmoscopically evident, besides severe glaucomatous disc cupping and atrophy. A scan ultrasonography measurements showed TAL reduction (RE: 19.4 mm; LE: 18.9 mm) and a reduced vitreous cavity length (RE: 12.6 mm; LE: 12.1 mm) in both eyes. Anterior chamber depth and lens thickness were normal in OU. The presence of choroidal thickening was also observed on ultrasound (1.7 mm bilaterally). He is currently on daily topical treatment with beta blockers and acetazolamide to prevent painful ocular hypertensive relapses.

#### PATIENT IV.12

This 27 year old female patient did not notice any symptoms until the age of 22, when she first experienced glaucomatous uveitis. Her best corrected visual acuity was 0.7 RE and 0.4 LE with hyperopic and astigmatic correction. Corneal diameter reduction was biomicroscopically observed with an increased corneal thickness, more pronounced during the hypertensive uveitis relapses. For this reason, she is currently on daily treatment with topical beta blockers, mydriatics, and steroids, and on oral acetazolamide at variable dosages. Mild posterior cortical opacities were biomicroscopically observed in both eyes. Examination of the patient showed retino-choroidal thickening in both eyes. The TAL was ultrasonographically reduced in both eyes (19.7 mm) as well as the vitreous cavity (RE

13.4 mm, LE 13.5 mm) and the anterior chamber depth (2 mm). Choroidal congestion was confirmed by ultrasonography (1.9 mm OU).

#### PATIENT V.8

This 11 year old girl, daughter of patient IV.5, reported no symptoms related to the disease. Best corrected visual acuity was 1.0 in OU and a high astigmatism was found. Her ophthalmological examination was unremarkable, with the exception of microcornea. Ultrasonographic measurements were all within normal limits, except for TAL (18.4 mm OU) and the vitreous cavity length (11.4 mm OU).

#### Discussion

In this study five patients were diagnosed as having microphthalmos based on TAL reduction (table 1). All of them also showed microcornea. Regarding this clinical association, Weiss *et al*<sup>2</sup> related the presence of microcornea to a TAL less than 18 mm. This is in agreement with other authors,<sup>9 17 19 22</sup> who reported microcornea coexisting with microphthalmos with TAL ranging between 13 and 20.5 mm (table 2). On the other hand, normal corneal diameters were found in several studies (table 2).<sup>2 5 6 11 22 28</sup> To the best of our knowledge, this clinical association has not been considered from a genetic point of view.

Microcornea may occur as an isolated anomaly and can be either the result of environmental factors<sup>34</sup> or can be transmitted as an autosomal dominant trait.<sup>35</sup> Accordingly, environmental factors can determine non-syndromic microphthalmos.<sup>36</sup> Most of the published familial cases of microphthalmos show an autosomal recessive mode of transmission,<sup>5-7 13 18 20 26</sup> but recessive X linked pedigrees have been also described.<sup>37</sup> Only Bateman<sup>8</sup> and Sjögren and Larsson<sup>23</sup> described pedigrees in which non-colobomatous microphthalmos was inherited as an autosomal dominant trait.

The reasons for such wide genetic heterogeneity are not clear. However, recent ad-

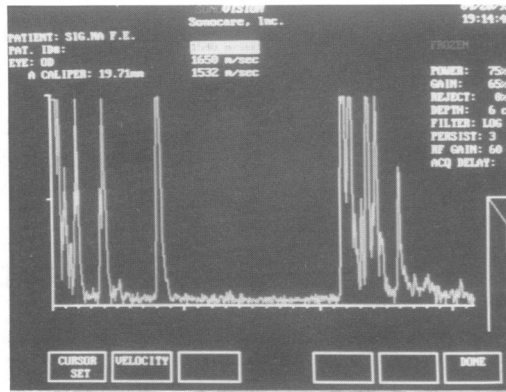


Figure 2 Total axial length of the right eye measured in case IV-12.

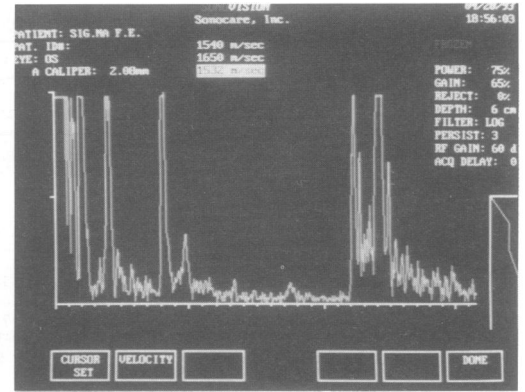


Figure 3 Anterior chamber depth of the left eye measured in case IV-12.

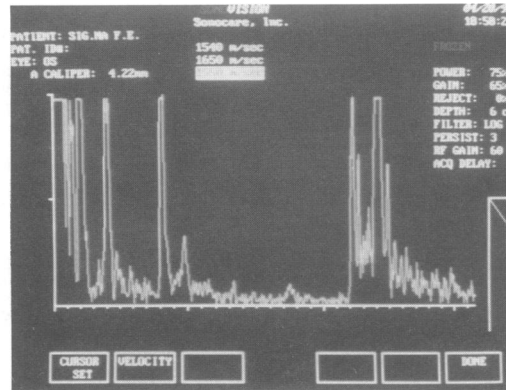


Figure 4 Lens thickness of the left eye measured in case IV-12.

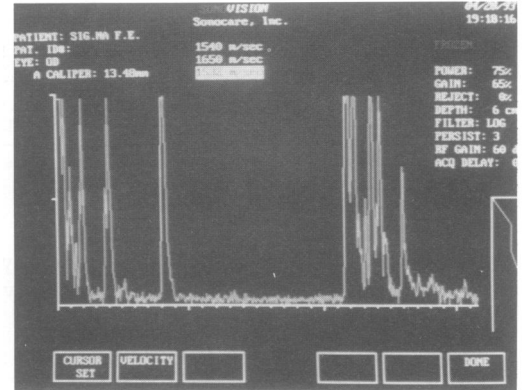


Figure 5 Vitreous cavity length of the right eye measured in case IV-12.

vances in the field of molecular genetics might help in clarifying this issue. In fact, different mutations at the same locus were found to cosegregate with the disease phenotype in families with both autosomal dominant and autosomal recessive inheritance.<sup>38</sup> This consideration might help to explain the clinical and genetic heterogeneity of microphthalmos.

Our pedigree shows an association between microphthalmos and microcornea, both inherited as an autosomal dominant trait. This clinical association has also been previously reported, both as a sporadic<sup>29 11 17 19 22</sup> and a familial finding,<sup>5 20</sup> but so far no explanation for this co-occurrence has been attempted. In our opinion, it could be speculated that contiguous genes are involved in the family described here.

In addition, environmental factors may interfere both during organogenesis, involving the entire eye globe, causing microphthalmos or anophthalmos, and eye differentiation, determining local growth abnormalities that can produce specific ocular defects.<sup>39</sup> In fact, it is known from experimental studies that the diameter of the cornea is determined by the size of the retinal cup, so that growth retardation of the eye would entail a reduction of a qualitatively normal cornea as well.<sup>40 41</sup> Therefore, a factor that interferes with optic vesicle development can produce a small retinal cup, so that the mesenchymal layer from which the corneal stroma and endothelium derive has no room for proper growth (although qualitatively normal), while the ectodermic lens vesicle keeps growing into an overall small eye. On the other hand, a late factor can interfere only in

posterior segment differentiation, determining microphthalmos without anterior segment abnormalities, while a local disturbance of corneal growth can explain microcornea without reduced axial length.

Therefore, both conditions are possible, that is, to observe a severe reduction in TAL with no developmental defects of the cornea, and, as in our pedigree, the presence of microcornea with mild TAL reduction. The autosomal dominant inheritance of both microcornea and microphthalmos observed in our five generation pedigree suggests that a gene cluster defect is more likely to play a role than environmental factors. Since microphthalmos can occur either with or without microcornea, we suggest that microcornea should not be considered as a parameter for classification of microphthalmos. However, the diagnosis of microcornea should always prompt a careful clinical and biometric evaluation to establish the possible coexistence of microphthalmos.

In our study, TAL values ranged between 18.4 mm and 19.7 mm, indicating a mild form of microphthalmos (fig 2). Anterior chamber depth was normal in IV-5 and in V-8, while it was shallow in IV-12 (table 1) (fig 3). Lens thickness was normal in all subjects (table 1) (fig 4). Therefore, on ultrasonography, anterior segment length was within the normal range in all three persons examined, while a pronounced reduction of the posterior segment was seen in all cases (table 1, fig 5). This observation indicates that the impaired growth of the posterior segment length is responsible for the determination of TAL reduction in simple microphthalmos. This is in agreement with Weiss

et al.,<sup>2</sup> who reported the values for the posterior segment length to be uniformly below (at least 2 SD) the mean for age in 10 patients affected with simple microphthalmos. Therefore, they emphasised that the vitreous cavity length reduction accounted for 90% of the reduction in TAL.

Other authors have previously identified the same clinical condition by the term posterior microphthalmos. In fact, Fried et al.,<sup>4</sup> and Spitznas et al.,<sup>5</sup> Fledelius and Rosenberg,<sup>6</sup> and Meire et al.<sup>7</sup> described eyes with short TAL owing to disproportionately short posterior segment length, while the anterior segment fell within normal values (table 2). Very recently, Warburg<sup>26</sup> identified this clinical condition with the term partial microphthalmos. In addition, several authors<sup>8-29</sup> (table 2) have used the term nanophthalmos to indicate short eyes, without other systemic or ocular abnormalities. According to Duke-Elder,<sup>3</sup> the typical TAL of nanophthalmos was between 16 and 18.5 mm, and this biometric finding has been until recently considered the only useful parameter for the diagnosis of nanophthalmos. In most cases ultrasonographic measurements on nanophthalmic eyes were not performed and reviewing published reports allowed us to note that only in a few studies on nanophthalmic eyes was the anterior chamber depth and lens thickness calculated (table 2).<sup>18,20,22</sup> Particularly, in these investigations the reported ultrasonographic measurements allowed us to estimate the values for the anterior and posterior segments. In all measurable cases the former fell within the normal range, while the latter were shortened (table 2). This is not in agreement with the clinical classification proposed by Warburg,<sup>1</sup> who identified nanophthalmos as total microphthalmos characterised by a reduction of both anterior and posterior segments.

In conclusion, to our knowledge, this is the first described pedigree showing an association of simple microphthalmos and microcornea, possibly owing to a cosegregation of two contiguous genes, suggesting an independently inherited autosomal dominant trait with complete penetrance.

Clinical and ultrasonographic findings from our study, together with published data, lead us to believe that nanophthalmos and pure, partial, simple, posterior microphthalmos are synonymous terms to indicate a unique clinical entity with a common ultrasonographic reduction of the posterior segment of the eye and a normal anterior segment. Therefore, it could be suggested that these might be superimposable conditions and can be identified with the definition of simple microphthalmos, according to Weiss et al.<sup>2</sup>

- 1 Warburg M. Classification of microphthalmos and coloboma. *J Med Genet* 1993;30:664-9.
- 2 Weiss AH, Kousseff BG, Ross EA, Longbottom J. Simple microphthalmos. *Arch Ophthalmol* 1989;107:1625-30.
- 3 Duke-Elder S. Anomalies in the size of the eye. In: Duke-Elder S, ed. *Systems in ophthalmology* Vol 3. Part 2. St Louis: CV Mosby, 1963:488-95.
- 4 Fried M, Meyer-Schwickerath G, Koch A. Excessive hypermetropia: review and case report documented by echography. *Ann Ophthalmol* 1981;14:15-19.

- 5 Spitznas M, Gerke E, Bateman JB. Hereditary posterior microphthalmos with papillomacular fold and high hyperopia. *Arch Ophthalmol* 1983;101:413-7.
- 6 Fledelius HC, Rosenberg T. Extreme hypermetropia and posterior microphthalmos in three siblings. An ophthalmometric study. In: Ossoing KC, Nijhoff M, eds. *Ophthalmic echography*. Dordrecht: WJ Junk, 1987:87-91.
- 7 Meire F, Leys M, Boghaert S, De Lacy JJ. Posterior microphthalmos. *Bull Soc Belge Ophthalmol* 1982;231:101-6.
- 8 Bateman JB. Microphthalmos. *Int Ophthalmol Clin* 1984;24:87-107.
- 9 Brockhurst RJ. Nanophthalmos with uveal effusion: a new clinical entity. *Trans Am Ophthalm Soc* 1974;72:371-403.
- 10 Brockhurst RJ. Vortex vein decompression for nanophthalmic uveal effusion. *Arch Ophthalmol* 1980;98:1987-90.
- 11 Calhoun FP Jr. The management of glaucoma in nanophthalmos. *Trans Am Ophthalm Soc* 1975;73:97-119.
- 12 Chi Jin J, Anderson DR. Laser and unsutured sclerotomy in nanophthalmos. *Am J Ophthalmol* 1990;109:575-80.
- 13 Cross HE, Yoder F. Familial nanophthalmos. *Am J Ophthalmol* 1976;81:300-6.
- 14 François J, Goes F. Ultrasonographic study of 100 emmetropic eyes. *Ophthalmologica* 1977;175:321-7.
- 15 Frazer GR, Friedmann AI. *The causes of blindness in childhood*. Baltimore: Johns Hopkins University Press, 1967:59-60.
- 16 Good WV, Stern WH. Recurrent nanophthalmic uveal effusion syndrome following laser trabeculoplasty. *Am J Ophthalmol* 1988;106:234-5.
- 17 Kimbrough RL, Trempe CS, Brockhurst RJ, Simmons RJ. Angle-closure glaucoma in nanophthalmos. *Am J Ophthalmol* 1979;88:572-9.
- 18 Martorina M. Nanophthalmia familiare. *J Fr Ophthalmol* 1988;11:357-61.
- 19 O'Grady RB. Nanophthalmos. *Am J Ophthalmol* 1971;71:1251-3.
- 20 Ryan EA, Zwaan J, Chylack LT. Nanophthalmos with uveal effusion. Clinical and embryologic considerations. *Ophthalmology* 1982;89:1013-7.
- 21 Shiono T, Shoji A, Mutoh T, Tamai M. Abnormal sclerocytes in nanophthalmos. *Graefe's Arch Clin Exp Ophthalmol* 1992;230:348-51.
- 22 Singh OS, Simmons RJ, Brockhurst RJ, Trempe CL. Nanophthalmos. A perspective on identification and therapy. *Ophthalmology* 1982;89:1006-12.
- 23 Sjögren T, Larsson T. Microphthalmos and anophthalmos with and without coincident oligophrenia. *Acta Psychiatr Neurol Scand* 1949;suppl 56:1-103.
- 24 Stewart DH, Streeten FH, Brockhurst RJ, Anderson DR, Hirose T, Gass DM. Abnormal scleral collagen in nanophthalmos. An ultrastructural study. *Arch Ophthalmol* 1991;109:1017-25.
- 25 Trelstad RL, Sibermann NN, Brockhurst RJ. Nanophthalmic sclera: ultrastructural, histochemical and biochemical observations. *Arch Ophthalmol* 1982;100:1935-8.
- 26 Warburg M. Genetics of microphthalmos. *Int Ophthalmol* 1981;4:45-65.
- 27 Ward RC, Gragoudas ES, Pon DM, Albert DM. Abnormal scleral findings in uveal effusion syndrome. *Am J Ophthalmol* 1988;106:139-46.
- 28 Yue BYJT, Duvall J, Goldberg MF, Puck A, Tso MAO, Sugar J. Nanophthalmic sclera. Morphologic and tissue culture studies. *Ophthalmology* 1986;93:534-41.
- 29 Zeiter HJ. Congenital microphthalmos. A pedigree of four affected siblings and an additional report of forty four sporadic cases. *Am J Ophthalmol* 1963;55:910-22.
- 30 François J. A propos d'une famille présentant des anomalies oculaires du type colobomateaux depuis le colobome unilatéral de l'iris jusqu'à l'anophthalmie bilatérale, associée au syndrome de Bardet-Biedl. *J Genet Hum* 1953;2:203-18.
- 31 Romano A, Tadmor AR, Frank I, et al. Clinical and genetic considerations in familial anophthalmia. *Metabol Ophthalmol* 1978;2:197-200.
- 32 Hessel IE. Midface syndrome with iridochoroidal coloboma and deafness in a mother: microphthalmia in her son. *Birth Defects* 1971;7(7):269.
- 33 Pannarale MR. La determinazione della correzione astigmatomica. Indicazioni e tecniche d'uso di quadranti astigmatometrici personali. *Boll Ocul* 1977;56:71-97.
- 34 Waring GO, Rodrigues MM. Congenital and neonatal corneal abnormalities. In: Tasman W, Jaeger EA, eds. *Duane's foundations of clinical ophthalmology*. Philadelphia: JB Lippincott, 1990:3-4.
- 35 Merin S. In: Merin S, ed. *Inherited eye diseases: diagnosis and clinical management*. Vol 2. New York: Dekker, 1991:51.
- 36 Guyer DR, Green WR. Bilateral extreme microphthalmos. *Ophthalmic Paediatric Genet* 1984;4:81-90.
- 37 Hoefnagel D, Keenan ME, Allen FH. Heredofamilial bilateral anophthalmia. *Arch Ophthalmol* 1963;69:760-4.
- 38 Rosenfeld PJ, Cowley GS, McGee TL, Sandberg MA, Berson EL, Dryja TP. A null mutation in the rhodopsin gene causes rod photoreceptor dysfunction and autosomal recessive retinitis pigmentosa. *Nature Genet* 1992;1:209-21.
- 39 Hay ED. Development of the vertebrate cornea. *Int Rev Cytol* 1980;63:263-322.
- 40 Hay ED, Revel JP. Fine structure of the developing avian cornea. In: Wolfsky A, Chen PS, eds. *Monographs in developmental biology*. Basel: Karger, 1969:1.
- 41 Lopashov GV, Stroevo OG. Morphogenesis of the vertebrate eye. In: Abercrombie M, Brachet J, eds. *Advances in morphogenesis*. Vol 1. New York: Academic Press, 1961:331-77.