

# Osteocraniostenosis

Alain Verloes, Françoise Narcy, Bettina Grattagliano, Anne-Lise Delezoide, Pierre Guibaud, Jean-Pierre Schaaps, Martine Le Merrer, Pierre Maroteaux

## Abstract

We report a multiple congenital anomalies (MCA) syndrome in three unrelated fetuses consisting of extremely thin, dense, fishbone-like diaphyses, flared metaphyses, mild micromelic dwarfism, brachydactyly, facial dysmorphism, ocular malformations (microphthalmia, aniridia), cloverleaf skull deformity, and splenic hypoplasia. Histopathological investigations showed abnormalities of the metaphyseal cartilage and adjacent diaphyseal ossification, excessive modelling of the metaphyses, and, in one case, dysplasia of the epiphyseal cartilage. We review three previously reported cases. We suggest the name osteocraniostenosis to describe this radiological and clinical disorder, pinpointing its major clinical and radiological features.

(J Med Genet 1994;31:000-000)

Centre for Human Genetics, CHU Sart Tilman, (B) 4000-Liège, Belgium  
A Verloes

Department of Pathology, CHU Sart Tilman, Liège, Belgium  
B Grattagliano

University Department of Obstetrics and Gynaecology, CHR 'La Citadelle', Liège, Belgium  
J-P Schaaps

Clinique de Génétique Médicale and Unité INSERM U12, Hôpital des Enfants-Malades, Paris, France  
M Le Merrer  
A-L Delezoide  
P Maroteaux

Department of Foetopathology, Hôpital Cochin-Port Royal, Paris, France  
F Narcy

Department of Paediatrics, Hôpital Debrousse, Lyon, France  
P Guibaud

Correspondence to Dr Verloes.

Received 28 January 1994  
Revised version accepted for publication 16 May 1994

Thin, brittle bones are unusual in the skeletal dysplasias. In 1988, one of us,<sup>1</sup> and, independently, Kozłowski and Kan<sup>2</sup> reported several children with these features. Maroteaux *et al*<sup>1</sup> stressed the heterogeneity of these patients from a radiological point of view. We recently had the opportunity to investigate two fetuses with thin bones and cloverleaf deformity. We present here clinical, radiological, and histological evidence for the delineation of a distinct MCA-skeletal dysplasia syndrome best described as "osteocraniostenosis".

## Case reports

### CASE 1

The mother of the proband (GF 6898) was referred for evaluation of intrauterine growth retardation (IUGR) at 23 weeks of gestation. She was a healthy 24 year old woman, married to a healthy 31 year old man. Both were of Italian ancestry and non-consanguineous. Their first child was unaffected. The pregnancy was terminated at 24 weeks after ultrasonographic detection of micromelic dwarfism, skull deformity, and hypotelorism.

The female fetus (fig 1A) weighed 254 g (-1 SD), crown-heel distance was 22 cm (-2.5 SD), crown-rump was 17 cm (mean), foot length was 20 mm (mean for 16 weeks), and OFC was 18 cm. The skull was acrocephalic with a cloverleaf deformity and a huge anterior fontanelle. Apparent blepharophimosis, short, upturned nose, short philtrum, small, reversed V shaped mouth (fig 1B), low set ears, moderate micromelia with acromicria, short, stubby

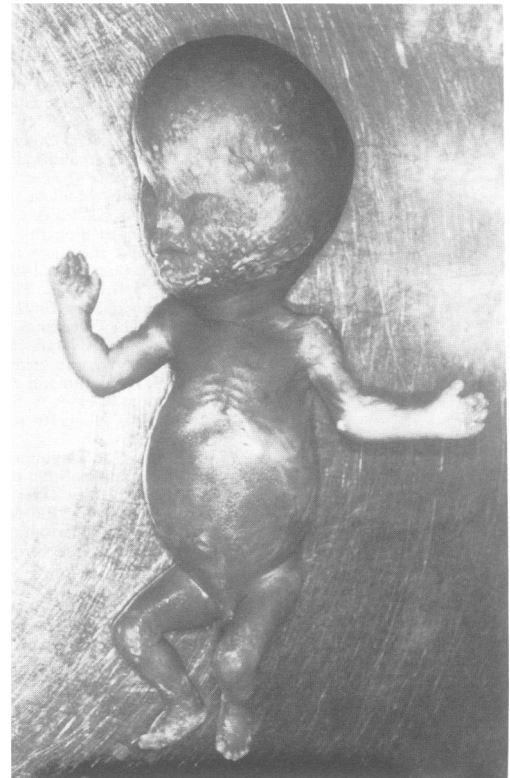

Figure 1A General appearance of case 1 showing cloverleaf anomaly, micromelia, and acromicria.

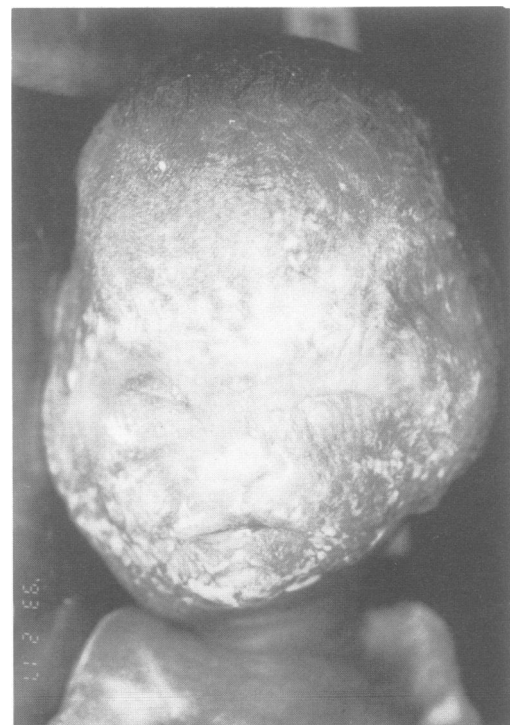

Figure 1B Facial aspect of case 1: note small nose and small palpebral fissures.

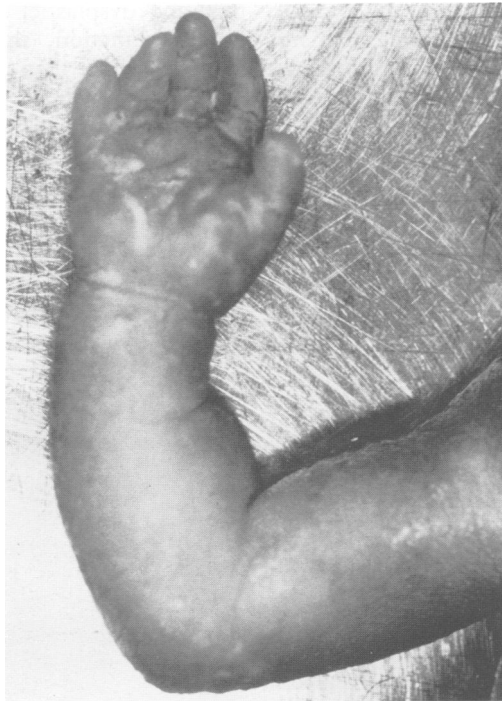

Figure 1C Close up view of the forearm of case 1.

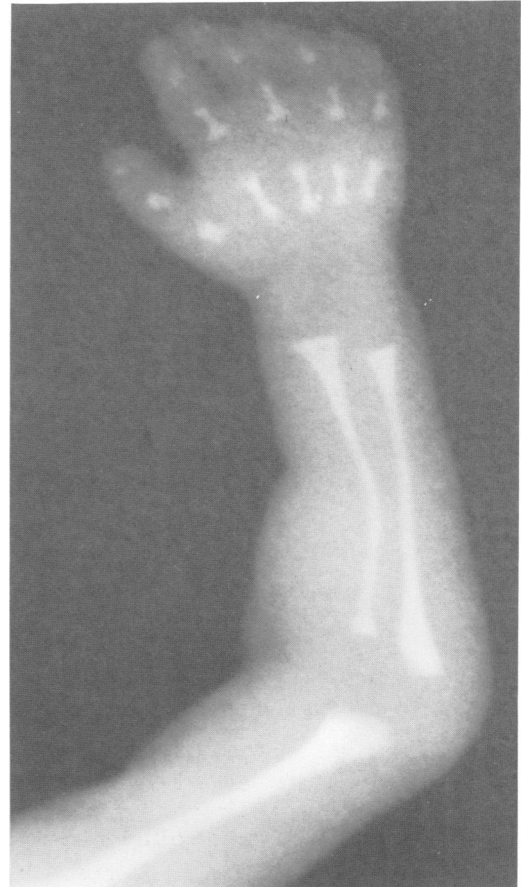

Figure 2B Curved diaphyses, drumstick phalanges, and square first metacarpal of case 1.

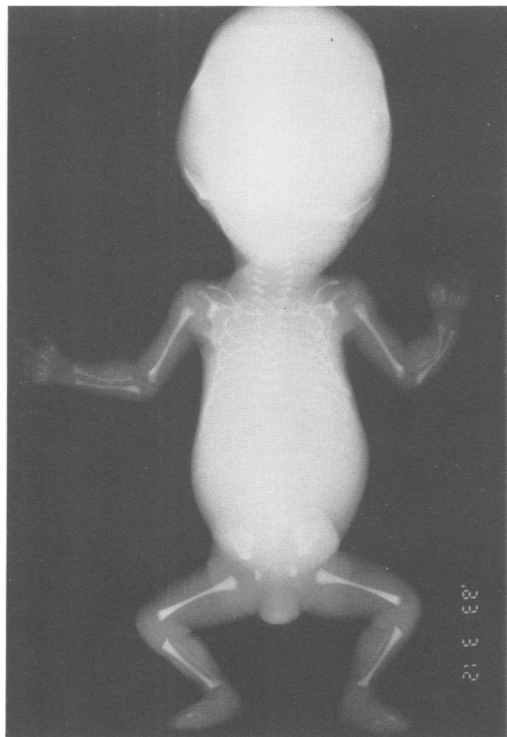


Figure 2A Skeletal survey of case 1 illustrating fishbone diaphyses and metaphyseal flaring most apparent in the upper limb.

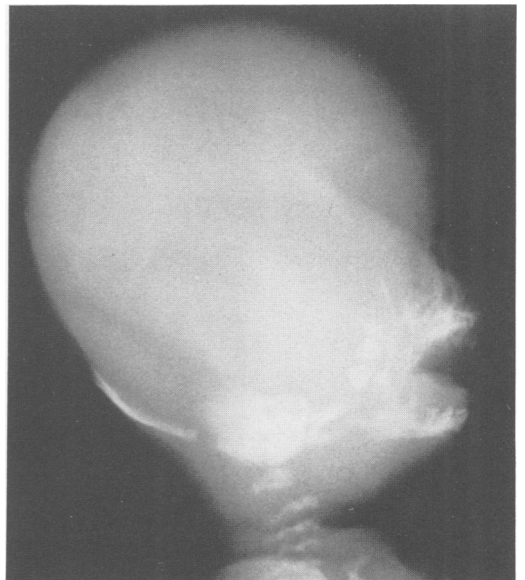

Figure 2C Hypomineralised skull vault of case 1.

fingers (fig 1C) with tiny nails, and bowed forearms were noted. There was no visceral malformation, but the spleen could not be found. The brain weighed 95 g and was macroscopically normal. Non-colobomatous microphthalmia was present on one side, and aniridia on the opposite side.

X rays showed extremely thin, sclerotic, and somewhat misshapen long bones (fig 2A), fili-form fibulae, brachymetacarpia, and brachyphalange with lack of ossification of the third

phalanges (fig 2B). The metaphyses were flared and dense, giving a drumstick appearance to the tubular bones. Despite poor mineralisation, the typical deformities of a cloverleaf skull were clearly present (fig 2C). The vertebral bodies were flattened and dense. There were 11 pairs of ribs.

Microscopic examination of a finger, a femoral head, and a tibial plate was performed. In the hyaline cartilage of the epiphyses (fig 3A), the density of chondrocytes was low, the cells

appeared irregularly clustered, and the lacunae were of very uneven diameter, some of them unusually large. The ground substance appeared very irregularly stained and disorganised. Endochondral ossification was abnormal; the zone of columnar cartilage was very short and the chondrocytes were poorly lined (fig 3B). The zone of degenerating vesicular cartilage was thin and cells were less hypertrophied than usually seen. The zone of calcified cartilage was reduced. The trabeculae of primary bone were short, stubby, and irregular. The ring of bone usually surrounding the growth plate up to the level of the primary trabeculae appeared short,

thin and dysplastic. At the metaphyseal-diaphyseal junction, the zone of remodelling appeared wider than usual, with a large excess of osteoclasts (fig 3C).

#### CASE 2

The pregnancy of this male fetus was terminated at 32 weeks, after a suggested ultrasound diagnosis of thanatophoric dysplasia, based on micromelic dwarfism, platyspondyly, and cloverleaf skull. The mother, aged 29, originated from Italy. No other pedigree data were available. The child (fig 4A,B) weighed 1480 g

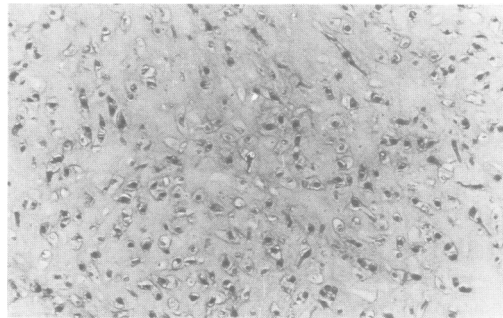


Figure 3A Case 1: dissimilar chondroblasts irregularly scattered in epiphyseal bone.

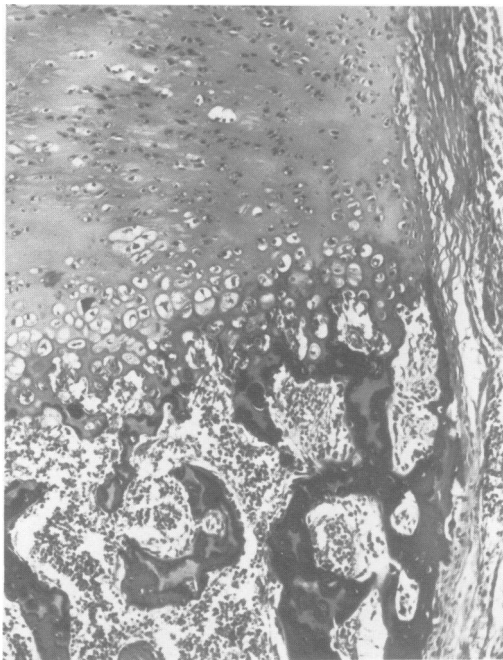

Figure 3B Case 1: metaphyseal plate showing shortened, irregular columns of hypertrophied cartilage, stubby primary bone spiculas, and irregular density of the intercellular matrix in the epiphyseal area.

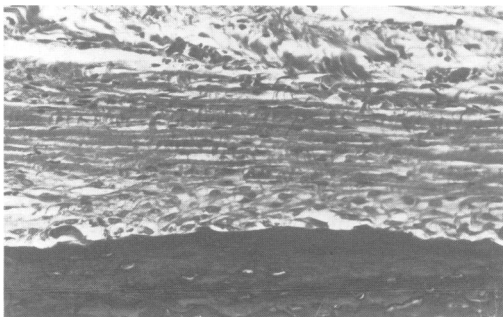


Figure 3C Case 1: numerous osteoclasts lining the inner aspect of the diaphysis.

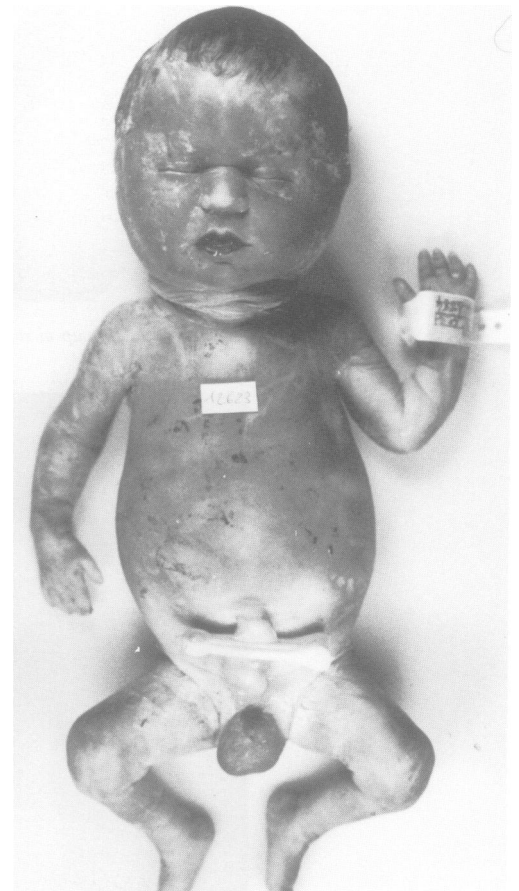

Figure 4A General appearance of case 2 (note mild temporal swelling).

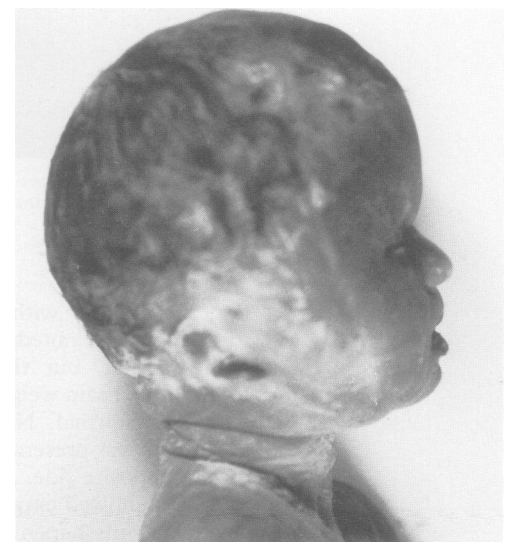

Figure 4B Brachycephaly with bulging forehead of case 2. Note less hypoplastic nose than case 1.

(mean), had a crown-heel length of 36 cm ( $-1$  SD), and a crown-rump length of 27 cm (mean). OFC was 27.5 cm and foot length 45 mm ( $-2$  SD). The face was flat. The skull was poorly mineralised, with a huge anterior fontanelle and a prominent forehead (acrocephaly). The bulging temporal areas (biparietal distance 85 mm) suggested a mild cloverleaf skull deformity. The nasal root was deep. Other anomalies included small, inverted V shaped mouth, low set ears, mild micromelia, and acromicria with brachydactyly. At necropsy a hypoplastic spleen ( $<0.5$  g) was noted. The CNS and medulla were macroscopically and microscopically normal. The eyes were not specifically investigated.

X rays (fig 5A) showed anomalies similar to case 1, poor mineralisation of the cranial vault, and hypoplasia of the distal phalanges (fig 5B). The bones of the forearms were curved and both radii were fractured.

Microscopical examination of the femoral heads, vertebrae, and chondrocostal junction was performed. The epiphyseal cartilage was

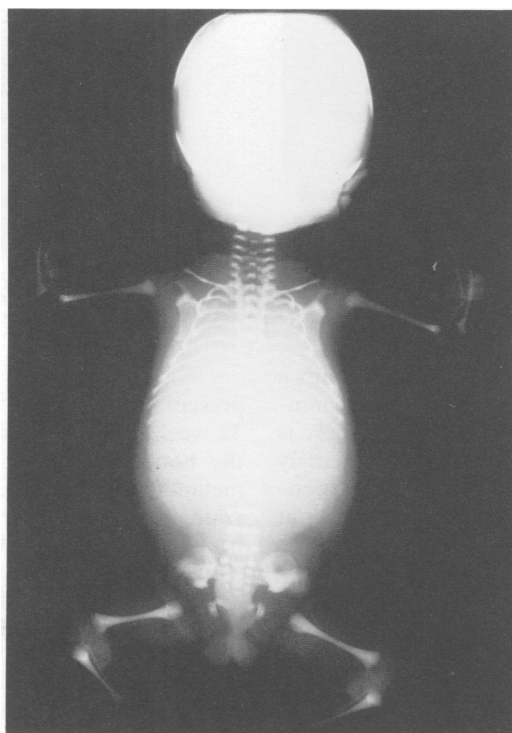


Figure 5A Skeletal survey of case 2. Note slenderness of clavicles.

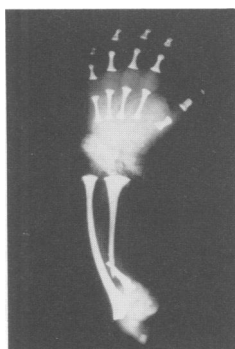


Figure 5B Distal phalangeal hypoplasia of case 2 (x ray obtained with mammograph).

normal and the chondrocytes were not dysmorphic. The zones of columnar and vesicular cartilage were short and irregular (fig 6). The perichondral bony ring was almost absent. The area of secondary metaphyseal remodelling was much wider than usual, extending to several millimetres along the diaphyseal sleeve in the endochondral and perichondral bone, with a large number of osteoclasts. The thickness and density of the diaphyseal bone beyond the metaphyseal zone was increased, and the matrix appeared denser.

#### CASE 3

Radiological data concerning this female patient have previously been published,<sup>1</sup> but this report allows us to illustrate the natural history of the syndrome at different gestational ages. This child was born at 37 weeks, weighing 2840 g, and died on day 2 from a respiratory distress syndrome. Clinical similarities with the previous patients were striking: a hypoplastic nose, microstomia, wide fontanelles, and temporal flaring suggestive of a mild cloverleaf skull deformity (fig 7). The limbs appeared micromelic, with acromicria and nail hypoplasia.

X rays showed thin, dense diaphyses with thin linear (forearm, fibulae) or biconcave (femora) long bones, flared metaphyses (fig 8A), striking drumstick phalanges and metacarpals (fig 8B), and a hypomineralised skull that, a posteriori, clearly showed hypomineralisation with premature synostoses giving a cloverleaf deformity. Necropsy showed hepatomegaly and splenic hypoplasia. Bone was not examined histologically.

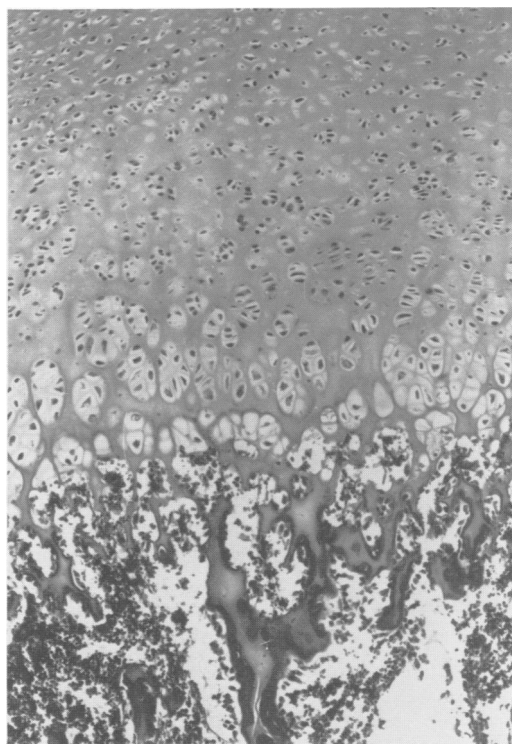


Figure 6 Case 2: metaphyseal plate showing shortened, very irregular columns of hypertrophied cartilage, stubby primary bone spiculas, and normal epiphyseal cartilage.

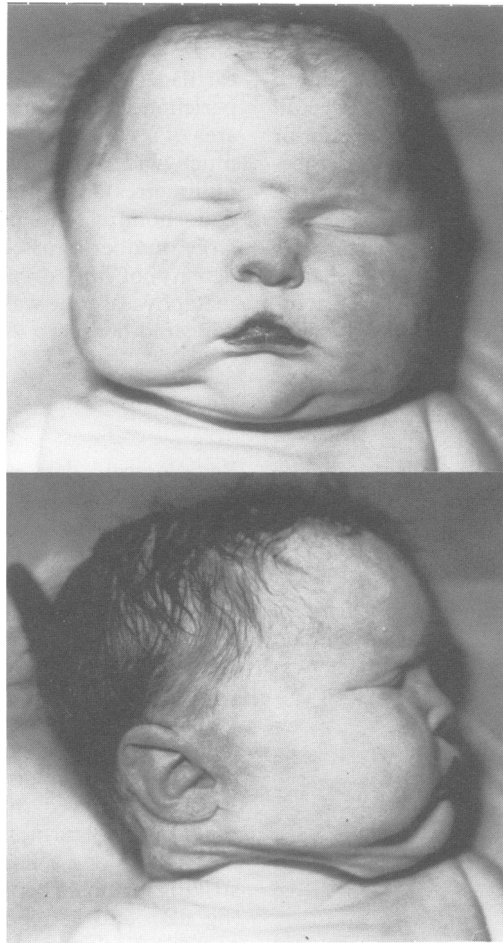


Figure 7 Case 3: face and profile showing distinctive facial features of osteocraniostenosis.

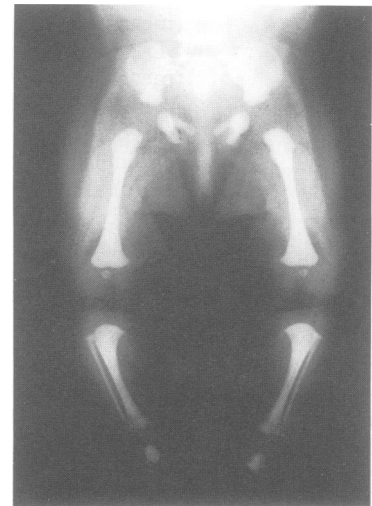

Figure 8A Case 3: thin bones with a biconcave profile of femoral shafts.

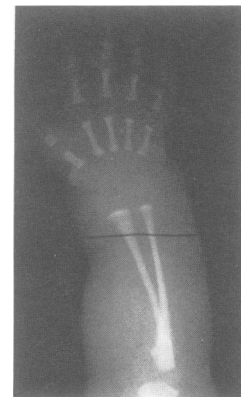

Figure 8B Case 3: forearm showing identical deformities to previous cases.

### Discussion

We have described here three children with a consistent set of clinical and radiological anomalies. The diaphyses are shortened and there is mild micromelia. The long bones are extremely thin but not hypomineralised, prone to spontaneous intrauterine or pathological fractures at birth, and can appear somewhat tortuous in the forearms. The metaphyses are flared. The clavicles and ribs are filiform, translucent, and mildly irregular. The vertebral bodies are somewhat flattened. The hands show a specific pattern of acromicria with brachydactyly, hypo/aplasia of the distal phalanges, and drumstick shaped metacarpals and phalanges in the second to fifth rays. The bones are much shorter in the first ray. The nails are hypoplastic. The fontanelles are very large and the cranial vault is poorly mineralised. The skull is misshapen, combining acrocephaly and cloverleaf deformity. The latter feature is severe in case 1, moderate in case 2, and mild in case 3, but the lateral bulge of the temporal bones is clear on frontal *x* rays, and the parietofrontal and parieto-occipital sutures appear prematurely closed. A combination of telecanthus, midface hypoplasia, and small, inverted V shaped mouth, result in a distinctive facial dysmorphism. Microphthalmia and aniridia were observed in one case, but were not specifically looked for in the others. Hypo/aplasia of the spleen, an uncommon feature in MCA syndromes, is always

present. As illustrated by our cases at 24 weeks, 32 weeks, and term, the radiological aspect of the bones evolves with gestational age. The metaphyses appear as thin cylinders in the youngest case (case 1), but evolve to a biconcave profile, at least in the lower extremities, at term (compare figs 8A and 8B).

Histopathological examination of cases 1 and 2 showed several anomalies in the tubular bones and in the cartilage. In case 1, epiphyseal changes were striking, the area of endochondral ossification appeared very abnormal, the perichondral bony ring was short and thin, and the zone of metaphyseal modelling was widened, with increased osteoclastic activity. Fetus 2 showed a closely related pattern of anomalies, with a widened zone of metaphyseal-diaphyseal remodelling, and absence of the perichondral bony ring, but the epiphyseal cartilage was normal. Unfortunately, the areas studied were not identical in both fetuses, and the eight week difference in gestational age makes accurate comparison very difficult.

One of us<sup>1</sup> described six children with thin, fragile bones and suggested that the patients could be clustered in two groups, based on radiological criteria. One group (patients 5 and 6 in the original report) included case 3 of this paper and a 33 week old stillborn infant (fig 9) with intrauterine fractures, considerable dia-

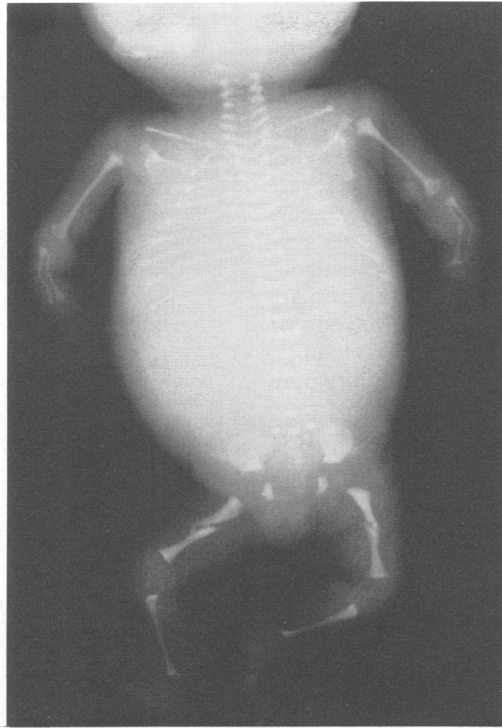


Figure 9 Another case of osteocraniostenosis (Maroteaux *et al.*<sup>1</sup> patient 6) showing multiple fractures, some of them with evidence of healing.

physeal thinning, a poorly mineralised skull, and mild platyspondyly. In the same year, Kozłowski and Kan<sup>2</sup> described three patients. Their patient 1 was a 32 week old boy who died soon after birth. X rays and facial appearance in the photographs are strikingly similar to our case 2. Temporal swelling, although not commented upon, is clearly visible. The spleen was very small. Microscopic examination showed normal ossification processes and low remodeling activity. Patient 3 of Kozłowski and Kan<sup>2</sup> showed identical skeletal anomalies on x ray. The authors quoted a further personal case with cloverleaf skull. These observations, combined with our cases, show a recurrent pattern of anomalies that allows the firm delineation of a syndrome (table).

In contrast to the clinical consistency, the histological features appear variable. The osteoclastic hyperactivity noted in our cases, and the abnormalities of the epi- and metaphy-

seal cartilage are absent in case 1 of Kozłowski and Kan in which the osteoclastic activity was reduced. Whether this reflects aetiological heterogeneity, natural variability, or chronological evolution of the disease remains to be resolved.

Patients 1 to 4 of Maroteaux *et al.*<sup>1</sup> and patient 2 of Kozłowski and Kan<sup>2</sup> show a very different skeletal disorder, characterised by uniformly thin bones (including the metaphyses), multiple fractures, and normal face and extremities. In one case, reduced secretion of total collagen, excess of  $\alpha 2(V)$ , and reduction of synthesis of  $\alpha 2(I)$  and  $\alpha 1(III)$  chains of collagen was reported.<sup>3</sup> A neuromuscular disorder was not totally excluded in other cases of this group, and aetiological heterogeneity must be suspected.

The differential diagnosis of osteocraniostenosis is limited: none of the classical variants of osteogenesis imperfecta (OI) shows severe diaphyseal thinning in infancy, and the dense bone of osteocraniostenosis further contrasts with the osteoporosis of OI. Children with Hallerman-Streiff-François syndrome may have a gracile skeleton in infancy,<sup>4</sup> but show a different phenotype. Very thin diaphyses were observed in a severe form of Beals-Hecht contractural arachnodactyly<sup>5</sup> and in microcephalic osteodysplastic dwarfism type 2.<sup>6</sup>

Two syndromes deserve wider comment. A single child described by Graveleau *et al.*<sup>7</sup> showed significant radiological similarities with osteocraniostenosis, but differs in several clinical features including irregular distal hypoplasia of the fingers, partial fusion of the metatarsals, subtotal agenesis of the phalanges of the toes, microcephaly, micrognathia, different facial dysmorphism, aplasia cutis verticis, severe growth retardation (1600 g at 35 weeks), and long survival (18 months). Another disorder with thin bones and flared metaphyses, observed in cousins, consists of acrocephaly, agenesis of the distal phalanges and nails, peculiar "lamellar" appearance of the diaphyses, and severe hypotonia (Le Merrer *et al.*, personal communication).

Several disorders with neuromuscular involvement have as a consequence poor mineralisation of the bones predisposing to fractures, as in Pena-Shokeir sequence.<sup>8</sup> Most children show associated features including arthrogryposis, amyotrophy, and cleft palate. The thinning of the diaphyses is less prominent than that

#### Clinical and radiographic features

	This report			Maroteaux <i>et al.</i> <sup>2</sup>	Kozłowski and Kan <sup>2</sup>	
	Case 1	Case 2	Case 3	Case 6	Case 1	Case 3
Gestational age (wk)	24	32	37	33	32	?
IUGR	+	+	-	+	+	?
Cloverleaf deformity	++	+	+	?	+	?
Hypotelorism	++	-	+	-	-	?
Microstomia	+	+	+	?	+	?
Nasal hypoplasia	+	±	+	?	+	?
Micromelia	+	+	+	+	+	?
Acromicria	+	+	+	?	+	?
Brachydactyly	+	+	+	?	+	?
Drumstick long bones	+	+	+	+	+	++
Drumstick phalanges	+	+	+	+	+	?
Vault hypomineralisation	+	+	+	+	+	?
Platyspondyly	+	+	?	+	-	?
Fractures	+	+	-	++	++	+++

observed here, and major osteopenia is usually present. The only neuromuscular disorder with a similar osseous involvement is the Finnish form of arthrogryposis multiplex congenita,<sup>9</sup> in which very gracile bones, IUGR, severe micrognathia, and hygroma colli or hydrocephalus are observed. Necropsy consistently shows severe muscular wasting and loss of the motor neurones of the anterior horns. Whether this syndrome represents the severe end of Pena-Shokeir sequence, or a specific disorder with primary osseous involvement remains unsolved. It should be noted that fishbone-like skeleton is not a feature of "common" multiple pterygium syndrome.

We conclude that evidence from this report and from two previous papers allows the delineation of a genuine and clinically consistent MCA syndrome with prominent x ray anomalies. Further reports are necessary to assess the histological variability and to delineate the phenotypic spectrum of osteocraniostenosis (with special emphasis on the CNS and ocular abnormalities). The homogeneity and the genetic origin of the disorder remain to be elucidated. All reported cases being males, the three

classic inheritance patterns have still to be considered.

Some of the illustrations of case 3 and fig 9 are reproduced with the kind permission of the *Archives Françaises de Pédiatrie*.

- 1 Maroteaux P, Cohen-Solal L, Bonaventure J, et al. Syndromes létaux avec gracilité du squelette. *Arch Fr Pédiatr* 1988;45:477-81.
- 2 Kozłowski K, Kan A. Intrauterine dwarfism, peculiar faces and thin bones with multiple fractures - a new syndrome. *Pediatr Radiol* 1988;18:394-8.
- 3 Bonaventure J, Zylberberg L, Cohen-Solal L. A new phenotype of lethal brittle bone disease: biochemical and ultrastructural collagen studies. *Am J Med Genet* 1989;33:309-10.
- 4 Kurlander GJ, Lavy NW, Campbell J. Roentgen differentiation of the oculodentodigital syndrome and the Hallerman-Streif syndrome. *Radiology* 1966;86:77-85.
- 5 Currarrino G, Friedman JM. A severe form of contractural arachnodactyly in two newborn infants. *Am J Med Genet* 1986;25:763-73.
- 6 Verloes A, Lambrechts L, Senterre J, Lambotte C. Microcephalic osteodysplastic dwarfism (type 2-like) in siblings. *Clin Genet* 1987;32:88-94.
- 7 Gravelleau D, Guillaud JC, Capdeville R, Vincens A, Akatcharian C. Nanisme intra-utérin avec dysmorphies multiples, tête d'oiseau, fractures intra-utérines. *Ann Pédiatr (Paris)* 1973;20:545-51.
- 8 Rodriguez JL, Palacios J. Change in the long bones due to fetal immobility caused by neuromuscular disease - a radiological and histological study. *J Bone Joint Surg (Am)* 1988;70:1052.
- 9 Herva R, Leisti J, Kirkinen P, Seppänen U. A lethal autosomal recessive syndrome of multiple congenital contractures. *Am J Med Genet* 1985;20:431-9.