

# Case reports

*Journal of Medical Genetics* 1986, 23, 426–441

## 18q– syndrome and extraskeletal Ewing's sarcoma

M MACHIN VALTUEÑA, J M GARCIA-SAGREDO\*, A MUÑOZ VILLA, C LOZANO GIMÉNEZ, AND J M APARICIO MEIX

*Pediatric Department and \*Medical Genetics Department, C E Ramón y Cajal, Madrid, Spain.*

**SUMMARY** Cytogenetic studies carried out in a boy with multiple congenital anomalies showed a partial deletion of the long arm of chromosome 18. The child later developed an extraskeletal Ewing's sarcoma. The possible association of the tumour with 18q– syndrome is discussed.

18q– syndrome or partial deletion of the long arm of chromosome 18 was first described in 1964<sup>1</sup> and the malformations it produces are well known.<sup>2</sup>

Reference has been made in published reports to the association between certain chromosomal constitutional changes and the growth of specific tumours.<sup>3–6</sup> A cerebellar astrocytoma has been described in a male child with 18q– syndrome.<sup>7</sup>

We describe what is, as far as we are aware, only the second case with the 18q– anomaly who, at four years of age, developed an extraskeletal Ewing's sarcoma.

### Case report

The patient, a male, was the first child of non-consanguineous, healthy parents who were aged 29 and 32 years at the time of his birth. The pregnancy reached term and the delivery was normal. The baby had pulmonary hypertension secondary to pulmonary hypoventilation and right diaphragmatic relaxation. At four months of age he was referred to our Centre because of his dysmorphic features, which included microcephaly, protruding eyes with an antimongoloid slant, flattened bridge of the nose, large philtrum, downturned mouth, high arched palate, low set ears, prominent venous veins on the face and thorax, widely spaced nipples, undescended testes bilaterally, and generalised muscular hypotonia (fig 1).

Chromosome studies showed a partial deletion of the long arm of chromosome 18: 46,XY,del

(18)(q21→qter) (fig 2). The karyotypes of the parents were normal.

At the age of four, he was again admitted to our Centre with functional impairment of walking and standing, after suddenly developing changes in movement with frequent falls. On admission he weighed 15 kg (50th centile), measured 96 cm (10th centile), and his head circumference was 47 cm (below the 3rd centile). Neurological examination showed marked mental retardation, generalised

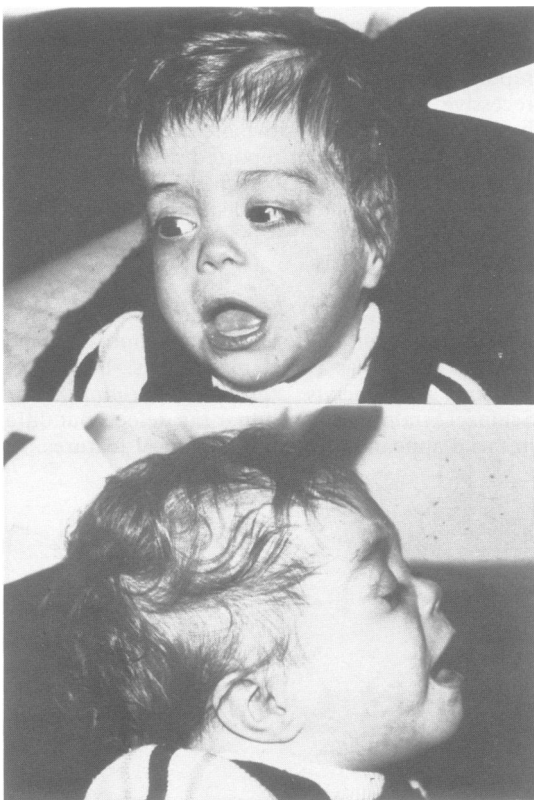


FIG 1 *The proband aged nine months.*

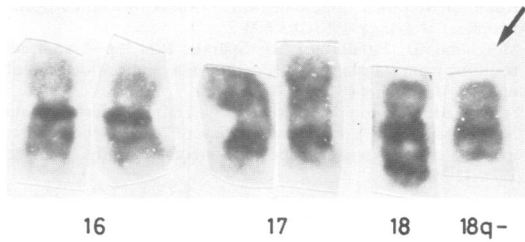


FIG 2 Partial karyotype of the proband showing the  $del(18)(q21 \rightarrow qter)$ .

muscular hypotonia, paraparesis of the lower limbs, bilateral hyperreflexia in patellar and Achilles tendons, and absence of response to painful stimuli. It was impossible to evaluate the remaining sensory functions because of lack of cooperation. The patient was unable to walk. Sphincter control had been absent from birth. The rest of the medical examination was normal.

The CSF study showed a raised protein level (16 g/dl). The number of cells and protein electrophoresis were normal. Catecholamine screening was negative.

X ray examinations of the spine and the rest of the skeleton were normal. Myelography showed a blockage of the contrast material at the level of L1. A CT scan was normal. The electromyogram and the speed of motor activity and sensory function of the lower limbs were normal.

A laminectomy was performed with total excision of the extradural tumour at the level of the conus medullaris, which was found to be histologically compatible with a Ewing's sarcoma (fig 3).

The family refused to continue with any further

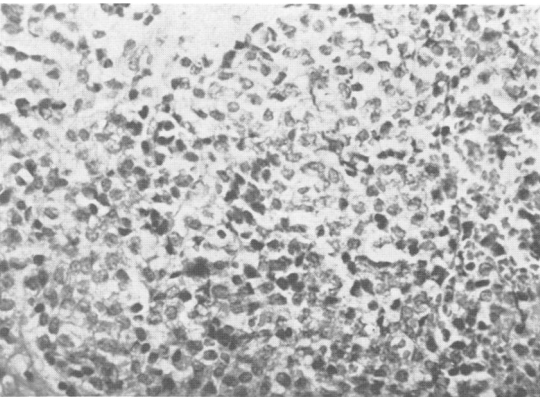


FIG 3 Hyperchromatic tumour cells with round nucleus and no visible cytoplasm.

treatment. Five months later the patient had respiratory difficulty secondary to bilateral pulmonary metastases. He died two weeks later at home.

## Discussion

Various authors have made reference to the appearance of tumours in patients with constitutional chromosomal changes.<sup>3-6</sup> However, it is difficult to know the frequency of this association as the life span of most of these patients is not long enough for the development of tumours.<sup>4</sup>

Chromosomal deletions have been associated with neoplasms, for example, 13q14 deletion with retinoblastoma<sup>8</sup> and 11p13 deletion with Wilms' tumour,<sup>9</sup> and it is thought that loss of genes situated in these bands could be a predisposing factor for tumour development in certain tissues.<sup>4</sup>

Other rare associations include a renal carcinoma in translocation (3;8)(p14;q24)<sup>10</sup> and neuroblastoma in  $inv(11)(q21p23)$  and  $del(21)(p11)$ .<sup>11</sup> Reference has also been made to various extragonadal tumours in patients with sex chromosomal abnormalities.<sup>4</sup>

Neuroblastoma associated with trisomy 18<sup>12</sup> and cutaneous carcinoma of basal cells in 18p-deletion<sup>13</sup> have been described in relation to alterations of this chromosome.

In a review of published reports, we found only one case of 18q- syndrome associated with a tumour, a cerebellar astrocytoma reported by Faulkner *et al.*<sup>7</sup> Our patient had partial deletion of the long arm of chromosome 18 (q21), similar to that described by Faulkner *et al.*<sup>7</sup> At the age of 4 the patient developed a clinical picture of medullary compression caused by a sarcoma histologically compatible with an extraskeletal Ewing's sarcoma, similar to that previously described by Soule *et al.*<sup>14</sup>

In view of the infrequency of both diseases and the existence of a previous association between the 18q- syndrome and a malignant tumour, we should be aware of the possible appearance of malignant tumours in patients with this chromosomal abnormality.

## References

- 1 de Grouchy J, Royer P, Salmon C, Lamy M. Deletion partielle des bras longs du chromosome 18. *Pathol Biol* 1964;12:579-82.
- 2 de Grouchy J, Turleau C. Monosomie partielle 18q ou syndrome 18q-. In: *Atlas des maladies chromosomiques*. Paris: Expansion Scientifique Française, 1977: 210-5.
- 3 Harris CC, Mulvihill JJ, Thorgeirsson SS. Individual differences in cancer susceptibility. *Ann Intern Med* 1980;92:809-25.
- 4 Sandberg AA. Congenital chromosome anomalies and neoplasia. In: *The chromosomes in human cancer and leukemia*. New York: Elsevier/North Holland, 1980:119-35.
- 5 Yunis JJ. The chromosomal basis of human neoplasia. *Science* 1983;221:227-36.

- <sup>6</sup> Littlefield JW. Genes, chromosomes and cancer. *J Pediatr* 1984;**104**:489-94.
- <sup>7</sup> Faulkner KW, Holmes LB, Steinfeld A, Abrams IF. A child with 18q- syndrome and cerebellar astrocytoma. *J Pediatr* 1983;**103**:600-2.
- <sup>8</sup> Yunis JJ, Ramsay N. Retinoblastoma and subband deletion of chromosome 13. *Am J Dis Child* 1978;**132**:161-3.
- <sup>9</sup> Riccardi VM, Sujansky E, Smith AC, Francke V. Chromosomal imbalance in the aniridia-Wilms' tumor association: 11p interstitial deletion. *Pediatrics* 1978;**61**:604-10.
- <sup>10</sup> Cohen AJ, Pi FP, Berg S, *et al.* Hereditary renal cell carcinoma associated with a chromosomal translocation. *N Engl J Med* 1979;**301**:592-5.
- <sup>11</sup> Hecht F, Kaiser-McCaw B. Chromosomes in familial neuroblastoma. *J Pediatr* 1981;**98**:334.
- <sup>12</sup> Robinson MG, McCorquodale MM. Trisomy 18 and neurogenic neoplasia. *J Pediatr* 1983;**103**:600-2.
- <sup>13</sup> Moedjono SJ, Funderburk SJ, Sparkes RS. 18p- syndrome resulting from translocation (13q;18q) in a mildly affected adult male. *J Med Genet* 1979;**16**:399-402.
- <sup>14</sup> Soule EH, Newton W, Moon TE, Tefft M. Extraskelatal Ewing's sarcoma. A preliminary review of 26 cases encountered in the intergroup rhabdomyosarcoma study. *Cancer* 1978;**42**:259-64.

Correspondence and requests for reprints to Dr J M Garcia-Sagredo, Servicio de Genética Médica, CE Ramón y Cajal, 28034 Madrid, Spain.

## An isodicentric X chromosome with short arm fusion in a woman without somatic features of Turner's syndrome

I C S BARNES\*, D J CURTIS\*, AND S L B DUNCAN†

\*Centre for Human Genetics, 117 Manchester Road, Sheffield S10 5DN; and †Jessop Hospital for Women, Leavygreave Road, Sheffield.

**SUMMARY** A 25 year old woman with gonadal dysgenesis but no other somatic features of Turner's syndrome was found to have a 45,X/46,XidicX(p22.3) karyotype. It is postulated that because her stature is within the normal range there has been no loss of genetic material in the fusion of the two Xs. Her mother, who also had a history of menstrual problems, was found to be a 46,XX/47,XXX mosaic.

Isodicentric X chromosomes, formed by fusion of two X chromosomes, have been widely described.<sup>1</sup> The phenotypic effects of this X chromosome abnormality are variable and depend on the amount of material deleted and whether the chromosomes are fused by the short or the long arms. Despite the variable presence of a 45,X cell line, they do, in general, form two distinct groups. Those joined by the short arms exhibit shorter than average stature with gonadal dysgenesis, while those attached by the long arms exhibit normal or taller than average stature with gonadal dysgenesis. Other Turner stigmata can occasionally be present in both groups, but are more frequently associated with short arm fusions.

The present case describes a 25 year old woman with gonadal dysgenesis and normal stature whose karyotype is 45,X/46,Xidic(X)(p22.3). Her mother,

who also had a history of menstrual problems, had a 46,XX/47,XXX karyotype.

### Case report

The female proband (born 8.5.59) presented in July 1981 with a desired, but unconfirmed, pregnancy (LMP April 1981). Clinical examination did not confirm pregnancy. Enquiry into her menstrual history was inconsistent on different occasions. She described her first period as a flowing blood loss following a fight when she was kicked in the stomach. This could have been at about 15 years of age. Menstruation had been very irregular and scanty; between 1977 and 1980 she had been prescribed various courses of the contraceptive pill. During these times she had fairly regular withdrawal bleeding. She stopped the pill in 1980 to try to become pregnant. After the amenorrhoeic episode in 1981 she had a period in February 1982. On review in 1982 because of oligomenorrhoea and infertility she was found to be on the tall side of the normal range (170.75 cm) and underweight (52.25 kg): ponderal index=18. She had a dependent and childish personality and was poorly integrated with her life situation. Neck and carrying angle were unremarkable. Breast development was stage 3 and pubic hair was stage 4 in distribution, but rather scanty. The vulva and vagina were normal and there was a small, anteverted uterus. Tomography of the skull was normal and the bone age showed epiphyseal fusion.