

In our patient, the X;13 translocation did not involve band 13q14. Her tumour was apparently not the result of a functional deletion of genes on chromosome 13, since the normal X was late replicating in all lymphocytes and fibroblasts examined. Also, the normal levels of ESD activity were in agreement with the cytogenetic findings. However, the rarity of X;autosome translocations means that the Rb and the chromosome 13 abnormality are probably related.

We therefore postulate that a cell line with a late replicating der(X;13) chromosome, with spreading of inactivation over chromosome 13, was present in the very early stages of development and was then lost because of selective events against genetic imbalance.<sup>11</sup> The presence of such a line during brain and retinal development could explain the patient's severe mental retardation. At the same time, it would have caused a functional monosomy for the Rb allele.

In all cases of constitutive abnormalities of chromosome 13 leading to loss or inactivation of genes at band 13q14, a Rb mutation in the homologous chromosome 13 is needed to induce the development of Rb.<sup>4</sup> Since in all reported cases of constitutive chromosome abnormality associated with Rb the latter appears to be sporadic, a high frequency of germinal or somatic mutation seems likely.

The authors wish to thank Professor Fraccaro for helpful discussion. The work was supported by a

grant from the Regione Piemonte, Progetto N 32/1983 and by CNR P F Ingegneria Genetica.

#### References

- 1 Francois J. The Costendader memorial lecture: genesis and genetics of retinoblastoma. *J Pediatr Ophthalmol Strabismus* 1979;16:85-100.
- 2 Matsunaga E. Retinoblastoma: host resistance and 13q-chromosome deletion. *Hum Genet* 1980;56:53-8.
- 3 Motegi T, Komatsu M, Nakazato Y. Retinoblastoma in a boy with a de novo mutation of a 13/18 translocation: the assumption that the retinoblastoma locus is at 13q141, particularly at the distal portion of it. *Hum Genet* 1982;60:193-5.
- 4 Ward P, Packman S, Loughman W, et al. Location of the retinoblastoma susceptibility gene(s) and the human esterase D locus. *J Med Genet* 1984;21:92-5.
- 5 Ejima Y, Sasaki MS, Kaneko A, et al. Possible inactivation of part of chromosome 13 due to 13qXp translocation associated with retinoblastoma. *Clin Genet* 1982;21:357-61.
- 6 Mohandas T, Sparkes RS, Shapiro LJ. Genetic evidence for the inactivation of a human autosomal locus attached to an inactive X chromosome. *Am J Hum Genet* 1982;34:811-7.
- 7 Sparkes RS, Sparkes MC, Wilson MG, et al. Regional assignment of genes for human esterase D and retinoblastoma to chromosome band 13q14. *Science* 1980;208:1042-4.
- 8 Galjaard H. *Genetic metabolic diseases*. Amsterdam: Elsevier/North Holland, 1980.
- 9 Cavanee WK, Dryia TP, Philips RA, et al. Expression of recessive alleles by chromosomal mechanisms in retinoblastoma. *Nature* 1983;305:779-84.
- 10 Knudson AG. Mutation and cancer: statistical study of retinoblastoma. *Proc Natl Acad Sci USA* 1971;68:820-3.
- 11 Distèche CM, Eicher EM, Latt SA. Late replication in an X-autosome translocation in the mouse: correlation with genetic inactivation and evidence for selective effects during embryogenesis. *Proc Natl Acad Sci USA* 1979;76:5234-8.

Correspondence and requests for reprints to Dr G Ponzio, Istituto di Genetica Medica, Università di Torino, Via Santena 19, 10126 Torino, Italy.

## Partial monosomy 12p13.1→13.3

D R ROMAIN\*, J GOLDSMITH†, L M COLUMBANO-GREEN\*,  
C J CHAPMAN\*, R H SMYTHE\*, AND R G PARFITT\*

\*Cytogenetics Laboratory, Laboratory Services, Wellington Hospital, Wellington 2; and †Department of Paediatrics, The Wanganui Hospital, Wanganui, New Zealand.

**SUMMARY** We describe a 27 month old female child with partial monosomy for the short arm of chromosome 12: 46,XX,del(12)(p13.1→p13.3). She differs from the eight cases described by others, in that she is less severely affected. Her main clinical features are developmental delay, protruding tongue, strabismus, slightly unusual facies, slight micrognathia, and speech delay.

Received for publication 19 March 1986.  
Revised version accepted for publication 5 May 1986.

#### Case report

The child was born to 26 year old parents at term, after an uneventful pregnancy. She has two normal sibs and her family history is unremarkable. Her birthweight was 3.62 kg, length 49.5 cm, and head circumference 34 cm. Early milestones were only slightly delayed. At 19 months she was referred for investigation of developmental delay, a squint, a protruding tongue (fig 1a), an unusual facies, and possible speech delay. Chromosome analysis was carried out as part of this investigation, her karyo-



FIG 1 (a) Frontal view of face of index case.

type being interpreted as 46,XX,del(12)(p13.1→p13.3) (fig 2). Parental chromosomes were normal.

At 27 months, her weight was 88 cm, head circumference 46.2 cm (just above the 3rd centile), and weight 12.4 kg. Her skull was normal, as was her hair. There was no telecanthus. She still had a squint, but eye movements were full. Her ears were normal in shape and position (fig 1b). She had a large mouth and an unusual tooth which appeared to be the result of the lower left second incisor and canine tooth fusing together (fig 1c). Her palate was normal, but her chin was small and her nose broad. Chest x ray was normal. Examination of her cardiovascular system revealed a soft systolic murmur along the left sternal border which did not sound like a VSD. Her hands were normal in size and appearance. There was a minor degree of overlapping of her second and third toes, but her feet were otherwise normal. There were no birthmarks but her skin mottled quickly when she undressed. The genitalia were normal.

### Discussion

The first observation of monosomy 12p was made by Mayeda *et al.*,<sup>1</sup> who at the same time confirmed the localisation of the LDH-B gene to 12p. Eight further cases of 12p- have been described and have been reviewed by Kivlin *et al.*<sup>2</sup> Although in the greater number of these cases high resolution chromosome banding was not carried out, the indications are that



FIG 2 High resolution G banded examples of 12p-.

there is no unique 12p- syndrome, but that there are a variety of different phenotypes caused by different specific chromosomal segments, as has been found in studies of other chromosome deficiencies and duplications. The most consistent manifestations are micrognathia, microcephaly,

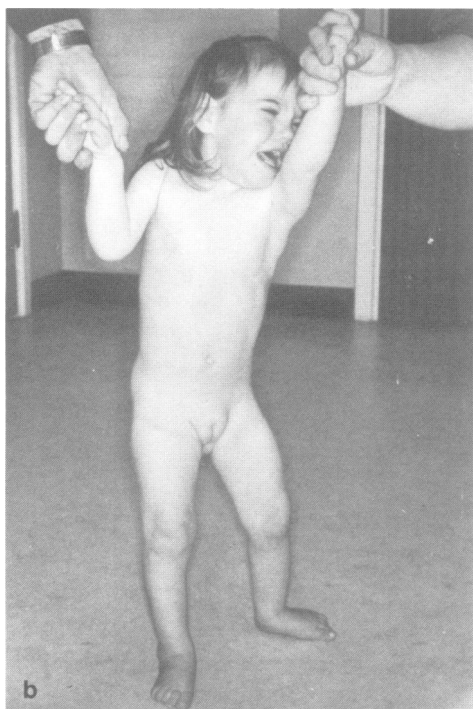

FIG 1 (b) Full frontal view of index case.

slight dysmorphism, and variable mental retardation.

Our patient differs from those already reported in that she is less severely affected. This is possibly because the deleted segment of 12p is smaller (fig 2). Of the reported cases, there is most similarity between our own and that of Magenis *et al.*<sup>3</sup> There is less similarity with the patient of Tenconi *et al.*<sup>4</sup> who, like our infant, showed prominent mottling of the skin, a broad nose, and only slight micrognathia.

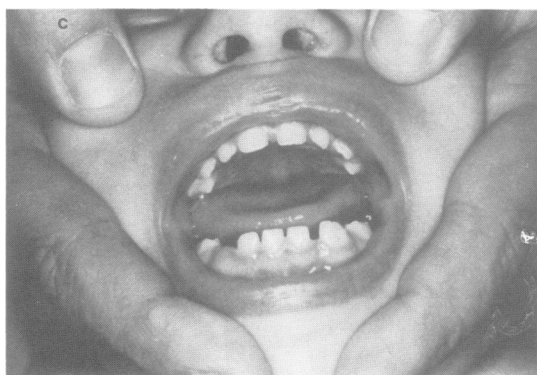


FIG 1 (c) Oral view of index case.

We thank Mrs T Zervos for typing the manuscript and the Audiovisual Unit, Wellington Clinical School for assistance with the illustrations.

#### References

- Mayeda K, Weiss L, Lindahl R, Dully M. Localization of the human lactate dehydrogenase B gene on the short arm of chromosome 12. *Am J Hum Genet* 1974;26:59-64.
- Kivlin JD, Fineman RM, Williams MS. Phenotype variation in the del(12p) syndrome. *Am J Med Genet* 1985;22:769-79.
- Magenis E, Brown M G, Chamberlin J, *et al.* Resolution of breakpoints in a complex rearrangement by use of multiple staining techniques: confirmation of suspected 12p12.3 intraband by deletion dosage effect of LDHB. *Am J Med Genet* 1981;9:95-103.
- Tenconi R, Baccichetti C, Anglani F, Pellegrino PA, Kaplan JC, Junien C. Partial deletion of the short arm of chromosome 12(p11;p13): report of a case. *Ann Genet (Paris)* 1975;18:95-8.

Correspondence and requests for reprints to Dr D R Romain, Cytogenetics Laboratory, Laboratory Services, Wellington Hospital, Wellington 2, New Zealand.

## De novo 2q+ masquerading as Smith-Lemli-Opitz syndrome

ALAN E DONNENFELD, ELAINE H ZACKAI, DONNA M McDONALD, ROSARIA AQUINO\*, AND BEVERLY S EMANUEL\*

Departments of Clinical Genetics and \*Clinical Cytogenetics, The Children's Hospital of Philadelphia, Philadelphia, Pennsylvania 19104, USA.

**SUMMARY** We report a female infant diagnosed shortly after birth as having Smith-Lemli-Opitz syndrome. Despite previously re-

ported normal G banded karyotypes, a high resolution banded chromosome analysis identified 46,XX,2q+. The importance of attention to established features of clinical syndromes, as well as persistence in investigation when diagnostic uncertainties exist, are discussed.