

## Syndrome of the month

# Cartilage-hair hypoplasia

O Mäkitie, T Sulisalo, A de la Chapelle, I Kaitila

Cartilage-hair hypoplasia (CHH) or McKusick type metaphyseal chondrodysplasia (MIM No 250250)<sup>1</sup> is a rare autosomal recessive chondrodysplasia with short limbed short stature, hypoplastic hair, and defective immunity and erythropoiesis.<sup>2-5</sup> The major radiological abnormalities are confined to the metaphyseal regions of the tubular bones.<sup>6,7</sup> The disease is prevalent among the Old Order Amish in the United States and in the Finnish population.<sup>2,8</sup> While genealogical data confirm autosomal recessive inheritance, segregation analysis shows a lack of affected persons among both the Amish and Finnish CHH families; this has been interpreted as a possible example of reduced penetrance.<sup>2,8</sup> The CHH gene was recently assigned to chromosome 9 by linkage analysis,<sup>9</sup> and its localisation refined.<sup>10</sup> This has allowed prenatal diagnosis in four cases.<sup>10A</sup>

### Clinical description

#### GROWTH FAILURE

The growth failure has its onset prenatally; the shortness of limbs or stature or both was noticed neonatally in 76% and by the age of 1 year in 98% of 108 Finnish CHH patients.<sup>11</sup> All segments of the limbs are affected. The growth failure is progressive, owing in part to a weak or absent pubertal growth spurt; pubertal maturation is normal. Adult heights range from 103.7 cm to 149.0 cm with medians of 131.1 cm for males and 122.5 cm for females.<sup>11</sup>

The growth failure is disproportionate with a long trunk in relation to the short limbs. The more severe the growth failure, the greater the disproportion.<sup>11</sup> Proportionate short stature has been described in some CHH patients.<sup>5,12,13</sup>

Median relative weight is above the normal mean in childhood and is further augmented around puberty; most adult patients are clinically obese. The head circumference is close to normal at all ages.<sup>11</sup>

#### OTHER CLINICAL FEATURES

The majority of affected persons have sparse, fine, and silky hair; the eyebrows, eyelashes, and body hair are similarly affected. In some patients, however, the hair appears normal. This was observed in 7% of the Finnish CHH patients.<sup>5</sup>

Other clinical features include laxity of ligaments, limited extension of the elbows, increased lumbar lordosis, bowing of the lower

limbs, chest deformity (narrow thorax, Harrison's grooves, prominent sternum, or asymmetry), and mild scoliosis (figs 1 and 2).<sup>5</sup>

#### IMMUNE DEFICIENCY

The defective cellular immunity is characterised by mild to moderate lymphopenia, decreased delayed hypersensitivity, and impaired in vitro responsiveness of lymphocytes to PHA; humoral immunity is usually intact.<sup>3,4,14,15</sup> A few patients with normal immunity<sup>12,16</sup> or combined immunodeficiency<sup>17-21</sup> have been reported. Defective cellular immunity results in susceptibility to and mortality from infections. The infection problems are most pronounced in early childhood but occasionally persist to adult age. Varicella infection has been fatal in a few cases. In the Finnish series impaired in vitro cellular immunity was observed in 88% of the patients.<sup>5</sup> Fifty-six percent had been unusually prone to infections. Six patients (6%) had died of primary infections. On the other hand, 44% of the patients had shown no unusual susceptibility to infections even though deficient cellular immunity had been confirmed in half of them.<sup>5</sup>

The incidence of malignancies is increased as observed in the Finnish series<sup>5</sup> and cases described earlier.<sup>22-24</sup> Francomano *et al*<sup>25</sup> reported an incidence of 10% of malignancies in 113 Amish CHH patients: lymphoma in three patients, leukaemia in two, skin neoplasms in five, ocular cancer in one, and bile duct carcinoma in one patient.<sup>25</sup> Among the Finnish patients the incidence was six out of 108 patients (6%): skin neoplasms in three patients, lymphoma in one, lymphosarcoma in one, and testicular tumour in one patient.<sup>5</sup>

#### ANAEMIA

Deficient erythrocyte production presents usually as mild macrocytic anaemia in early childhood with spontaneous recovery before adulthood.<sup>26</sup> Occasionally, however, the patients have severe, even fatal, congenital hypoplastic anaemia.<sup>4,13,21,23,25-27</sup> Sixty-seven out of 85 Finnish patients (79%) had been anaemic during childhood; in 14 patients (16%) the anaemia had been severe (lowest haemoglobin value 30-75 g/l) with a fatal course in six patients.<sup>5</sup>

Department of  
Medical Genetics,  
Helsinki University  
Hospital,  
Haartmaninkatu 2B,  
SF-00290 Helsinki,  
Finland  
O Mäkitie  
I Kaitila

Children's Hospital,  
Helsinki University  
Hospital, 00290  
Helsinki, Finland  
O Mäkitie

Department of  
Medical Genetics,  
PO Box 21, 00014  
University of Helsinki,  
Finland  
T Sulisalo  
A de la Chapelle  
I Kaitila

Folkhälsan Institute of  
Genetics, 00250  
Helsinki, Finland  
T Sulisalo  
A de la Chapelle

Correspondence to:  
Dr Kaitila.

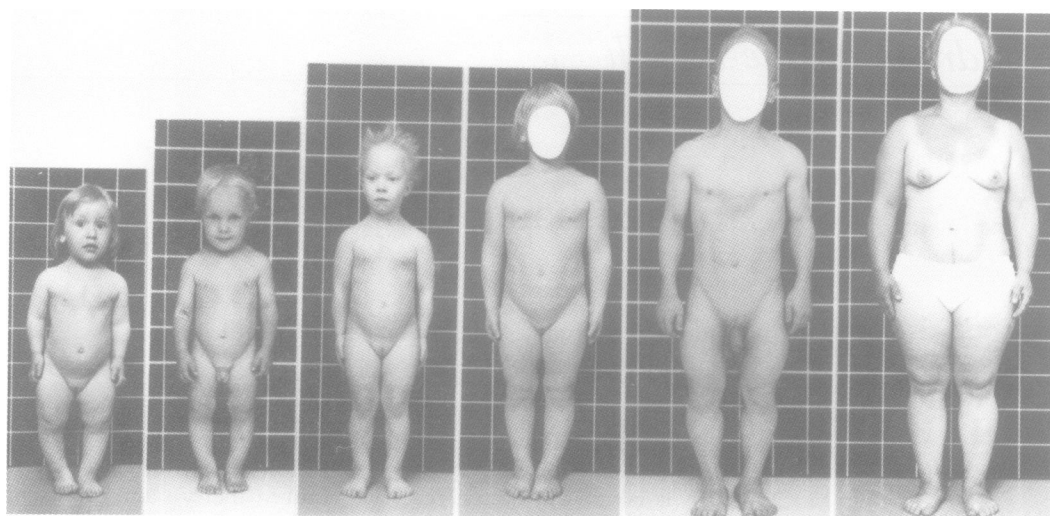


Figure 1 Six CHH patients, front view. Age and absolute and relative values of height (from left to right): (1) 3.6 years, 74.5 cm (-6.8 SD); (2) 3.5 years, 84.3 cm (-4.1 SD); (3) 5.5 years, 94.8 cm (-4.1 SD) (4) 10.5 years, 113.2 cm (-4.7 SD); (5) 15.2 years, 123.9 cm (-6.1 SD); (6) 28.7 years, 134.2 cm (-5.8 SD).

#### INTESTINAL MANIFESTATIONS

There have been several descriptions of CHH patients with congenital megacolon (Hirschsprung's disease).<sup>2,4,16,21,22,28-31</sup> The Finnish series included eight patients (7%) with congenital megacolon.<sup>5</sup> These cases clearly indicate increased prevalence of Hirschsprung's disease among CHH patients.

Intestinal malabsorption was suspected in six Amish patients who had diarrhoea and failure to thrive in the first two years of life.<sup>2</sup> However, primary malabsorption was not observed in any of the 108 Finnish CHH patients; instead, gastrointestinal infection was confirmed in two patients with symptoms suggesting malabsorption.<sup>5</sup> These and other reported cases<sup>32,33</sup> suggest that primary malabsorption is only exceptionally associated with CHH; mimicking symptoms may reflect an underlying gastrointestinal infection.

#### ORTHOPAEDIC PROBLEMS

Orthopaedic problems in CHH are rare com-

pared with many other chondrodysplasias. Ligamentous laxity and increased lumbar lordosis may cause arthralgic pains in the knees, ankles, or lumbar region of the spine. Bow legs may necessitate corrective osteotomy (in 14% of the Finnish patients).<sup>5</sup>

#### Radiographic features

The tubular bones are short for age and their metaphyseal ends are flared, scalloped, and irregularly sclerotic, often with cystic areas (fig 3); the epiphyses are less affected.<sup>6,7</sup> The metaphyseal changes are most pronounced in the knees and ankles; the hips are only mildly affected (fig 4). The metaphyseal irregularities disappear after the closure of the epiphyseal plates but the ends remain somewhat flared and angulated. The spine shows only minor abnormalities: the vertebral bodies are usually normal and caudal widening of the interpediculate distances, though less obvious than normal, is present in most patients (fig 5). Lumbar lordosis is increased and further ac-

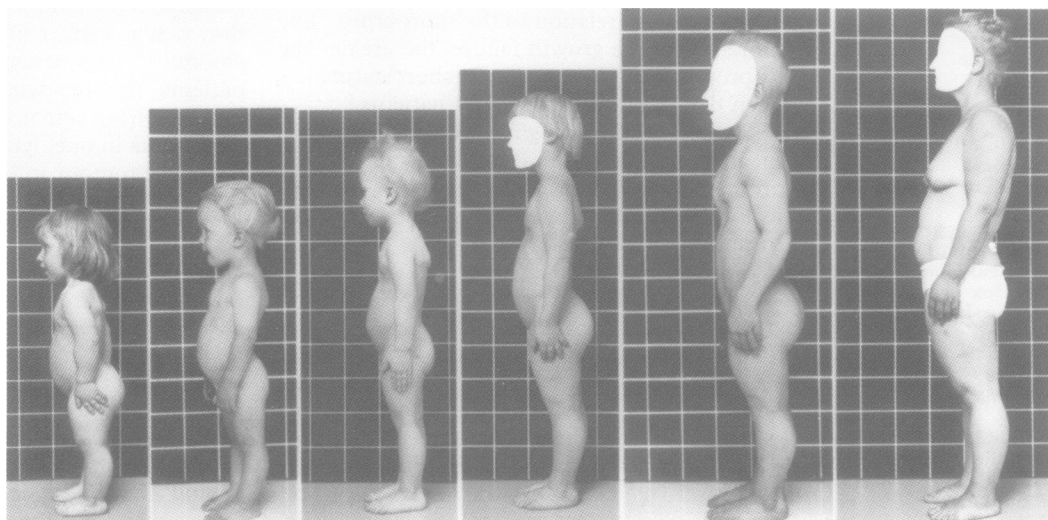


Figure 2 Six CHH patients, side view. Same patients as in fig 1. Note the variation in the degree of disproportion, hair hypoplasia, lumbar lordosis, and chest deformity.

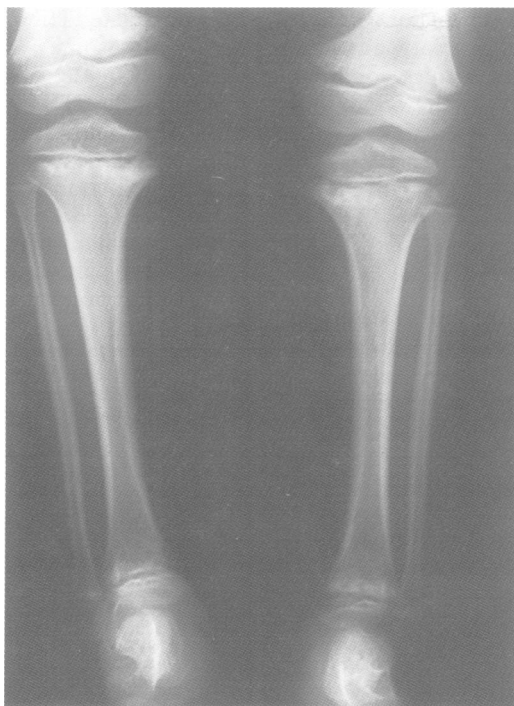

Figure 3 Radiograph of the legs of a 9 year old boy. The metaphyseal ends are flared and irregularly sclerotic. Note the excessive distal length of the fibula.

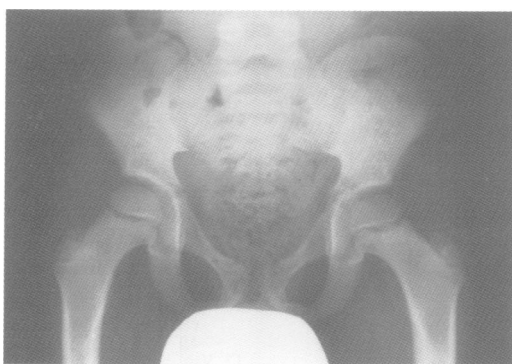

Figure 4 Radiograph of the hips of a 9 year old boy (same patient as in fig 3) showing only mild metaphyseal involvement in the proximal femora.

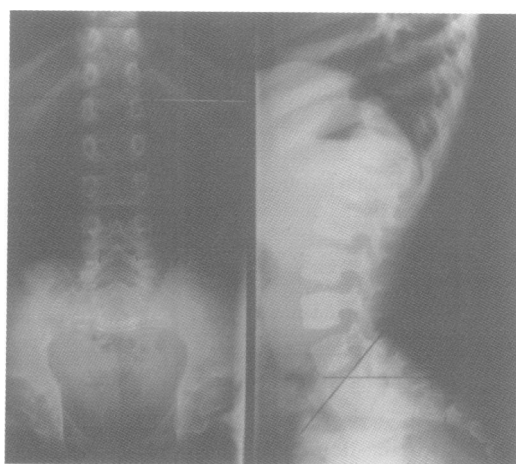


Figure 5 Constant interpediculate distances of 17 mm at the levels of first, third, and fifth lumbar vertebrae. The moderate lumbar lordosis ( $52^\circ$ ) is accentuated by a horizontally tilted sacrum (male, 9.5 years).

centuated by a horizontally tilted sacrum (fig 5).<sup>7</sup>

#### Differential diagnosis

Most of the 150 different osteochondrodysplasias result in disproportionate short stature and progressive problems in the joints and spine. The clinical features of CHH resemble those of hypochondroplasia (MIM 14600)<sup>1</sup> which, however, is a dominantly inherited condition and does not present with abnormal hair. It is easily differentiated from CHH by normal metaphyses in childhood skeletal radiographs. Murk Jansen (MIM 156400) and Schmid (MIM 156500) metaphyseal dysplasias are dominantly inherited conditions and result in severe growth failure but patients have normal immunity and erythropoiesis; these are easily distinguished from CHH. Recently, a type X collagen mutation was reported as the cause of Schmid chondrodysplasia.<sup>34</sup> Shwachman-Bodian syndrome (MIM 260400), an autosomal recessive condition with metaphyseal involvement, is associated with pancreatic insufficiency, malabsorption, and leucopenia; the mild skeletal changes are most evident in the proximal femora.

#### Epidemiology

CHH was originally described among the Old Order Amish, a religious isolate in the United States.<sup>2</sup> At least 113 Amish CHH patients have been recognised<sup>25</sup>; the incidence is estimated at 1-2:1000 corresponding to a carrier frequency of 1:10.<sup>2</sup> Another accumulation of the disease has been observed among Finns with 120 patients in a population of 5 million; the incidence is estimated at 1:23 000 live births and the carrier frequency at 1:76.<sup>8</sup> The number of diagnosed patients among other populations is low: 13 patients have been reported among the French, eight among the Dutch, seven among the British, and sporadic cases among the Germans, Danes, Algerians, Italians, Polish, Spanish, and Mexicans.<sup>35</sup> Whether this is because of underdiagnosis, under-reporting, or low incidence cannot be determined with certainty.

#### Mapping of the gene for CHH by linkage and linkage disequilibrium analysis

Assignment of the CHH gene to the proximal part of 9p was accomplished by a random search for linkage in 14 Finnish families.<sup>9</sup> Subsequently, linkage to the same locus was shown in a large series of Amish families.<sup>10</sup> No signs of heterogeneity within or between the two populations were detected.

As there were no recombinations within the highly polymorphic marker D9S163 (lod score 26.30 at  $\theta=0$ ) CHH could be placed in the vicinity of D9S163 in the 4 cM interval between markers D9S165 and D9S50. As both the Finnish and Amish populations had few founders and have remained highly isolated, it could be assumed that the number of ancestral mutations would be small, possibly with a single

mutation accounting for the majority of the patients in each population. Haplotype analyses and linkage disequilibrium studies confirmed this assumption.<sup>10</sup> Moreover, the strength of linkage disequilibrium was used to assess the distance between D9S163 and CHH by a recently developed method.<sup>36-38</sup> The current best estimate of this distance is 0.3 cM.<sup>39</sup>

### Genetics and penetrance

Genetic studies among Amish and Finnish families have confirmed the recessive mode of inheritance in CHH.<sup>2,8</sup> However, segregation analyses showed a slightly lower number of affected members than expected according to the recessive hypothesis. This has been explained by reduced penetrance or by the loss of affected children in utero or in infancy.<sup>2,8,35</sup>

The mapping of CHH and availability of closely linked polymorphic markers provide a tool to examine the question of penetrance. If reduced penetrance were responsible for the unexpectedly low proportion of affected children in CHH sibships, healthy persons with haplotypes identical to their affected sibs should be found. Such a phenomenon was looked for in a total of 66 unaffected sibs but was not found.<sup>9,10</sup> This finding is indeed credible as reduced penetrance appears to be very rare in recessively inherited disorders. Several other mechanisms might account for the observed under-representation of affected children,<sup>40</sup> which is more pronounced in the Amish<sup>2</sup> than in the Finnish series.<sup>8</sup> The haplotype analyses done in unaffected sibs appear to exclude not only reduced penetrance, but also genetic heterogeneity.<sup>9,10</sup> Remaining explanations are uniparental disomy, monosomy owing to deletion, biased ascertainment of families, early lethality in a fraction of homozygotes, and gametic selection.

### Prenatal diagnosis

As CHH may in some cases be severe or even fatal, some families with an affected child have requested prenatal testing for CHH. The precise mapping of the CHH gene with respect to several highly polymorphic DNA markers provides an excellent opportunity for accurate predictive testing based on the segregation of those markers in families with a previous history of CHH. Four prenatal determinations have so far been done; in three cases the fetus was predicted to be unaffected, and in one case an affected fetus was predicted.<sup>10A</sup> In all cases the outcome was as predicted.

### Hypotheses regarding the pathogenesis

The pathogenesis of the disorder remains unknown. However, since previous studies have established defective cellular proliferation of T and B lymphocytes and fibroblasts,<sup>4</sup> and defective erythropoiesis,<sup>26</sup> it is suggested that the clinical manifestations (growth failure, sparse hair, recurrent infections, anaemia, Hirschsprung's disease) in CHH may result from a generalised defect of cellular proliferation. It is intriguing to note that a gene

causing isolated Hirschsprung's disease located on chromosome 10 has recently been cloned.<sup>41,42</sup> It follows that one of the pleiotropic effects of the CHH gene, Hirschsprung's disease, arises either by a different mechanism from that in the isolated form of the disease, or by the interaction of the two genes. Additional studies are needed to elucidate further the molecular mechanisms in the pathogenesis of CHH. The solution will probably have to await the cloning and characterisation of the gene itself.

These studies have been supported by the Academy of Finland, the Sigrid Juselius Foundation, the March of Dimes Birth Defects Foundation, the Human Growth Foundation, the Päivikki and Sakari Sohlberg Foundation, the Finnish Medical Foundation, the University of Helsinki, and the Foundation for Paediatric Research.

- 1 McKusick VA. *Mendelian inheritance in man*. Baltimore: Johns Hopkins University Press, 1991.
- 2 McKusick VA, Eldridge R, Hostetler JA, Ruangwit U, Egeland JA. Dwarfism in the Amish. II. Cartilage-hair hypoplasia. *Bull Johns Hopkins Hosp* 1965;116:285-326.
- 3 Virolainen M, Savilahti E, Kaitila I, Perheentupa J. Cellular and humoral immunity in cartilage-hair hypoplasia. *Pediatr Res* 1978;12:961-6.
- 4 Polmar SH, Pierce GF. Cartilage hair hypoplasia: immunological aspects and their clinical implications. *Clin Immunol Immunopathol* 1986;40:87-93.
- 5 Mäkitie O, Kaitila I. Cartilage-hair hypoplasia - clinical manifestations in 108 Finnish patients. *Eur J Pediatr* 1993;152:211-7.
- 6 Ray HC, Dorst JP. Cartilage-hair hypoplasia. *Prog Pediatr Radiol* 1973;4:270-98.
- 7 Mäkitie O, Marttinen E, Kaitila I. Skeletal growth in cartilage-hair hypoplasia - a radiological study of 82 patients. *Pediatr Radiol* 1992;22:434-9.
- 8 Mäkitie O. Cartilage-hair hypoplasia in Finland: epidemiological and genetic aspects of 107 patients. *J Med Genet* 1992;29:652-5.
- 9 Sulisalo T, Sistonen P, Hästbacka J, et al. Cartilage-hair hypoplasia gene assigned to chromosome 9 by linkage analysis. *Nature Genet* 1993;3:338-41.
- 10 Sulisalo T, Francomano CA, Sistonen P, et al. High resolution genetic mapping of the cartilage-hair hypoplasia gene in Amish and Finnish families. *Genomics* 1994;20:347-53.
- 10A Sulisalo T, Sillence D, Wilson M, Rynnänen M, Kaitila I. Early prenatal diagnosis of cartilage-hair hypoplasia (CHH) with polymorphic DNA markers. *Prenat Diagn* (in press).
- 11 Mäkitie O, Perheentupa J, Kaitila I. Growth in cartilage-hair hypoplasia. *Pediatr Res* 1992;31:176-80.
- 12 Savage MO. Metaphyseal dysplasia in sibs: A variant of cartilage-hair hypoplasia (case report). *Proc R Soc Med* 1972;65:727.
- 13 Van der Burgt I, Haraldsson A, Oosterwijk JC, van Essen AJ, Weemaes C, Hamel B. Cartilage hair hypoplasia, metaphyseal chondrodysplasia type McKusick: description of seven patients and review of the literature. *Am J Med Genet* 1991;41:371-80.
- 14 Trojak JE, Polmar SH, Winkelstein JA, et al. Immunologic studies of cartilage-hair hypoplasia in the Amish. *Johns Hopkins Med J* 1981;148:157-64.
- 15 Ranki A, Perheentupa J, Andersson LC, Häyry P. In vitro T- and B-cell reactivity in cartilage hair hypoplasia. *Clin Exp Immunol* 1978;32:352-60.
- 16 Lischka A, Frisch H, Weissenbacher G. Radiologische Veränderungen bei metaphysärer Chondrodysplasie Typ McKusick (Knorpel-Haar-Hypoplasie). *Monatsschr Kinderheilkd* 1984;132:550-3.
- 17 Ammann AJ, Sutliff W, Millinchick E. Antibody-mediated immunodeficiency in short-limbed dwarfism. *J Pediatr* 1974;84:200-3.
- 18 Rubie H, Graber D, Fischer A, et al. Hypoplasie du cartilage et des cheveux avec deficit immunitaire combine. *Ann Pediatr (Paris)* 1989;36:390-2.
- 19 Saulsbury FT, Winkelstein JA, Davis LE, et al. Combined immunodeficiency and vaccine-related poliomyelitis in a child with cartilage-hair hypoplasia. *J Pediatr* 1975;86:868-72.
- 20 Steele RW, Britton HA, Anderson CT, Kniker WT. Severe combined immunodeficiency with cartilage-hair hypoplasia: in vitro response to thymosin and attempted reconstitution. *Pediatr Res* 1976;10:1003-5.
- 21 Wilson WG, Aylsworth AS, Folds JD, Whisnant JK. Cartilage-hair hypoplasia (metaphyseal chondrodysplasia, type McKusick) with combined immune deficiency: variable expression and development of immunologic functions in sibs. *Birth Defects* 1978;14:117-29.
- 22 Harris RE, Baehner RL, Gleiser S, Weaver DD, Hodes ME. Cartilage-hair hypoplasia, defective T-cell function, and Diamond-Blackfan anemia in an Amish child. *Am J Med Genet* 1981;8:291-7.
- 23 Hensley MF. McKusick's dwarfism and resistant Hodgkin's disease (letter). *J Am Osteopath Assoc* 1984;84:159.

- 24 Roberts MA, Arnold RM. Hodgkin's lymphoma in a child with cartilage-hair hypoplasia (case report). *Milit Med* 1984;149:280-1.
- 25 Francomano CA, Trojak JE, McKusick VA. Cartilage-hair hypoplasia in the Amish: increased susceptibility to malignancy (abstract). *Am J Hum Genet* 1983;35:89A.
- 26 Mäkitie O, Rajantie J, Kaitila I. Anaemia and macrocytosis - unrecognized features in cartilage-hair hypoplasia. *Acta Paediatr* 1992;81:1030-4.
- 27 Sacrez R, Levy JM, Godar G, Castanier J. Anémie de Blackfan-Diamond associé à des malformations multiples. *Med Infantile* 1965;72:493-9.
- 28 Roberts PAL, Mann TP, Rubin J. Hirschsprung's disease associated with a variant form of achondroplasia, in sister and brother (case report). *Proc R Soc Med* 1969;62:329.
- 29 Fauchier C, Régy JM, Combe P. Nanisme diastrophique familial avec maladie de Hirschsprung. *Ann Pediatr (Paris)* 1969;16:496-502.
- 30 Boothby CB, Bower BD. Cartilage hair hypoplasia. *Arch Dis Child* 1973;48:919-21.
- 31 Le Merrer M, Briard ML, Chauvet ML, Maroteaux P. Autosomal recessive metaphyseal chondrodysplasia and Hirschsprung's disease. *Ann Pediatr (Paris)* 1991;38:27-30.
- 32 Wood DJ, David TJ, Chrystie LL, Totterdell B. Chronic enteric virus infection in two T-cell immunodeficient children. *J Med Virol* 1988;24:435-44.
- 33 Lux SE, Johnston RB, August CS, et al. Chronic neutropenia and abnormal cellular immunity in cartilage-hair hypoplasia. *N Engl J Med* 1970;282:231-6.
- 34 Warman ML, Abbot M, Apte SS, et al. A type X collagen mutation causes Schmid metaphyseal chondrodysplasia. *Nature Genet* 1993;5:79-82.
- 35 Mäkitie O. *Cartilage-hair hypoplasia. Clinical, radiological and genetic study of an inherited skeletal dysplasia*. Thesis, University of Helsinki, 1992.
- 36 Luria SE, Delbrück M. Mutations of bacteria from virus sensitivity to virus resistance. *Genetics* 1943;28:491-511.
- 37 Hästbacka J, de la Chapelle A, Kaitila I, Sistonen P, Weaver A, Lander E. Linkage disequilibrium mapping in isolated populations: diastrophic dysplasia in Finland. *Nature Genet* 1992;2:204-11.
- 38 Lehesjoki AE, Koskiniemi M, Norio R, et al. Localization of the EPM1 gene for progressive myoclonus epilepsy on chromosome 21: linkage disequilibrium allows high resolution mapping. *Hum Molec Genet* 1993;2:1229-34.
- 39 Sulisalo T, Klockars J, Mäkitie, O, Francomano CA, de la Chapelle A, Kaitila I. High-resolution linkage-disequilibrium mapping of the cartilage-hair hypoplasia gene. *Am J Hum Genet* 1994;55:937-45.
- 40 Bunday S, Young ID. Low segregation ratios in autosomal recessive disorders. *J Med Genet* 1993;30:449-51.
- 41 Romeo G, Ronchotto P, Luo Y, et al. Point mutations affecting the tyrosine kinase domain of the RET proto-oncogene in Hirschsprung's disease. *Nature* 1994;367:377-8.
- 42 Edery P, Lyonnet S, Mulligan LM, et al. Mutations of the RET proto-oncogene in Hirschsprung's disease. *Nature* 1994;367:378-80.