

- ¹⁸ Sinet PM, Couturier J, Dutrillaux B, *et al.* Trisomic 21 et superoxyde dismutase-1 (IPO-A). Tentative de localisation sur le sous-bande 21q21.1. *Exp Cell Res* 1976;**97**:47-55.
- ¹⁹ Skovby F, Krassikoff N, Francke U. Assignment of the gene for cystathionine beta-synthase to human chromosome 21 in somatic cell hybrids. *Hum Genet* 1984;**65**:291-4.
- ²⁰ Chadeaux B, Rethoré MO, Raoul O, *et al.* Cystathionine beta-synthase: gene dosage effect in trisomy 21. *Biochem Biophys Res Commun* 1985;**128**:40-4.
- ²¹ Kraus JP, Williamson CL, Firgaira FA, *et al.* Cloning and screening with nanogram amounts of immunopurified mRNAs:

cDNA cloning and chromosomal mapping of cystathionine beta-synthase and the beta subunit of propionyl-CoA carboxylase. *Proc Natl Acad Sci USA* 1986;**83**:2047-51.

Correspondence and requests for reprints to Dr Nancy J Carpenter, H Allen Chapman Research Institute of Medical Genetics, Children's Medical Center, 5300 East Skelly Drive, Tulsa, Oklahoma 74135, USA.

Deletion 15q21.1→q22.1 resulting from a paternal insertion into chromosome 5

MOH-YING YIP*, MARK SELIKOWITZ†, NEVILLE DON†, ALEX KOVACIC*, S PURVIS-SMITH*, AND P R L LAM-PO-TANG*

*Cytogenetics Unit, Prince of Wales Hospital, and †Department of Paediatric Medicine, Prince of Wales Children's Hospital, Sydney, Australia.

SUMMARY A 15 month old boy with an interstitial deletion 15q derived from a paternal insertion (5;15)(q31.3;q21.1q22.1) is described and compared with one other reported case. A beak like nose with hypoplastic nasal alae, a thin upper lip, failure to thrive in infancy with later onset of obesity, and severe mental retardation are features common to both.

Insertions involving three breakpoints are the least common chromosome rearrangements in man.¹ With banding studies, insertions have been detected between and within chromosomes. We are aware of 21 published reports of interchromosomal insertions. We describe here a case of an interstitial deletion of 15q21.1→q22.1 derived from a paternal insertion in a 15 month old boy.

Case report

The proband was the first live born child of healthy, unrelated parents. At his birth, the mother was 25 and the father 30. There were three previous miscarriages at six, eight, and 12 weeks.

The pregnancy with the proband was complicated by polyhydramnios and decreased fetal movement which developed at 30 weeks. Caesarian section was performed at 35 weeks' gestation for intrauterine growth retardation. The Apgar scores were 8 and 9 at one and five minutes, respectively. The birth

weight was 1680 g (less than the 3rd centile), head circumference 30.7 cm (10th centile), and birth length 40 cm (3rd centile). Dysmorphic features noted at birth were: narrow bifrontal diameter, a patent posterior fontanelle, low temporal hair implantation, and low set ears. The mouth had a thin upper lip and was usually kept open. The nose was beak shaped with poor development of the nasal alae (fig 1a). The hands were held in ulnar deviation and there was bilateral clinodactyly of the fifth fingers and simian creases. Dermal ridge whorl patterns were present on all 10 fingers. Creases were decreased around the elbows and knees which, however, had a full range of movement (fig 1b). The testes were bilaterally undescended with an underdeveloped scrotum. Bilateral inguinal herniae were present and the penis was of normal size but hooded with coronal hypospadias and chordee.

There was hypotonia and poor feeding. He had occasional apnoeic episodes during the neonatal period. A chest x ray showed a raised anteromedial portion of the right hemidiaphragm which was inserted high on the posterior surface of the sternum. X ray of the spine showed that the vertebral bodies had a square outline and reduction of interpedicular distances in the lumbar region.

From the age of six months the patient has gained weight rapidly despite dietary joule restriction. At present, at the age of 15 months, his weight is on the 90th centile and his length on the 10th centile. His psychomotor development corresponds to a six month level. He has developed a mild degree of scoliosis and strabismus associated with myopia.

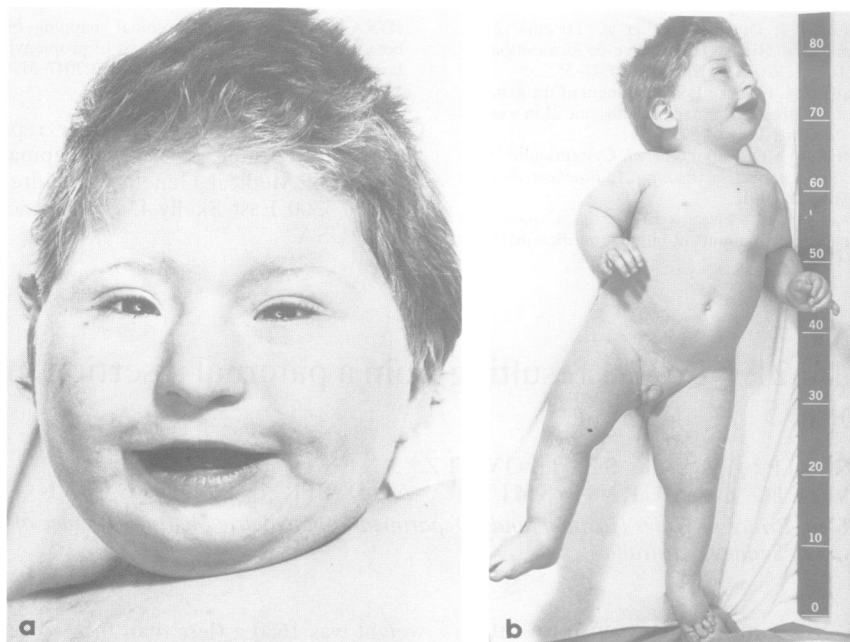


FIG 1 Clinical features of patient. (a) Facial dysmorphism: narrow bifrontal diameter, low temporal hair implantation, beak shaped nose, and thin upper lip. (b) Hypotonia, bilateral clinodactyly of fifth fingers, and obesity.

CYTOGENETIC STUDIES

Cytogenetic studies were performed on peripheral blood lymphocytes and G banded karyotypes of the proband, his parents, and a paternal uncle were examined. The proband's father has one other sib, a sister with short stature. Neither the sister nor any other members of the father's family would agree to being physically examined or having cytogenetic studies carried out. GTG banding revealed an interstitial deletion of chromosome 15q in the proband. The mother's and paternal uncle's chromosomes were normal. The phenotypically normal father had a similarly deleted chromosome 15 but with the deleted region inserted into the distal long arm of a chromosome 5. The exact breakpoints of the insertion were confirmed by high resolution G banding (fig 2). The father's karyotype was 46,XY,ins(5;15)(q31·3;q21·1q22·1) and that of the proband 46,XY,-15,+der(15),ins(5;15)(q31·3;q21·1q22·1)pat.

Discussion

The majority of interstitial deletions of chromosome 15 reported have been those proximal to the centromere in subjects with the Prader-Willi syn-

drome. Those not associated with Prader-Willi syndrome include a del(15)(q12→q14) mosaic with congenital heart disease,² a del(15)(q21) with mental retardation,³ and a del(15)(q22q24) with features of Potter's syndrome.⁴

Fryns *et al*³ reported the one other patient with an interstitial deletion involving 15q21. A comparison of the clinical findings in our patient and that of Fryns *et al*³ is shown in the table. In both cases, the pregnancy was complicated by polyhydramnios and diminished fetal movements. Failure to thrive in infancy was common to both, as was the later onset of obesity. The facial features show a striking similarity with beak like nose, hypoplastic nasal nasi, and a thin upper lip. Scoliosis developed in both patients and both have severe mental retardation. A notable difference was the absence of microcephaly and spastic paraplegia in our patient.

In our case, the proband received his deleted 15q chromosome from random segregation of one of the two derivative chromosomes involved in the paternal insertion. With the small size of the insertion, multivalent formation at meiosis with possible crossing over would seem unlikely. Small insertions generally lead to the formation of unequal bivalents with the derivative chromosomes involved being

paired with their respective homologues. Random segregation would produce either balanced, normal, or two types of unbalanced gametes arising from nullisomy or disomy for the insertion in question.

Of the familial balanced interchromosomal insertions reported, only one family has been described

where an unbalanced offspring was produced from a crossover within the insertion loop during multivalent formation at meiosis.⁵ It is noteworthy that half of a chromosome 5 long arm had been involved in the balanced maternal insertion.

The cause of the three first trimester miscarriages

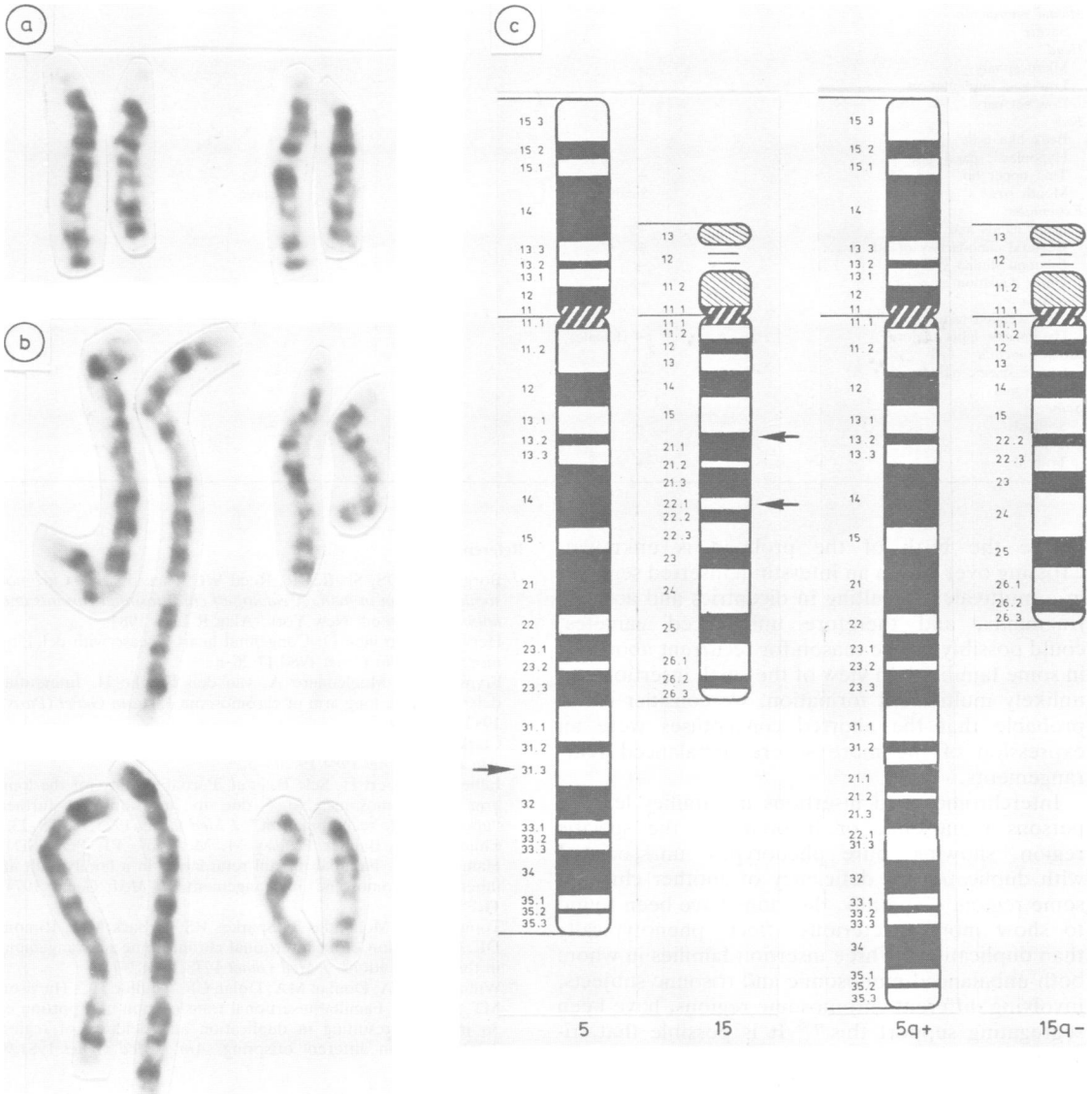


FIG 2 (a) Two pairs of chromosome 15 in the proband. The deleted chromosomes 15 are on the right. (High resolution G banding.) (b) Two pairs of chromosomes 5 and 15 involved in the balanced insertion in the proband's father. The derivative chromosomes are on the right. (High resolution G banding.) (c) Diagram of insertion in the father. Arrows indicate breakpoints.

TABLE Clinical findings in patients with partial monosomy 15q21.

	Fryns <i>et al</i> ³	Present report
Monosomic region	15q21	15q21·1→15q22·1
Origin of partial monosomy	De novo	Ins(5;15)(q31·3;q21·1q22·1)pat
<i>Pregnancy</i>		
Polyhydramnios	+	+
Diminished fetal movements	+	+
<i>Infancy</i>		
Failure to thrive	+	+
<i>Mental retardation</i>		
Severe	+	+
<i>Head</i>		
Microcephaly	+	-
Low hair implantation	+	+
Low set ears	+	+
<i>Face</i>		
Beak like nose	+	+
Hypoplastic nasal alae	+	+
Thin upper lip	+	+
Mouth size	Small	Large
<i>Extremities</i>		
Small hands and feet	+	-
Bilateral clinodactyly of 5th finger	+	+
Bilateral simian creases	-	+
Ulnar deviation at wrist	-	+
<i>Genitalia</i>		
Undescended testes		+
Hypoplastic labia majora	+	(female)
<i>Motor function</i>		
Severe spastic paraplegia	+	-
Hypotonia	-	+
<i>Spine</i>		
Scoliosis	+	-
<i>Obesity</i>		
Truncal	+	+

before the birth of the proband is unknown. Crossing over within an interstitial inserted segment in a multivalent resulting in dicentric and acentric fragments, and therefore unbalanced gametes, could possibly be the reason for recurrent abortions in some families.⁶ In view of the small insertion and unlikely multivalent formation, we consider it improbable that the aborted conceptuses were an expression of the more severe unbalanced rearrangements.

Interchromosomal insertions in families lead to persons monosomic or trisomic for the specific region, showing 'pure phenotypes' unassociated with duplication or deficiency of another chromosome region. Generally, deletions have been found to show more deleterious effects phenotypically than duplications. Three insertion families in whom both unbalanced monosomic and trisomic subjects, involving different chromosome regions, have been segregating support this.⁶⁻⁸ It is possible that trisomy for the segment in the present family would survive to term and show fairly mild dysmorphic features. If so, would monosomy be implicated in a range of viability from early fetal loss to abnormal survivors like the proband? It is unknown which, if any, of these two conditions were associated with the early fetal loss in this family.

References

- Borgaonkar DS, Shaffer R, Reed WC, Jackson LG. *Chromosomal variation in man. A catalog of chromosomal variants and anomalies*. 4th ed. New York: Alan R Liss, 1984.
- Herva R, Vuorinen O. Congenital heart disease with del(15q) mosaicism. *Clin Genet* 1980;17:26-8.
- Fryns JP, de Muclenaere A, van den Berghe H. Interstitial deletion of the long arm of chromosome 15. *Ann Genet (Paris)* 1982;25:59-60.
- Clark RD. Del(15)(q22q24) syndrome with Potter sequence. *Am J Med Genet* 1984;19:703-5.
- Jalbert P, Jalbert H, Sele B, *et al*. Partial trisomy for the long arm of chromosome No 5 due to insertion and further "aneusomic de recombinaison". *J Med Genet* 1975;12:418-23.
- Chudley AE, Bauder F, Ray M, McAlpine PJ, Pena SDJ, Hamerton JL. Familial mental retardation in a family with an inherited chromosome rearrangement. *J Med Genet* 1974; 11:353-63.
- Toomey KE, Mohandas T, Sparkes RS, Kaback MM, Rimoin DL. Segregation of an interstitial chromosome rearrangement in three generations. *J Med Genet* 1978;15:382-7.
- Williamson RA, Donlan MA, Dolan CR, Thuline HC, Harrison MT, Hall JG. Familial interstitial translocation of a portion of 3q into 11q resulting in duplication and deletion of region 3q22·1→q24 in different offspring. *Am J Med Genet* 1981;9: 105-11.

Correspondence and requests for reprints to Dr Moh-Ying Yip, Cytogenetics Unit, Prince of Wales Hospital, High Street, Randwick, NSW 2031, Australia.