

Syndrome of the month

Journal of Medical Genetics 1988, 25, 488-490

Pseudoxanthoma elasticum (Grönblad-Strandberg syndrome)

DENIS VILJOEN

From the Department of Human Genetics, Medical School, University of Cape Town, Observatory 7925, South Africa.

Pseudoxanthoma elasticum (PXE) is a rare disorder of elastin which primarily involves the skin, cardiovascular system, and eyes, but also manifests in the central nervous system, skeleton, and gastrointestinal tract. Rigal¹ first described the cutaneous lesions of PXE in 1881 and thought the disorder was akin to the xanthomatoses. In 1896, Darier² showed the typical histological changes in elastin fibres, thus proving that PXE was a separate condition. Grönblad and Strandberg subsequently recognised the association between ophthalmological and dermatological features in PXE and their names are sometimes eponymously applied to the disorder.³

Incidence

The true frequency of PXE is unknown but estimates range from 1:160 000 to 1:1 000 000 of the population.⁴ There appears to be no specific ethnic or population predilection, but more affected females than males have been reported. This probably reflects an ascertainment bias as women are more likely to seek medical attention for cosmetic reasons.

Clinical aspects

SKIN

The typical manifestations of PXE are yellowish papular lesions in the flexures associated with mild skin redundancy. The nape of the neck is the most frequently affected, followed by the axillae, groins, and antecubital fossae (fig 1). A rare, generalised form of PXE has been described in which the skin is very lax and non-flexural areas are involved.⁵

EYE

Although not pathognomonic of PXE, angioid

streaks or breaks in Bruch's membrane of the retina occur in 85% of affected subjects. These lesions tend to extend radially from the optic disc (fig 2). Neovascularisation, oedema, haemorrhage, and eventual fibrosis lead to visual deterioration which may be profound when the macula is involved.⁶

CARDIOVASCULAR SYSTEM

Premature obliterative arteriosclerotic changes of the medium and small sized arteries result in diminished pulses, cold peripheries, intermittent claudication, renovascular hypertension, angina, and cerebrovascular accidents. Mitral valve prolapse is reported to be common in one form of PXE.⁷

GASTROINTESTINAL

Despite a plethora of single case reports, GIT haemorrhage is an infrequent complication of PXE. When it occurs, bleeding is probably the result of structural weaknesses in the submucosal blood vessels of the stomach.³

OTHER FEATURES

Clinical features less frequently reported are pre-senile dementia, peripheral neuropathy, and an increased risk to the affected female of having a miscarriage in the first trimester.⁸ Minor radiological changes include calcification of the falx cerebri.

Differential diagnosis

Solar and actinic (senile) elastosis have cutaneous features which are very similar to PXE. Occasionally, penicillamine and vitamin D toxicity can produce skin lesions which resemble those of PXE, but can be histologically differentiated. Patients with cutis laxa have skin redundancy but no other stigmata of PXE.

Received for publication 12 January 1988.

Revised version accepted for publication 1 February 1988.

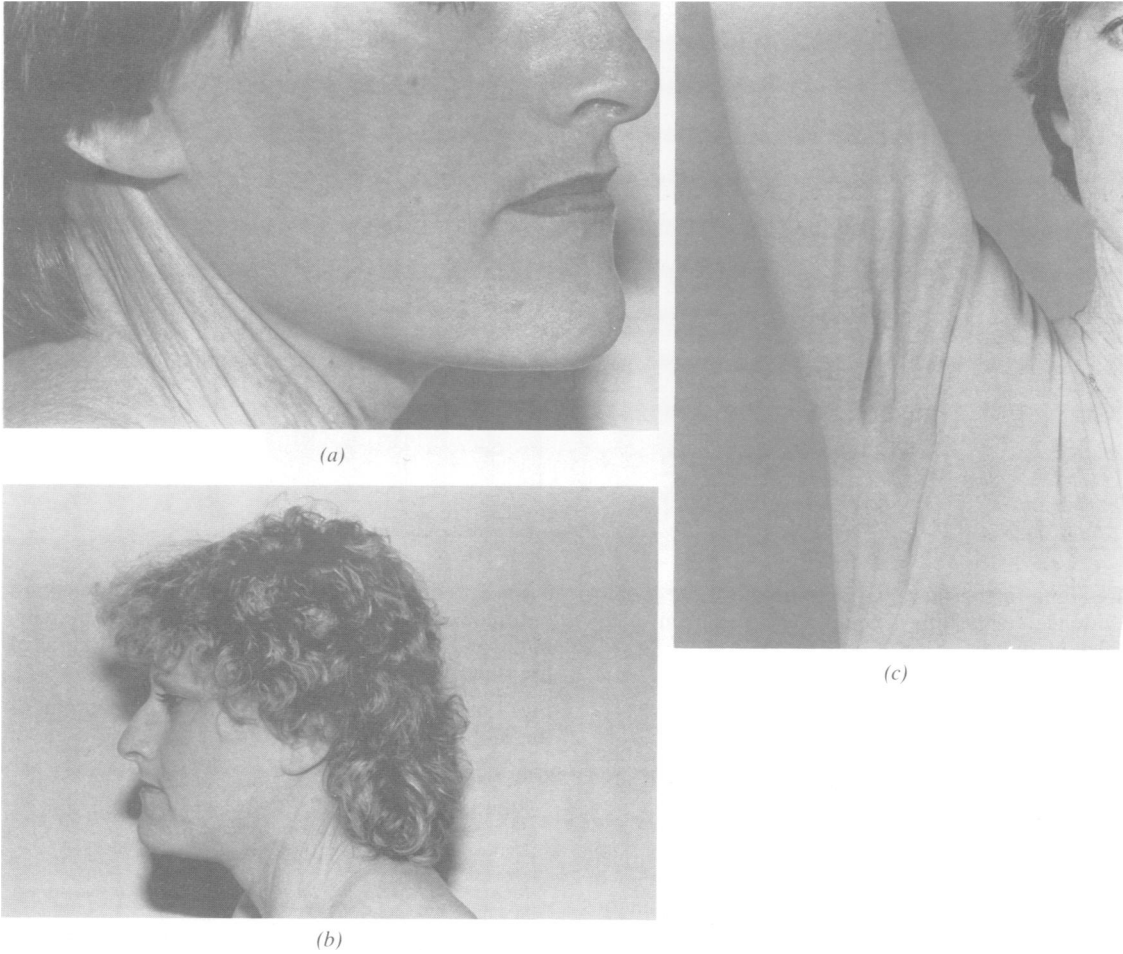


FIG 1 Loose, thickened skin folds in a patient with PXE (a) before surgery and (b) after surgery. (c) Marked cutaneous laxity in the axilla.

Investigations

Skin biopsy may be the only means of differentiating between the aforementioned disorders and PXE. The characteristic skin changes occur in the deep and middle zones of the corium where large aggregations of degenerate elastin fibres are found. Calcification of elastin fibres is the earliest histological abnormality in skin from affected subjects and this phenomenon is progressive. Collagen is said to be unaffected in PXE.

Routine annual review of the cardiovascular and ophthalmological status of affected persons is imperative in order to treat early hypertension and also to avoid the sequelae of angioid streaks extending

into the macula of the eye area. Bleeding and neovascularisation in the latter lesions causes severe visual impairment and extension of angioid streaks may be prevented through the use of laser therapy.

Natural history and management

PXE is a progressive disorder and affected subjects have an increased propensity for ischaemic heart disease, cerebrovascular accidents, visual impairment, and cosmetic deterioration of the skin. Life expectancy is reduced as compared with the general population.

Early medical treatment of hypertension, cosmetic surgery, and laser therapy for eye complications

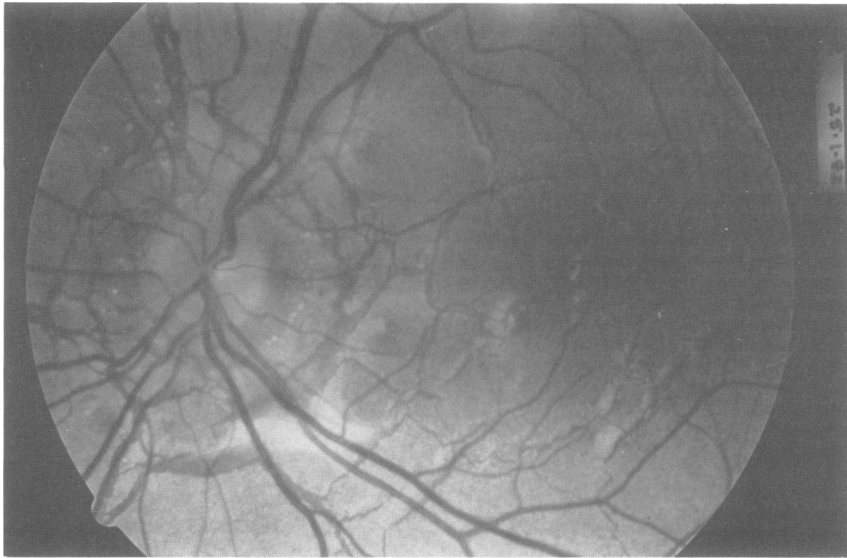

FIG 2 Ocular fundus of a PXE patient showing angioid streaks and retinal sclerosis.

are some of the therapeutic options. There is some evidence suggesting a beneficial effect from a low calcium diet.⁹

Inheritance

PXE is heterogeneous and five forms have been described which are phenotypically distinct.^{5 10 11} Pope¹⁰ delineated four types.

Autosomal recessive type I. These patients have vascular and retinal degeneration accompanied by flexurally distributed peau d'orange cutaneous lesions.

Autosomal recessive type II. This is a very rare variant presenting with generalised skin manifestations and no systemic involvement.

Autosomal dominant type I. This form is characterised by severe retinal and cardiovascular degeneration, accompanied by classic cutaneous features. Early blindness and coronary artery disease frequently result.

Autosomal dominant type II. Mild cardiovascular and retinal changes, together with Marfanoid features of hyperextensible joints, blue sclerae, and a highly arched palate, characterise this form.

A fifth distinct form of PXE has recently been described in 39 patients from 24 families in the Afrikaner community in Southern Africa.¹¹ Affected persons have mild to moderate cutaneous and

cardiovascular manifestations together with severe ophthalmological lesions. Profound visual impairment or blindness occurs from the third decade of life onwards. Inheritance is autosomal recessive.

Fig 1 is reproduced with the kind permission of the editor of *Clinical Genetics*.

References

- Rigal D. Observations pour servir à l'histoire de la cheloïde diffuse xantholasmique. *Ann Dermatol Syph* 1881;2:491-5.
- Darier J. Pseudoxanthoma elasticum. *Monatsschr Prakt Dermatol* 1896;23:609-14.
- McKusick VA. *Heritable disorders of connective tissue*. 4th ed. St Louis: CV Mosby, 1973:475-520.
- Berlyne GM, Bulmer HG, Platt R. The genetics of pseudoxanthoma elasticum. *Q J Med* 1961;30:201-6.
- Pope FM. Two types of autosomal recessive pseudoxanthoma elasticum. *Arch Dermatol* 1974;110:209-12.
- Clarkson JG, Altman RD. Angioid streaks. *Surv Ophthalmol* 1982;26:235-46.
- Lebwohl MG, Distefano D, Prioleau PG, et al. Pseudoxanthoma elasticum and mitral valve prolapse. *N Engl J Med* 1982;307:228-31.
- Viljoen DL, Beatty S, Beighton P. The obstetric and gynaecological implications of pseudoxanthoma elasticum. *Br J Obstet Gynaecol* 1987;94:1-5.
- Pyeritz RE, Weis JL, Rencic WA, et al. Pseudoxanthoma elasticum and mitral valve prolapse. *N Engl J Med* 1982;307:1451-2.
- Pope FM. Historical evidence for the genetic heterogeneity of pseudoxanthoma elasticum. *Br J Dermatol* 1975;92:493-509.
- Viljoen DL, Pope FM, Beighton P. Heterogeneity in pseudoxanthoma elasticum: delineation of a new form? *Clin Genet* 1987;32:100-5.

Correspondence and requests for reprints to Dr D Viljoen, Department of Human Genetics, University of Cape Town Medical School, Observatory 7925, South Africa.