

oesophagus, intestinal tract, liver, pancreas, spleen, or kidneys.

The present patient is another example of non-chromosomal association of holoprosencephaly and postaxial hexadactyly limited to the hands. It is interesting to note that in the patient of Young and Madders¹ and in the present case the postaxial polydactyly is limited to the hands. In trisomy 13 a holoprosencephaly sequence may be present and is associated with postaxial hexadactyly of the hands and feet. As discussed by Young and Madders, the association of holoprosencephaly and postaxial polydactyly of the hands does not fit into any hitherto delineated MCA syndrome.

P MOERMAN* AND J P FRYNS†

*Department of Histopathology and
†Centre for Human Genetics,
University of Leuven,
UZ Gasthuisberg,
Herestraat 49,
B-3000 Leuven,
Belgium.

Reference

- ¹ Young ID, Madders DJ. Unknown syndrome: holoprosencephaly, congenital heart defects, and polydactyly. *J Med Gen* 1987;24:714-5.

Holoprosencephaly, ventricular septal defect, and postaxial polydactyly in a human embryo

SIR,

In the November 1987 issue of the *Journal*, Young and Madders¹ reported a stillborn male infant with holoprosencephaly, cardiac anomalies, and postaxial polydactyly. This is a new dysmorphic syndrome which has not been fitted into any established clinical entity.

We report here a six week male embryo with a similar syndrome. The embryo was studied after induced abortion on a healthy 25 year old woman for socioeconomic reasons (Eugenics Protection Law of Japan). Her husband was 31 years old and the couple was non-consanguineous. Their family history was unremarkable. They had one normal child and one previous induced abortion. The mother had regular menstrual cycles and her pregnancy was uneventful. She took no alcohol, cigarettes, or medication during pregnancy. The pregnancy was terminated on the 45th day after estimated ovulation by dilatation and curettage.

The embryo was at Carnegie stage 20² and its crown-rump length was 18.8 mm. Externally, ethmocephaly with a proboscis and closely set eyes

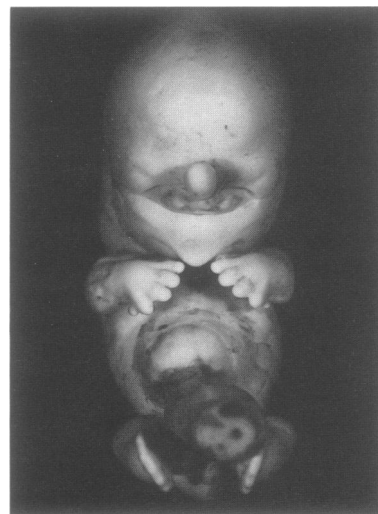


FIG 1 AP view of the embryo. Note the proboscis and closely set eyes.

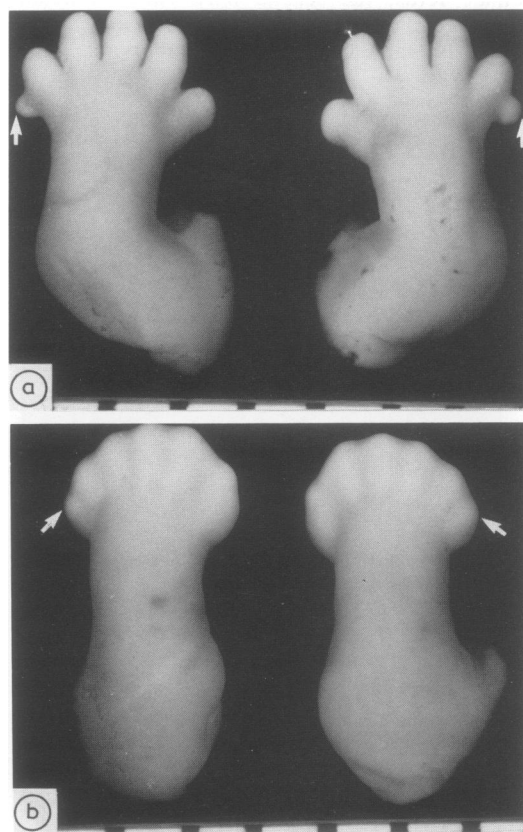

FIG 2 Upper (a) and lower (b) limbs showing supernumerary digits on the postaxial side (arrows).

was noted (fig 1). Bilateral postaxial polydactyly was found in both upper and lower limbs (fig 2). External genitalia were at an undifferentiated stage. There were only two vessels in the cord. The whole body was serially sectioned, stained with haematoxylin and eosin, and examined microscopically. Internal anomalies included alobar holoprosencephaly with absence of midline structures, ventricular septal defect (membranous portion), and single umbilical artery. No abnormalities were noted in the trachea, lungs, gastrointestinal tract, liver, pancreas, or urogenital organs. Histologically, the gonadal sex was male.

KOHEI SHIOTA AND TAKASHI TANIMURA
*Congenital Anomaly Research Centre,
 Faculty of Medicine,
 Kyoto University, Kyoto 606; and
 Department of Anatomy,
 Kinki University School of Medicine,
 Osaka-Sayama 589,
 Japan.*

References

- Young ID, Madders DJ. Unknown syndrome: holoprosencephaly, congenital heart defects, and polydactyly. *J Med Genet* 1987;24:714-5.
- O'Rahilly R, Müller F. *Developmental stages in human embryos*. Washington DC: Carnegie Institution of Washington, 1987.

Syndactyly, ectodermal dysplasia, and cleft lip and palate

SIR,

Recently, each of us reported independently in the journal a family in which two children were affected with a syndrome which seemed to be new.^{1,2}

TABLE Main clinical features of the syndrome.

	Zlotogora et al ¹		Ogur and Yukse ²	
	Male	Female	Male	Male
Sex				
Cleft lip and palate	+	+	+	+
Partial syndactyly				
Fingers	3-4	3-4	2-3-4	2-3-4
Toes	2-3*	2-3*	2-3	2-3
Ectodermal dysplasia				
Abnormal hair	+	+	+	+
Pili torti				'Kinky'
Thickened, dry skin	+†	-	+	+
Abnormal teeth	+	NR	+	+
Normal nails	+	+	+	+
Mental retardation	Mild‡	NR		Moderate
Consanguineous parents		+		+

- = Not present in the child. NR = not relevant since the child died very young.

*Owing to an error in the original article the syndactyly of the toes was reported to be between toes 3 and 4.

†Appeared at the age of four years, mainly on the palms and soles.

‡At the age of four years the child had caught up most of the delay and was only mildly retarded. Speech was very delayed.

Comparison of the clinical signs show that although the families are unrelated, the affected children present with very similar features, which are summarised in the table. It seems that this represents a distinct syndrome which is inherited as an autosomal recessive disorder. Additional cases are needed for further delineation of the syndrome.

J ZLOTOGORA* AND G OGU†
 *Department of Human Genetics,
 Hadassah Medical Center, Jerusalem,
 il 91 110 Israel; and
 †the Institute of Child Health,
 University of Istanbul, Çapa/Istanbul, Turkey.

References

- Zlotogora J, Zilberman Y, Tenenbaum A, Wexler MR. Cleft lip and palate, pili torti, malformed ears, partial syndactyly of fingers and toes, and mental retardation: a new syndrome? *J Med Genet* 1987;24:291-3.
- Ogur G, Yuksel M. Association of syndactyly, ectodermal dysplasia, and cleft lip and palate: report of two sibs from Turkey. *J Med Genet* 1988;25:37-40.

Are 'upper' and 'lower' neural tube defects aetiologically different?

SIR,

The idea that anencephaly and spina bifida cystica are aetiologically related, since each occurs with increased frequency in sibs of probands with the other,¹ may need reconsideration. In two studies,^{2,3} families of probands with neural tube defects were classified according to whether the lesion was 'upper' (anencephaly and thoracic spina bifida, which arise by failure of neurulation) or 'lower' (lumbar and sacral, which represent errors in canalisation⁴). All of 25 sib pairs were concordant as to level, suggesting that the two types are genetically different.^{2,3} T11 to T12 was considered the dividing point between upper and lower lesions.

In contrast, during an epidemiological study of neural tube defects in Newfoundland,⁵ we noted 11 pairs of affected sibs, without other malformations, of which four were discordant for level of lesion.

In family A, a girl was born with a lumbosacral myelomeningocele involving L1 to S3, with diastematomyelia of L1 (lower), followed by a sister with anencephaly and cervical spina bifida (upper). In family B, a girl with a lumbosacral myelomeningocele involving L1 to S3 (lower) was followed by a brother with a myelomeningocele of T10 to S3 (upper). In family C, the first boy was born with a tuft of hair in