

“Pure” partial trisomy 4q25-qter owing to a de novo 4;22 translocation

Ruth V Mikelsaar, I W Lurie, Tiiu E Ilus

Abstract

A girl with a new de novo translocation of 4q onto the short arm of acrocentric 22 is reported as a case of “pure” partial trisomy 4q. Her karyotype was 46,XX,-22,+mar,t(4;22)(q25→qter;p11) identified by Giemsa staining and FISH. Comparison of the proband with previously reported cases of “pure” partial trisomy 4q showed the main clinical features to be growth retardation, psychomotor retardation, microcephaly, large, low set, malformed ears, prominent nasal bridge, ptosis and epicanthus.

(J Med Genet 1996;33:344-345)

Key words: partial trisomy 4q25-qter; translocation 4;22.

At present, only three cases of “pure” partial trisomy 4q have been reported where a 4q segment is translocated onto an acrocentric: two were de novo^{1,2} and one was inherited.³ In addition, there are six cases of partial trisomy 4q owing to de novo duplications.⁴ The present report describes a new case of “pure” partial trisomy 4q owing to a de novo t(4;22)(q25;p11) translocation.

The proband, a girl, was the second child of healthy and unrelated parents. At the child's birth, her mother was 32 and her father was 39 years old. The mother had a history of two induced abortions and one healthy girl. At 3 months, the pregnancy was complicated by a virus infection and fever. The delivery was uneventful and the child was born at 38 weeks. The birth weight was 1850 g, length 42 cm, and head circumference 29 cm. Examination at the age of 18 months showed a girl with short stature (76 cm), mild microcephaly (43 cm), muscular hypotonia, and a small umbilical hernia (fig 1). She had epicanthus, slightly downward slanting palpebral fissures, left sided ptosis, and a prominent nasal bridge. The pro-

truding upper lip with short philtrum formed a “carp mouth”. She had large, low set, malformed ears and a short neck. There were shortened fingers and bilateral simian creases. Her psychomotor and mental development was delayed. At the age of 7 years she was severely mentally retarded. Her height was 105 cm, weight 14 kg, head circumference 47 cm, and she had bilateral partial ptosis. CT scan of the brain and ultrasound examinations of the heart, urinary system, and other internal organs showed no congenital anomalies. An x ray examination showed an extra cervical rib and spina bifida occulta of the 10th and 11th thoracic vertebrae.

Department of Human Biology and Genetics, Institute of General and Molecular Pathology, University of Tartu, Veski Street 34, Tartu EE2400, Estonia
R V Mikelsaar

Foundation for Developmental and Medical Genetics, Helena, Montana, USA
I W Lurie

Children's Hospital, University of Tartu, Estonia
T E Ilus

Correspondence to:
Dr Mikelsaar.

Received 28 April 1995
Revised version accepted for publication
29 November 1995

Clinical features of “pure” partial trisomy 4q

	Nine “pure” cases ¹⁻⁴	Our proband
Growth retardation	8/8	+
Psychomotor retardation	8/8	+
Microcephaly	7/9	+
Large, low set ears	6/8	+
Prominent nasal bridge	7/8	+
Ptosis/narrow palpebral fissures	5/6	+
Epicanthus	5/6	+
Downward slanting eyes	1/3	+
Short philtrum	5/8	+
“Carp mouth”	5/8	+
Retromicrognathia	5/8	-
Thumb anomalies	2/9	-
Vertebral anomalies	3/8	+
Congenital heart disease	3/8	+
Renal anomalies	2/7	-
Epilepsy	3/8	-

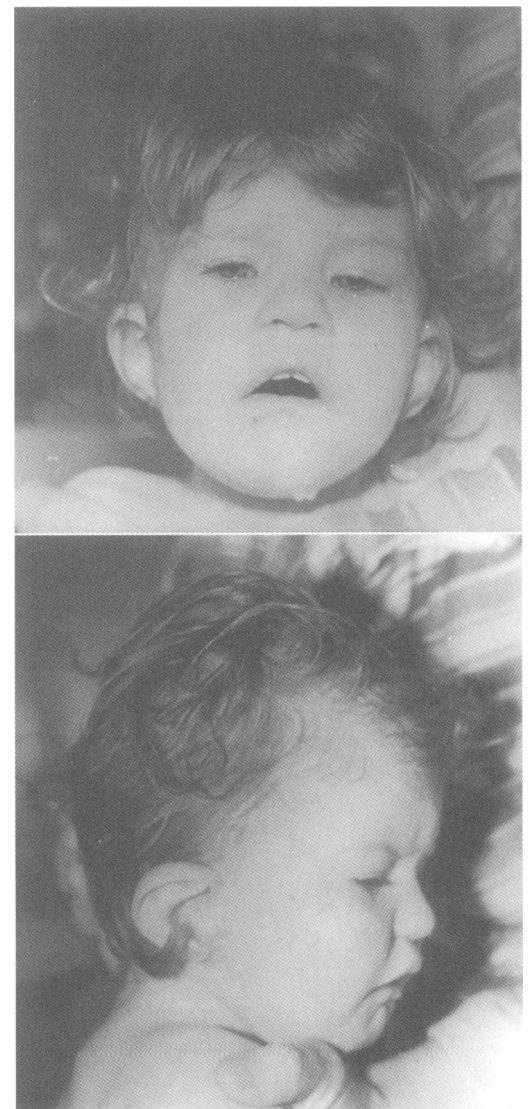


Figure 1 Proband at 1½ years old.

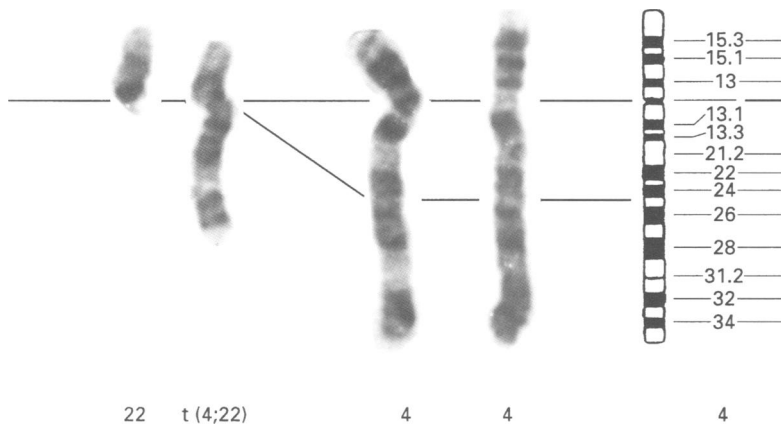


Figure 2 Partial karyotype of the proband.

Chromosome analysis on cultured lymphocytes using GTG banding and fluorescence in situ hybridisation (FISH) with whole chromosome 4 painting probe showed that the enlarged short arm of the chromosome 22 consisted of 4q25-qter material. The proband's karyotype (fig 2) was 46,XX,-22,+der(22),t(4;22)(q25;p11). The karyotypes of her mother, father, and sister were normal.

The clinical features of our proband and previously reported cases of "pure" partial tri-

somy 4q are quite similar (table). The constant features include growth retardation, psychomotor retardation, microcephaly, large low set, malformed ears, prominent nasal bridge, ptosis or narrow palpebral fissures or both, and epicanthus. Short philtrum, "carp mouth", and retromicrognathia are relatively common. These features can be considered characteristics of the partial trisomy 4q syndrome.

Major congenital anomalies are not very frequent: congenital heart disease in 30% and renal malformations in 20% of the reported cases.⁴ No malformations of these organs or the brain were observed in our patient; however, she had vertebral anomalies. Differences in the phenotype of the reported cases might be related to the different segment of 4q involved or the parental origin of the aberration.

We wish to thank Professor E Schwinger and Dr K Ballestrin from the Institute of Human Genetics in Lübeck for the instructions for FISH.

- 1 Yunis E, Giraldo A, Zuniga R, *et al.* Partial trisomy 4q. *Ann Genet (Paris)* 1977;20:243-8.
- 2 Furneau C, Speleman F, Van Roy N, *et al.* Pure terminal 4q duplication in a mentally retarded male: a recognizable phenotype. *26th Annual Meeting of ESHG, Paris, 1994:178.*
- 3 Priest FJ, Clarkson M, Nevin NC, *et al.* Duplication of 4q syndrome resulting from a familial 4;14 translocation. *J Med Genet* 1991;28:573.
- 4 Jeziorowska A, Ciesla W, Houck GE, *et al.* Cytogenetic and molecular identification of a de novo direct duplication of the long arm of chromosome 4(q21.3-31.3). *Am J Med Genet* 1993;46:83-7.