

A case of duplication of 13q32→qter and deletion of 18p11.32→pter with mild phenotype: Patau syndrome and duplications of 13q revisited

Nasser Helali, A Kimberly Iafolla, Stephen G Kahler, Mazin B Qumsiyeh

Abstract

A mild clinical phenotype is described in a patient with duplication of 13q32→qter and a small deletion of 18p11.32→pter. The 8 year old white male presented with psychomotor retardation, tethered cord, soft, fleshy ears, and normal facial features except for thin lips. The karyotype was found to be 46,XY,der(18)t(13;18)(q32;p11.32)pat confirmed by fluorescence in situ hybridisation (FISH). A review of earlier studies showed that features of trisomy 13 are found in cases of duplication of bands 13q14 to qter. None of the cardinal features of trisomy 13 was seen in this patient. The absence of polydactyly, hernias, urogenital abnormalities, and haemangiomas contrast this condition with both trisomy 13 and duplication of 13q14-22→qter. Possible explanations for lack of Patau syndrome in this patient could include restriction of the critical region for Patau syndrome to duplication 13q14→13q32 with variable expression, gene interactions, or interchromosomal effects.

(*J Med Genet* 1996;33:600-602)

Key words: trisomy 13; Patau syndrome: phenotype-karyotype correlation.

The classical features of Patau syndrome or trisomy 13 are defects of the auricles, eyes (microphthalmia, iris coloboma, strabismus, etc), and mouth (cleft lip, palate or both), holoprosencephaly sequence (including arhinencephaly, cebocephaly, and others), haemangiomas, polydactyly, hyperconvex fingernails, scalp defects, and heart defects (reviewed by Tharapel *et al*¹). Partial duplications for proximal segments (13q11→q14) alone show some features of Patau syndrome: including strabismus, depressed nasal bridge, stubby nose, cleft lip/palate, clinodactyly, increased polymorphonuclear (PMN) projections on the segmented neutrophils, and persistence of Hb F.¹ Patients with distal 13q duplications (13q14→qter) typically show other features overlapping those with full trisomy 13.² Some studies suggest that both proximal and distal duplications are needed for full manifestations of Patau syndrome.^{3,4} Thus, a clear phenotype-karyotype correlation has not been established. Possible explanations for this include: (1) partial duplications for 13 are

usually associated with aneuploidies for other chromosomal segments, (2) gene interactions, (3) imprinting effects, (4) interchromosomal effects. Here we report a patient with duplication of 13q32→qter who presented with a mild phenotype not consistent with either full trisomy 13, proximal 13 duplication, or the described features of distal 13 duplication, and we discuss possible explanations.

Case report

The proband (fig 1) was 8 years old when referred because of delay in academic performance and "a cousin with Down syndrome". He was the first child of non-consanguineous white parents delivered at term and weighing 3742 g. The pregnancy was complicated by pre-eclampsia. Early development and milestones were reported by the parents as "normal". At 3 years he was able to recognise the alphabet and read simple words but he could not remember nursery rhymes. After that age he showed behavioural abnormalities such as frustration with changes in routine and not sleeping alone. He was evaluated by a developmental biologist for the language difficulties at 6 years

Departments of
Pediatrics and
Pathology,
Duke University
Medical Center,
Durham,
NC, USA
N Helali
A K Iafolla
S G Kahler
M B Qumsiyeh

Correspondence to:
Dr Qumsiyeh, Cytogenetic
Services, Department of
Pathology,
Box 3712, Duke University
Medical Center, Durham,
NC 27710, USA.

Received 5 February 1995
Revised version accepted for
publication 1 March 1996




Figure 1 Proband at 10 years of age. (Photograph reproduced with parental consent.)

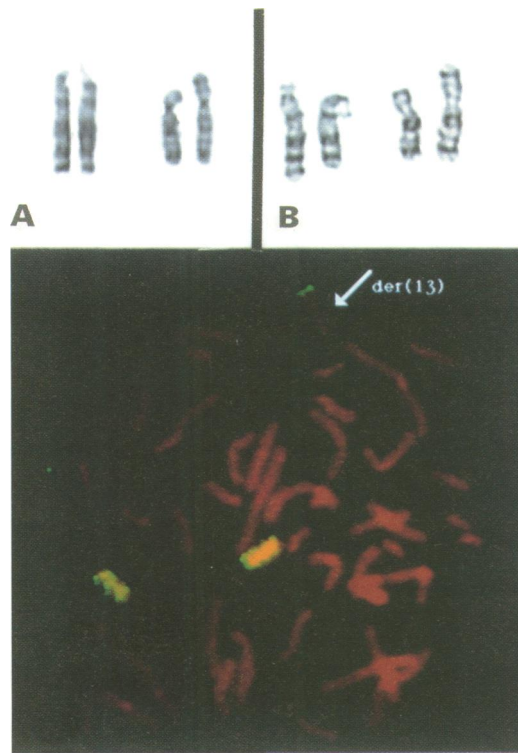


Figure 2 G banded chromosomes 13 and 18 from the proband (A) with extra material on 18p and the father (B) showing $t(13;18)$. (C) FISH using whole chromosome 18 paint probe illustrates the small amount of 18p material found on the derivative 13 in the brother (a balanced translocation carrier.)

terpreted as normal. Physical examination in the genetics clinic showed weight on the 10th centile, height on the 5th centile, and head circumference on the 5th centile. The child was apparently healthy with few phenotypic anomalies: soft fleshy ears, smooth philtrum, slightly downward slanting palpebral fissures, and slightly thin lips. He was initially placed in special education classes but is now mainstreamed and has just completed the sixth grade with grades of As and Bs.

LABORATORY INVESTIGATIONS

Chromosome studies were performed using established protocols and showed an unbalanced karyotype with extra material on chromosome 18 (fig 2A). The mother's karyotype was normal and the father was found to carry a $t(13;18)(q32;p11.32)$ (fig 2B). Thus, the proband's karyotype is designated 46,XY, $der(18)t(13;18)(q32;p11.32)pat$. This patient thus has a duplication of 13q32 to 13qter and deletion of a very tiny segment (the terminal portion) of distal 18p. Fluorescence in situ hybridisation using chromosome 18 painting probe (Oncor Inc, Gaithersburg, MD) confirmed this interpretation (fig 2C). Other family members were not available for study. A study of a blood smear at the age of 10 years showed no evidence of excess PMN projections on the segmented neutrophils.

Discussion

The proband has both a duplication 13q32→qter as well as a very small deletion of the terminal band of 18p11.32. The classic 18p deletion usually includes mental and growth retardation, brachycephaly/holoprosencephaly, blepharophimosis, ptosis, prominent auricles, abnormal teeth, short/broad neck, scoliosis/kyphosis, abnormal genitalia, clinodactyly of the fifth fingers, and hypertonia.⁵ This patient has none of these abnormalities (except slightly fleshy ears, fig 1). Findings in patients with trisomies for 13q14→qter, 13pter,→q22, 13q22→qter, and 13q32→qter (including our patient) are listed in the table. The following

5 months of age and was found to have a hearing deficit. His overall evaluation showed minor psychological problems and major weakness in his gross motor skills with a developmental age of 3 years 11 months.

At the age of 8 years he was diagnosed by a neurologist as having a tethered cord after showing weakness in the lower limbs. Surgical correction resulted in significant improvement. At 12 years it was suggested that he had static encephalopathy. CT scan showed a lacunar lesion at the border of the caudate nucleus and the capsula interna. EEG showed some epileptiform spikes but otherwise was in-

Phenotypes of duplication for various segments of 13q

	<i>Tharapel et al</i> ¹	<i>Tharapel et al</i> ¹	<i>Tharapel et al</i> ¹	<i>Escobar et al</i> ⁶	<i>Kim et al</i> ⁷	<i>Galan et al</i> ⁸	<i>Rivas et al</i> ⁹	<i>Proband</i>
13q trisomy	q14→qter	pter→q22	q32→qter	q22→qter	q22→qter	q22→qter	q22→qter	q32→qter
Other chromosome	Misc	Misc	?	—	dup 22pter→q12	—	del 15q26→qter	del 18pter
Psychomotor retardation	11/11	14/15	1/2	+	+	+	+	+
Mental retardation	11/11	14/15	2/2	+	+	+	+	—
Seizures/EEG abnormality	5/11	2/15	2/2	+	+	+	+	+
Scalp defects	5/11	3/15	?	—	—?	—	—	—
Microcephaly	3/11	8/15	0/2	+	+	+	+	—
Bossed forehead	4/11	6/15	0/2	—	?	+	+	—
Long curled eyelashes	7/11	1/15	—	+	?	+	+	—
Ocular abnormalities	3/11	6/15	1/2	+	+	+	+	—
Abnormal ears	9/11	10/15	2/2	+	+	+	+	Fleshy
Cleft palate	1/11	5/15	0/2	—	+	—	—	—
High arched palate	8/11	3/15	2/2	+	—	+	+	—
Long philtrum/thin upper lips	4/11	2/15	0/2	—	+	+	+	+
Polydactyly	6/11	0/15	2/2	+	—	+	—	—
Hernias	5/11	2/15	1/2	+	—	+	+	—
Urogenital abnormalities	4/11	1/15	1/2	?	+	+	?	—
Heart abnormality	—	—	—	—	+	—	—	—
Haemangiomas	4/11	2/15	2/2	+	+	+	?	—
Raised Hb F	1/11	7/10	0/2	—	?	?	—	—
PMN projections	0/11	8/11	0/2	—	?	?	—	—

observations are of note. (1) Microcephaly, cleft palate, raised fetal haemoglobin, and increased PMN projections are more represented in the proximal duplications 13qter→q22. (2) High arched palate, polydactyly, hernias, haemangiomas, and urogenital abnormalities are more represented in the distal duplications 13q14→qter. These phenotypic features are similar to those of complete trisomy 13 (Patau syndrome).²

Our patient with dup 13q32→qter did not show the features classically seen in patients with duplications of 13q14→qter. A recent patient with what was described as 13q32→qter duplication had many more abnormalities.¹⁰ However, the data (G banding and FISH) presented suggest to us that the duplication in that patient is larger than in ours (perhaps 13q31 or more proximally on 13q32 than ours). How do we explain the data? It is possible that features of trisomy 13 and duplication 13q14→qter are the result of genes that can now be restricted to the segment between 13q14 and 13q32. Another possibility is that gene interaction precludes a direct genotype-phenotype correlation in duplications of distal 13q. This "interactive model" proposes that epistasis/gene interaction modulates gene expression.¹¹⁻¹³ Yet a third possibility is that chromosome rearrangements may destabilise nuclear architecture and thus result in mosaic loss of derivative chromosomes by formation of micronuclei or change in expression of other genes or both.¹⁴ This hypothesis is supported by the presence of excess PMN projections in full and proximal trisomy 13q (with centromeres present) and their absence in distal duplication 13q (table). It must be emphasised that the three hypotheses are not mutually exclusive and a combination of two or three of

these can be possible. We are now investigating nuclear instability associated with various unbalanced and balanced rearrangements including cases with chromosome 13 abnormalities. (More patient samples are sought for these studies and we would appreciate collaborations.)

We thank the parents for their kind cooperation.

- 1 Tharapel SA, Lewandowski RC, Tharapel AT, Wilroy RS. Phenotype-karyotype correlation in patients trisomic for various segments of chromosome 13. *J Med Genet* 1986; 23:310-15.
- 2 Nikolis J, Ivanovic K, Diklic V. Partial trisomy 13q resulting from a paternal reciprocal Yq;13q translocation. *J Med Genet* 1991;28:425-6.
- 3 Riccardi VM, Hittner HM, Francke U, et al. Partial triplication and deletion 13q: study of a family presenting with bilateral retinoblastoma. *Clin Genet* 1979;15:332-45.
- 4 Rogers JF. Clinical delineation of proximal and distal partial 13q trisomy. *Clin Genet* 1984;25:221-9.
- 5 Zumel RM, Darnaude MT, Delicado A, Debustamante AD, Detorres ML, Lopezpajares I. The 18p- syndrome: report of 5 cases. *Ann Genet (Paris)* 1989;32:160-3.
- 6 Escobar JI, Sanchez O, Yunis JJ. Trisomy for the distal segment of chromosome 13: a new syndrome. *Am J Dis Child* 1974;128:217-20.
- 7 Kim HJ, Hsu LYF, Goldsmith LC, Strauss L, Hirschhorn K. Familial translocation with trisomy of 13 and 22: evidence that specific regions of chromosomes 13 and 22 are responsible for the phenotype of each trisomy. *J Med Genet* 1977;14:114-19.
- 8 Galan F, Garcia R, Aguilar MS, Moya M. Partial trisomy 13q22→qter: a new case. *Ann Genet (Paris)* 1989;32:114-16.
- 9 Rivas F, Rivera H, Plascencia ML, Cantu JM. The phenotype in partial 13q trisomies, apropos of a familial (13;15)(q22;q26) translocation. *Hum Genet* 1984;67:86-93.
- 10 Rao VVNG, Carpenter NJ, Guzsavas M, et al. Partial trisomy 13q identified by sequential fluorescence in situ hybridization. *Am J Med Genet* 1995;58:50-3.
- 11 Wilson GN. Karyotype/phenotype controversy: genetic and molecular implications of alternative hypotheses. *Am J Med Genet* 1990;36:500-5.
- 12 Wilson GN, Heller KB, Elterman RD, Schneider NR. Partial trisomy 18 with minimal anomalies: lack of correspondence between phenotypic manifestations and triplicated loci along chromosome 18. *Am J Med Genet* 1990; 36:506-10.
- 13 Lurie IW. Autosomal imbalance syndromes - genetic interactions and the origin of congenital malformations in aneuploidy syndromes. *Am J Med Genet* 1993;47:410-16.
- 14 Qumsiyeh MB. Impact of rearrangements on function and position of chromosomes in the interphase nucleus and on human genetic disorders. *Chromosome Res* 1995;3:455-65.