

## CASE REPORT

# Rift Valley fever and malaria co-infection: A case report

Yousif Ali<sup>1</sup> | Emmanuel Edwar Siddig<sup>2,3</sup>  | Nouh Mohamed<sup>4</sup> | Ayman Ahmed<sup>5,6,7</sup> 

<sup>1</sup>Sudan Field Epidemiology Training, Health Emergencies and Epidemics Control General Directorate, Sudan Federal Ministry of Health, Khartoum, Sudan

<sup>2</sup>Faculty of Medical Laboratory Sciences, University of Khartoum, Khartoum, Sudan

<sup>3</sup>Department of Medical Microbiology and Infectious Diseases, Erasmus University Medical Center Rotterdam, Rotterdam, The Netherlands

<sup>4</sup>Molecular Biology Unit, Sirius Training and Research Centre, Khartoum, Sudan

<sup>5</sup>Swiss Tropical and Public Health Institute (Swiss TPH), Allschwil, Switzerland

<sup>6</sup>Faculty of Science, University of Basel, Basel, Switzerland

<sup>7</sup>Institute of Endemic Diseases, University of Khartoum, Khartoum, Sudan

## Correspondence

Ayman Ahmed, Institute of Endemic Diseases, University of Khartoum, Khartoum, Sudan.  
Email: [ayman.ame.ahmed@gmail.com](mailto:ayman.ame.ahmed@gmail.com)

## Key Clinical Message

We report a case of febrile illness that was presented with mild symptoms. However, laboratory investigation confirmed a malaria and Rift Valley fever co-infection. Healthcare providers in settings endemic with several infectious diseases should seek rolling out possibilities of other infections prior to starting treatment for achieving effective case management with less resources and better safety of patients.

## Abstract

Here we report a case of febrile illness that confirmed to be a co-infection of malaria and Rift Valley fever. The patient was initially diagnosed with malaria and started on treatment immediately. However, due to the lack of response to the treatment further laboratory investigations were pursued.

## KEYWORDS

chronic diseases, critical care medicine, environmental health, infectious diseases, virology

## 1 | BACKGROUND

Rift Valley fever (RVF) is a mosquito-borne zoonotic viral disease that is associated with high morbidity and mortality rates among both human and animals populations in endemic countries.<sup>1</sup> The disease is caused by the Rift Valley fever virus (RVFV) that belongs to genus *Phlebovirus* and family *Phenuiviridae*.<sup>2</sup> The disease was described for the first time in 1931 in the Rift Valley area in Kenya; this how the disease obtained its name

(Ref). The RVFV is transmitted mainly through several species of *Aedes* and *Culex* mosquitoes; however, other modes of transmission including vertical transmission from mother to child, sexual transmission, and through the consumption of raw milk and uncooked meat were documented.<sup>3</sup>

In addition to malaria,<sup>4,5</sup> Sudan is endemic with several arboviruses including RVF, Chikungunya, Crimean–Congo hemorrhagic fever (CCHF), dengue, and West Nile virus.<sup>1,6–11</sup> Infections with the RVFV

This is an open access article under the terms of the [Creative Commons Attribution-NonCommercial](https://creativecommons.org/licenses/by-nc/4.0/) License, which permits use, distribution and reproduction in any medium, provided the original work is properly cited and is not used for commercial purposes.

© 2023 The Authors. *Clinical Case Reports* published by John Wiley & Sons Ltd.

were detected in Sudan in early 1930s.<sup>3,12</sup> Since then, outbreaks of RVF occur frequently in the country.<sup>1,13</sup> The disease is associated with high abortion among human and domestic animals, therefore, in addition to its negative health affects it has devastating socio-economic impacts on animals-dependent communities in endemic countries.<sup>1,13,14</sup> Recently, several outbreaks of emerging infectious diseases including RVF occurred in Sudan.<sup>1,6–11,13–17</sup> Additionally, there is rapidly growing evidence about the emergence and spread of invasive diseases vectors in the region including Sudan.<sup>10,18–21</sup> Studies have suggested that the major risk factors that drive this upsurge in the burden and outbreaks of infectious diseases and rapid spread of invasive diseases vectors include climate change, armed-conflicts and the growing size of population living in humanitarian crisis, globalization, and unplanned urbanization.<sup>1,13,22–27</sup> These risk factors increase the dynamic and the interactions of different populations of human and animals substantially, this in turn magnifies the occurrence of spill over and pathogens sharing events across the different species of diseases-susceptible hosts.<sup>28</sup>

Despite the frequent outbreaks of arboviral diseases in Sudan, still there is a huge gap in the local knowledge about the epidemiology, pathology, and the clinical presentation and outcome of patients, particularly in cases of co-infection.<sup>3,6</sup> This gap mainly because of the limited sharing of information about these diseases of local public health and global health concerns.<sup>29</sup> In this communication, we report a case of a differential diagnosis challenge in areas endemic with several causes of febrile illness. Our case, a young (19-year-old) female from central Sudan was confirmed to be co-infected with RVFV malaria.

## 2 | CASE PRESENTATION

A 19-year-old student female from Kampo five, Kenana, White Nile state (Figure 1), has arrived at the emergency unit of Kenana. She was presented on 23th October 2019; with fever, headache, joint pain, fatigue, and loss of consciousness. The patient is a student resident in kenana district and she reported staying at home for the week before the onset of the symptoms; she reported no contact with sick or apparently ill people or animals. However, she reported being recently exposed to heavy mosquitoes' bites during that time. She complained from fever, severe diffuse throbbing headache, and joint pain specifically in the knee and elbow. These symptoms were also accompanied by progressively fatigue and muscle pain.

On initial examination, she had a normal pulse rate (74/min), respiratory rate (19/min), blood pressure (95/55),

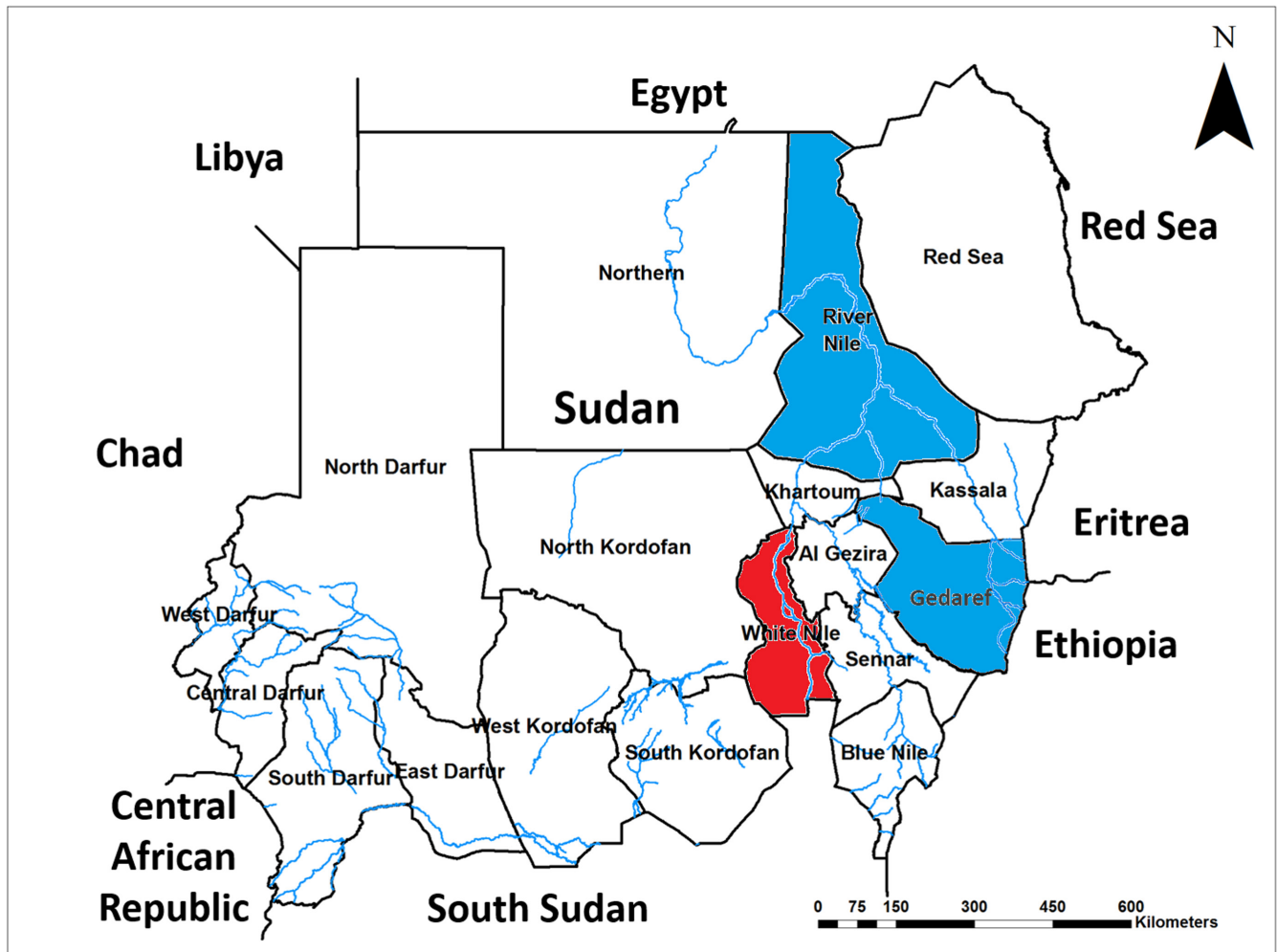
and temperature (39°C). Blood samples were drawn from the patient and sent to the local laboratory.

A blood film was made and was positive for the presence of malaria parasite; blood film showed asexual stage trophozoites of *Plasmodium falciparum* and ICT was also positive. She was started on malaria treatment. However, considering that she did not show clinical response after 3 days on the treatment, and that the country is endemic with several arboviral diseases, which are commonly presented with overlapping or similar symptoms and clinical manifestations.<sup>3</sup> Therefore, another sample of blood was taken on the third day and sent to the reference National Public Health Laboratory (NPHL) in Khartoum to be tested for the major viral infections endemic in the country including dengue, RVF, CCHF, and chikungunya.<sup>3</sup> Nonetheless, considering the recent reports about RVF outbreaks in different states of the country, namely River Nile and Gedaref (Figure 1), and a sudden increase in abortion rate among cattle and sheep was reported in the area, the sample was prioritized for testing RVFV infection. The result of the real time-polymerase chain reaction (RT-PCR) confirmed infection with RVFV.

For the treatment, the patient received paracetamol infusion for the pain. For the malaria infection, the patient received artemether/lumefantrine four tablets (20 mg artemether; 120 mg lumefantrine per tablet) orally (PO) as an initial dose, followed by four tablets PO after 8 h, then four tablets PO twice daily (morning and evening) for 2 days for a total course of 24 tablets. She was advised to stay all day under mosquito net to avoid infecting mosquitoes with RVFV and maintain the virus transmission in the area and she was followed up closely to monitor her case, she responded well and recovered after 3 days. After 2 week follow-up, she showed no signs of sequela or any damage.

## 3 | DISCUSSION

Here we report a case of malaria and RVF co-infection that was presented with mild symptoms without the main clinical characteristics of hemorrhagic fevers including RVF, namely the hemorrhage.<sup>30</sup> This none severe presentation of RVF infection has been observed during a recent outbreak in the northern side of the country (Figure 1).<sup>1</sup> However, during another outbreak of RVF in the south-eastern side of the country during the same year, cases were presented with severe manifestation (Figure 1).<sup>13</sup> This difference in the overall manifestation of several patients could be attributed to the sensitivity of the surveillance system and its capacity to identify and detect none severe cases during the outbreak.<sup>3,29</sup> Therefore, healthcare



**FIGURE 1** Map of Sudan shows the area of the current case study highlighted in red and the states (shaded in blue) where outbreaks of Rift Valley fever were reported during the case presentation.

providers in countries endemic with several causes of febrile illness should pay extra attention during the differential diagnosis and the possibility of co-infection should be high expected in such settings.<sup>3,6,7,31–33</sup> Recently, there is growing evidence about disease emergence and unusual presentation of endemic diseases.<sup>24,33–35</sup> Alternatively, this difference in the clinical manifestation of RVF infection could be attributed to variation in the virus strains of some clades of viruses are more associated with severe clinical presentations of the disease.<sup>36–38</sup> A similar situation has been observed during the currently ongoing Mpox outbreak of global concern.<sup>39</sup> Clade IIb of the Mpox virus that diverged from the West African lineage is associated with globally expanded transmission outside the endemic areas with none severe clinical presentation. While on the contrary, the Democratic Republic of Congo/Central African lineage (clade I) is associated with local transmission in Africa and a higher Case Fatality Rate.<sup>39</sup>

Interestingly, a substantial increase in outbreaks frequency of endemic and emerging infectious diseases has

been observed throughout the country. Several outbreaks of vector-borne diseases including malaria,<sup>17</sup> CCHF,<sup>11</sup> chikungunya,<sup>10</sup> dengue,<sup>31</sup> RVF,<sup>1</sup> leishmaniasis,<sup>16</sup> and other zoonotic emerging infectious diseases such as cholera,<sup>40</sup> COVID-19,<sup>41</sup> and hepatitis E<sup>15</sup> were reported in Sudan. These outbreaks were associated with climate change and sudden forcible displacement of human and animals populations as well as international travel and unplanned urbanization.<sup>25</sup>

Considering the lack of effective treatment and zoonotic nature of arboviral diseases, their prevention and control rely on the implementation of a transdisciplinary One Health strategy<sup>13,42</sup> including the integration of diseases control programs,<sup>43</sup> enhanced surveillance and control of diseases vectors,<sup>18,43,44</sup> improving the water sanitation and hygiene,<sup>45</sup> and the use of vaccines.<sup>40,46</sup> More importantly, stakeholders of health, humanitarian, and development sectors should invest more on long-term and comprehensive solutions including restoring peace and social construction, improving living

conditions, implementing adaptation and mitigation plan for climate change.<sup>25</sup> Such investment will be more rewarding and cost-effective in the long-term and will greatly contribute in achieving the Sustainable Development Goals.

In conclusion, in areas endemic with several infectious diseases like Sudan, co-infection should always be expected and investigated to improve the case management and the clinical outcome. Therefore, investment should be done on training clinical epidemiologists and improving the diagnostic capacity and surveillance system. Additionally, further studies are needed to investigate disease progress and clinical outcome in case of co-infection with two or more infectious diseases.

### AUTHOR CONTRIBUTIONS

**Yousif Ali:** Data curation; investigation; visualization; writing – review and editing. **Emmanuel Edwar Siddig:** Conceptualization; data curation; formal analysis; funding acquisition; investigation; methodology; supervision; validation; visualization; writing – original draft; writing – review and editing. **Nouh Mohamed:** Data curation; formal analysis; investigation; methodology; visualization; writing – original draft; writing – review and editing. **Ayman Ahmed:** Conceptualization; data curation; formal analysis; investigation; methodology; project administration; resources; supervision; validation; visualization; writing – original draft; writing – review and editing.

### ACKNOWLEDGMENTS

None.

### FUNDING INFORMATION

None.

### CONFLICT OF INTEREST STATEMENT

The author reports no conflicts of interest in this work.

### DATA AVAILABILITY STATEMENT

The data that support the findings of this study are available from the corresponding author upon reasonable request.

### CONSENT STATEMENT

Written informed consent was obtained from the patient to publish this report in accordance with the journal's patient consent policy.

### ORCID

Emmanuel Edwar Siddig  <https://orcid.org/0000-0001-6314-7374>

Ayman Ahmed  <https://orcid.org/0000-0002-9516-9508>

### REFERENCES

- Ahmed A, Ali Y, Elduma A, et al. Unique outbreak of Rift Valley fever in Sudan, 2019. *Emerg Infect Dis.* 2020;26(12):3030-3033.
- Gaudreault NN, Indran SV, Balaraman V, Wilson WC, Richt JA. Molecular aspects of Rift Valley fever virus and the emergence of reassortants. *Virus Genes.* 2019;55:1-11.
- Ahmed A, Dietrich I, LaBeaud AD, Lindsay SW, Musa A, Weaver SC. Risks and challenges of arboviral diseases in Sudan: the urgent need for actions. *Viruses.* 2020;12(1):81.
- Ageep TB, Damiens D, Alsharif B, et al. Participation of irradiated anopheles arabiensis males in swarms following field release in Sudan. *Malar J.* 2014;13(1):1-11.
- Elagali A, Ahmed A, Makki N, et al. Spatiotemporal mapping of malaria incidence in Sudan using routine surveillance data. *Sci Rep.* 2022;12(1):1-13.
- Ahmed A, Eldigail M, Elduma A, et al. First report of epidemic dengue fever and malaria co-infections among internally displaced persons in humanitarian camps of North Darfur, Sudan. *Int J Infect Dis.* 2021;108:513-516.
- Ahmed A, Elduma A, Magboul B, Higazi T, Ali Y. The first outbreak of dengue fever in greater Darfur, Western Sudan. *Trop Med Infect Dis.* 2019;4:43.
- Ahmed A, Ali Y, Elmagboul B, et al. Dengue fever in the Darfur area, Western Sudan. *Emerging Infect Dis.* 2019;25:2126.
- Ahmed A, Ali Y, Mohamed NS. Arboviral diseases: the emergence of a major yet ignored public health threat in Africa. *Lancet Planet Health.* 2020;4:e555.
- Ahmed A, Abubakr M, Sami H, Mahdi I, Mohamed NS, Zinsstag J. The first molecular detection of Aedes albopictus in Sudan associates with increased outbreaks of chikungunya and dengue. *Int J Mol Sci.* 2022;23:11802.
- Ahmed A, Ali Y, Salim B, Dietrich I, Zinsstag J. Epidemics of Crimean-Congo hemorrhagic fever (CCHF) in Sudan between 2010 and 2020. *Microorganisms.* 2022;10:928.
- Findlay GJ, Stefanopoulo GM, Mac Callum F. Présence d'anticorps contre la fièvre de la vallée du Rift dans le sang des africains. *Bull Soc Pathol Exot.* 1936;29:986-996.
- Ahmed A, Mahmoud I, Eldigail M, Elhassan RM, Weaver SC. The emergence of Rift Valley fever in Gedaref state urges the need for a cross-border one health strategy and enforcement of the international health regulations. *Pathogens.* 2021;10:885.
- Baudin M, Jumaa AM, Jomma HJ, et al. Association of Rift Valley fever virus infection with miscarriage in Sudanese women: a cross-sectional study. *Lancet Glob Health.* 2016;4(11):e864-e871.
- Ahmed A, Ali Y, Siddig EE, et al. Hepatitis E virus outbreak among Tigray war refugees from Ethiopia, Sudan. *Emerg Infect Dis.* 2022;28:1722-1724.
- Mohamed NS, Osman HA, Muneer MS, et al. Identifying asymptomatic leishmania infections in non-endemic villages in Gedaref state, Sudan. *BMC Res Notes.* 2019;12:566.
- Mohamed NS, Ali Y, Muneer MS, Siddig EE, Sibley CH, Ahmed A. Malaria epidemic in humanitarian crisis settings the case of South Kordofan state, Sudan. *J Infect Dev Ctries.* 2021;15:168-171.
- Hemming-Schroeder E, Ahmed A. Anopheles stephensi in Africa: vector control opportunities for cobreeding an. Stephensi and Aedes arbovirus vectors. *Trends Parasitol.* 2022;39(2):86-90.

19. Abubakr M, Sami H, Mahdi I, et al. The phylodynamic and spread of the invasive Asian malaria vectors, *Anopheles stephensi*, in Sudan. *Biology (Basel)*. 2022;11(3):409.
20. Ahmed A, Pignatelli P, Elaagip A, Hamid MMA, Alrahman OF, Weetman D. Invasive malaria vector *Anopheles stephensi* mosquitoes in Sudan, 2016–2018. *Emerg Infect Dis*. 2021;27(11):2952-2954.
21. Ahmed SK, Elagali A, Ali FF, et al. The Spatial Distribution and Prediction of Habitats Suitability of Some Important Aedes Species (Diptera: Culicidae) Vectors of Arboviruses in Sudan. Available at SSRN: <https://ssrn.com/abstract=4339988> or [10.2139/ssrn.4339988](https://doi.org/10.2139/ssrn.4339988)
22. Ahmed A, Mohamed NS, Siddig EE, Algaily T, Sulaiman S, Ali Y. The impacts of climate change on displaced populations: a call for action. *J Clim Chang Health*. 2021;3:100057.
23. Aljak ER, Eldigail M, Mahmoud I, et al. The first laboratory-confirmed imported infections of SARS-CoV-2 in Sudan. *Trans R Soc Trop Med Hyg*. 2021;115(1):103-109.
24. Ahmed A, Hemaïda MA, Hagelnur AA, Eltigani HF, Siddig EE. Sudden emergence and spread of cutaneous larva migrans in Sudan: A case series calls for urgent actions. *IDCases*. 2023;32:e01789.
25. El-Sadig SM, El-Amin SO, El-Amin RO, Siddig EE, Ahmed A. Humanitarian crisis in Sudan: the collapsed health system threatens the public and global health. *QJM*. 2023;11:hcad085. doi:10.1093/qjmed/hcad085
26. Siddig EE, Eltigani HF, Ali ET, Bongomin F, Ahmed A. Sustaining Hope amid struggle: the plight of cancer patients in Sudan's ongoing war. *J Cancer Policy*. 2023;38:100444. doi:10.1016/j.jcpc.2023.100444
27. Siddig EE, Eltigani HF, Ahmed A. Urgent call to protect children and their health in Sudan. *BMJ*. 2023;382:1799. doi:10.1136/bmj.p1799
28. Carlson CJ, Albery GF, Merow C, et al. Climate change increases cross-species viral transmission risk. *Nature*. 2022;607(7919):555-562.
29. Ahmed A. Urgent call for a global enforcement of the public sharing of health emergencies data: lesson learned from serious arboviral disease epidemics in Sudan. *Int Health*. 2020;12(4):238-240.
30. Kahlon SS, Peters CJ, Leduc J, et al. Severe Rift Valley fever may present with a characteristic clinical syndrome. *Am J Trop Med Hyg*. 2010;82(3):371-375. doi:10.4269/ajtmh.2010.09-0669
31. Elduma AH, LaBeaud AD, A Plante J, Plante KS, Ahmed A. High seroprevalence of dengue virus infection in Sudan: systematic review and meta-analysis. *Trop Med Infect Dis*. 2020;5:120.
32. Rugarabamu S, Rumisha SF, Mwanika GO, et al. Viral haemorrhagic fevers and malaria co-infections among febrile patients seeking health care in Tanzania. *Infect Dis Poverty*. 2022 Apr 25;11(1):33. doi:10.1186/s40249-022-00959-z
33. Ahmed A, El-Sadig SM, Eltigani H, et al. Guillain-Barre syndrome associated with COVID-19 and malaria coinfection: A case report. *Authorea*. 2023. doi:10.22541/au.167767321.12356900/v1
34. Ahmed A, Hagelnur AA, Eltigani HF, Siddig EE. Cutaneous tuberculosis of the foot clinically mimicking mycetoma: A case report. *Clin Case Rep*. 2023;11:e07295. doi:10.1002/ccr3.7295
35. Ahmed A, El-Amin R, Musa AM, et al. Guillain-Barre syndrome associated with COVID-19 infection: A case series. *Clin Case Rep*. 2023;11(2):e6988.
36. Bird BH, Khristova ML, Rollin PE, Ksiazek TG, Nichol ST. Complete genome analysis of 33 ecologically and biologically diverse Rift Valley fever virus strains reveals widespread virus movement and low genetic diversity due to recent common ancestry. *J Virol*. 2007;81(6):2805-2816.
37. Bird BH, Ksiazek TG, Nichol ST, MacLachlan NJ. Rift Valley fever virus. *J Am Vet Med Assoc*. 2009;234(7):883-893.
38. Anywaine Z, Lule SA, Hansen C, Warimwe G, Elliott A. Clinical manifestations of Rift Valley fever in humans: systematic review and meta-analysis. *PLoS Negl Trop Dis*. 2022;16(3):e0010233. doi:10.1371/journal.pntd.0010233
39. Roper RL, Garzino-Demo A, Del Rio C, et al. Monkeypox (Mpox) requires continued surveillance, vaccines, therapeutics and mitigating strategies. *Vaccine*. 2023;41:3171-3177.
40. Mohamed NS, Ali Y, Abdalrahman S, Ahmed A, Siddig EE. The use of cholera oral vaccine for containment of the 2019 disease outbreak in Sudan. *Trans R Soc Trop Med Hyg*. 2022;116(9):763-766.
41. Ahmed A, Mohamed NS, El-Sadig SM, et al. COVID-19 in Sudan. *J Infect Dev Ctries*. 2021;15(2):204-208.
42. Zinsstag J, Hediger K, Osman YM, et al. The promotion and development of one health at swiss TPH and its greater potential. *Diseases*. 2022;10(3):65.
43. Ali Y, Ahmed A, Siddig EE, Mohamed NS. The role of integrated programs in the prevention of COVID-19 in a humanitarian setting. *Trans R Soc Trop Med Hyg*. 2022;116(3):193-196.
44. Ahmed A, Abubakr M, Ali Y, Siddig EE, Mohamed NS. Vector control strategy for *Anopheles stephensi* in Africa. *Lancet Microbe*. 2022;3(6):e403.
45. Ahmed A, Irish SR, Zohdy S, Yoshimizu M, Tadesse FG. Strategies for conducting *Anopheles stephensi* surveys in non-endemic areas. *Acta Trop*. 2022;236:106671.
46. Ahmed A, Yousif A, Mohamed NS, Zinsstag J, Siddig EE, Khairy A. Hepatitis E virus outbreak among Tigray war refugees from Ethiopia, Sudan (response). *Emerg Infect Dis*. 2023;29(2):460-461.

**How to cite this article:** Ali Y, Siddig EE, Mohamed N, Ahmed A. Rift Valley fever and malaria co-infection: A case report. *Clin Case Rep*. 2023;11:e7926. doi:10.1002/ccr3.7926