

Molecular cytogenetic characterisation of the first familial case of partial 9p duplication (p22p24)

B R Haddad, A E Lin, H Wyandt, A Milunsky

Abstract

We report on a father and daughter with a partial 9p duplication, dup(9)(p22p24). Their phenotype, albeit mild, is characteristic of partial trisomy 9p. Fluorescence in situ hybridisation (FISH) was used to characterise further and confirm the G banding finding. This is the first reported instance of trisomy 9p occurring in two successive generations. The duplicated segment in these two patients is among the smallest segments reported. Comparison of our two patients and 144 reported patients with trisomy 9p (partial or complete trisomy) suggests that the 9p22 region may be responsible for the observed phenotype in 9p duplication cases.

(*J Med Genet* 1996;33:1045-1047)

Key words: trisomy 9p; FISH.

Since the first case of trisomy 9p was described in 1970,¹ almost 150 patients with partial or complete 9p trisomy have been reported. In

most of these patients, the trisomic segment was inherited from reciprocal translocation carrier parents, with only a small number occurring as de novo duplications. We describe the first familial instance of partial 9p duplication, dup(9)(p22p24), occurring in two successive generations. Fluorescence in situ hybridisation (FISH) was used to characterise the conventional cytogenetic findings further. This is among the smallest reported duplicated segments resulting in the characteristic partial trisomy 9p phenotype, albeit mild in our two patients, and the only family with a direct duplication in two successive generations. Review of 144 reported trisomy 9p patients, and comparison of our two patients specifically with 11 non-translocation patients, suggests that the 9p22 region may be responsible for the observed phenotype in this syndrome.

Case report

The proband, a 9¼ year old white girl, was the product of an uneventful 39 week gestation and normal vaginal delivery referred for genetic evaluation because of short stature, low normal intelligence (IQ 70-80), and unusual facial appearance. Weight was 25 kg (20th centile), height 120 cm (8th centile), head circumference 49.5 cm (8th centile), and interpupillary distance 5 cm (20th centile). She had a prominent, wide nose with a high nasal bridge, deep set eyes, mild ptosis, mildly downward slanting, small palpebral fissures, short, wide philtrum, narrow mouth with thin upper lip, mild micrognathia, and midfacial flattening (fig 1B). All her fingers appeared short, especially the fifth finger, with striking clinodactyly and a single flexion crease (fig 1D). There was a bridged transverse palmar crease on the left hand. An echocardiogram showed mitral valve prolapse with mild mitral regurgitation. She had early onset significant developmental delay, but currently participates in a regular class, needing assistance for impulsivity and short attention span.

The proband's 44 year old father has always lived independently, but considers himself slow. He has a history of learning disability and poor school performance, but without documented IQ score. He was a short, obese, middle aged white man who resembled his daughter. Height was 162 cm (less than the 5th centile), weight 101 kg (greater than the 95th centile), and head circumference 56 cm (50th centile). He had a short, wide neck without frank webbing, slightly downward slanting palpebral fissures, large,

Boston University School of Medicine, Center for Human Genetics, 700 Albany Street, Boston, Massachusetts 02118, USA

B R Haddad
H Wyandt
A Milunsky

National Birth Defects Center, 40 Second Street, Waltham, Massachusetts 02154, USA
A E Lin

Correspondence to: Dr Haddad, Institute for Molecular and Human Genetics, Georgetown University Medical Center, 3800 Reservoir Road, 4th Floor Main, Washington, DC, USA.

Received 15 May 1996
Revised version accepted for publication 9 July 1996

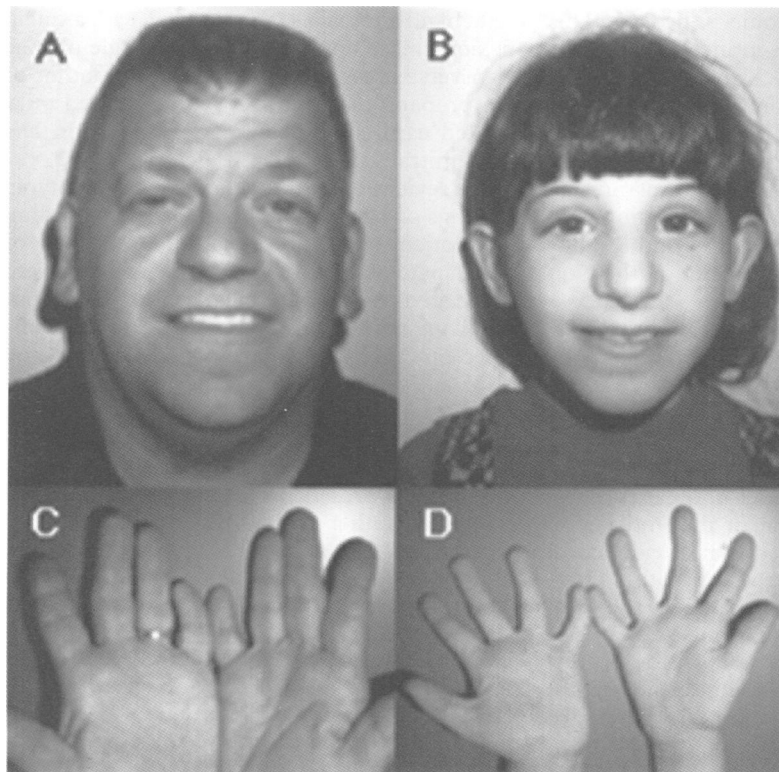


Figure 1 (A) The proband's father. (B) The proband. (C) Father's hand. (D) Proband's hand.

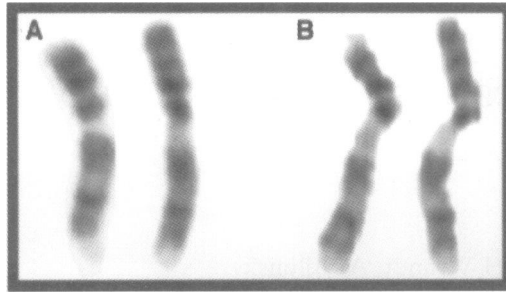


Figure 2 GTG banded partial karyotype of the proband (A) and her father (B) showing the two chromosomes 9. Left, normal 9; right, duplicated 9.

low set ears, a prominent nose with a high nasal bridge, a short, flat philtrum, downturned, thin lips, and a raspy voice (fig 1A). Before cytogenetic examination, the initial gestalt was reminiscent of Noonan syndrome. Like his daughter, he had short fingers and striking fifth finger clinodactyly with a single flexion crease and bilateral bridged transverse palmar creases (fig 1C). An echocardiogram showed a mild non-ischaemic dilated cardiomyopathy.

The family history is remarkable for the dead paternal grandfather having similar clinodactyly, obesity, and "slow" performance. He did not have short stature and died at the age of 61 years from coronary artery disease. The 45 year old paternal uncle and 68 year old paternal grandmother were reported as normal, but both refused examination or karyotype analysis.

CYTOGENETIC ANALYSIS

G banding of chromosomes derived from the patient's lymphocyte culture showed a 46,XX karyotype with an extra dark band present on the short arm of chromosome 9 (fig 2A). This was interpreted as representing either a duplication of distal 9p (46,XX,dup(9)(p22p24)) or some other chromosomal rearrangement, for example, a translocation or insertion. The paternal karyotype showed the same 9p finding (fig 2B). The mother's karyotype was normal (46,XX). The extra band was C banding negative in both the proband and her father, thus eliminating pericentric inversion of the 9qh region.

Fluorescence in situ hybridisation (FISH) studies using a chromosome 9 painting probe (Oncor) were performed on lymphocyte metaphase spreads prepared from both the proband and her father. In both patients, there was uniform hybridisation along both chromosomes 9 including the area of the extra band on 9p, with the exception of the 9qh region and centromeres. There was no evidence of hybridisation of the probe on any other chromosome. These findings excluded the possibility of an insertion or translocation and suggested a direct duplication as the correct interpretation of the G banding results (fig 3).

Discussion

Partial trisomy 9p is a relatively common and well described syndrome. The largest review

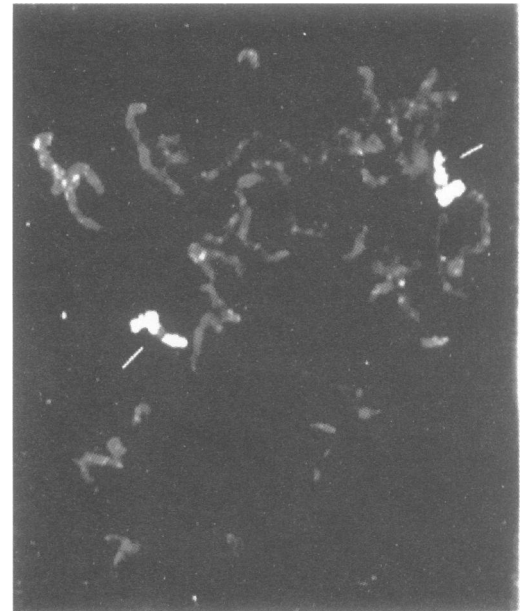


Figure 3 FISH studies using a painting probe for the entire chromosome 9 on lymphocyte metaphase spreads prepared from the proband. Note the uniform hybridisation on both chromosomes 9 (bars) with the exception of the centromeric and qh region. Also note the absence of a hybridisation signal on any other chromosome.

by Young *et al*² analysed 128 patients who had trisomic segments of variable length, extending to 9q in some instances.

The father and daughter in our family display several typical features of partial trisomy 9p syndrome, that is, mental limitation (in their case, IQ at lower limit of normal), short stature, characteristic facial appearance (downturned mouth, bulbous nose, short philtrum, apparent hypertelorism, short, wide neck, low set ears, downward slanting palpebral fissures), and mild hand anomalies (short fingers with a single flexion crease on the fifth finger, single palmar transverse crease).^{3,4} In addition, the father of the proband has a previously unreported mild dilated cardiomyopathy and the proband has mild mitral valve prolapse.

We reviewed the cytogenetic and phenotypic findings of 144 reported patients,⁵⁻¹⁶ including one patient with mosaicism.¹⁵ The majority of these patients with partial trisomy 9p were associated with an unbalanced translocation involving another chromosome. Thus we confined our analysis to our two patients and nine published cases in which partial trisomy 9p involved a direct duplication (table 1). Among these 11 patients, there was remarkable consistency in the facial and digital anomalies which were present in all patients and varied in degree rather than type. A general trend towards milder overall phenotype with smaller and more distal duplications was noted. In an earlier report, a similar comparison of patients with a broader range of trisomic segments increasing from 9pter to q32 showed an increase in the number of skeletal and visceral malformations and growth retardation.

Our patients carry one of the smallest duplicated 9p segments (p22p24) and display most of the typical features of the trisomy 9p syndrome. The moderate-severely retarded

Table 1 Phenotypic manifestations and chromosome breakpoints in 11 patients with partial trisomy 9p involving a direct duplication, arranged by breakpoints proximal to distal

Ref	Patient No	Chromosome 9 trisomic region	Mental retardation	Typical face*	Typical hands†	Other
12	4	p12-p22	Severe	+	+	
6	2	p12-p24	Severe	+	+	
8	1	p12-p24	Unknown (3 months)	+	+	Bilateral CL/CP
10	1	p12-p24	"Subnormal"	+	+	
16	1	p13-p22	Mod-severe	+	+	
5	1	p13-p24	Severe	+	+	
14	1	p13-p24	Moderate	+	+	
Chiyo <i>et al</i> (1976)	1	p21-p24	Severe	+	+	
Baccichetti (1979)	1	p21-p24	Mild	+	+	
This report	Child	p22-p24	Low normal	+	+	Mitral valve prolapse
	Father	p22-p24	Low normal	+	+	Dilated cardiomyopathy

* Bulbous nose with high nasal bridge, deep set eyes, ptosis, downward slanting palpebral fissures, apparent hypertelorism, short, wide neck, low set ears, short philtrum, downturned mouth.

† Brachymesophalangy, clinodactyly, single flexion creases.

patient reported by Fryns *et al*¹⁶ with dup(9)(p13p22) shows the characteristic trisomy 9p phenotype suggesting that the 9p22 region may be responsible for the observed phenotype in 9p duplication patients. When this critical region is associated with a tiny distal duplication, as in our patients, there is mild mental limitation and short stature, mild facial features, and digital anomalies as described above. Aside from cleft lip and palate in the patient reported by Motegi *et al*,⁸ major skeletal and visceral malformations were not observed (table 1). The significance of mitral valve prolapse in the proband and mild dilated cardiomyopathy in her father is not known.

The importance of the full characterisation of the conventional cytogenetic findings using molecular techniques (FISH) can not be overstated. In our two patients, FISH data were critical for showing the origin of the extra material on 9p and establishing the diagnosis.

In general, an inherited direct duplication of a chromosomal segment occurring in at least two generations is quite rare.¹⁷ Our patients are the first instance of partial trisomy 9p in two generations in which the trisomic segment is a proven direct duplication.

We thank Dr Michael Robbins for referring the proband to us.

- 1 Rethore MO, Larget-Piet L, Abonyi D, *et al*. Sur quartre cas de trisomie pour le bras court du chromosome 9. Individualisation d'une nouvelle entite morbide. *Ann Genet (Paris)* 1970;13:217-32.
- 2 Young RS, Reed T, Hodes ME, Palmer CG. The derma-

- 3 Preus M, Ayme S. Formal analysis of dysmorphism. Objective methods of syndrome delineation. *Clin Genet* 1982; 23:1-16.
- 4 Nichols P. Chromosome 9, trisomy 9p. In: Buyse ML, ed. *Compendium of birth defects*. Oxford: Blackwell, 1991: 355-6.
- 5 Zadeh TM, Funderburk SJ, Carrel R, Dumars KW. 9p duplication confirmed by gene dosage effect: report of two patients. *Ann Genet (Paris)* 1981;24:242-4.
- 6 Cuoco C, Gimelli G, Pasquali F, *et al*. Duplication of the short arm of chromosome 9. Analysis of five cases. *Hum Genet* 1982;61:3-7.
- 7 Wajntal A, Gonzalez CH, Koiffman de Souza DE. Brief cytogenetic report on maternal translocation t(7;9)(p22; p13). Two siblings with duplication 9p and one sibling with the balanced translocation. *Am J Med Genet* 1985; 20:265-9.
- 8 Motegi T, Watanage K, Nakamura N, *et al*. De novo tandem duplication 9p (p12→p24) with normal GALT activity in red cells. *J Med Genet* 1985;22:64-6.
- 9 Wilson GN, Raj A, Baker D. The phenotypic and cytogenetic spectrum of partial trisomy 9. *Am J Med Genet* 1985;20: 277-82.
- 10 Mattina T, Sorge G, Milone G, *et al*. Duplication 9p due to unequal sister chromatid exchange. *J Med Genet* 1987; 24:303-5.
- 11 Smart RD, Viljoen DL, Fraser B. Partial trisomy 9 - further delineation of the phenotype. *Am J Med Genet* 1988;31: 947-51.
- 12 Bussani Mastellone C, Uzielli MLG, Guarducci S, Nathan G. Four cases of trisomy 9p syndrome with particular chromosome rearrangements. *Ann Genet (Paris)* 1991;34: 115-19.
- 13 Rivera J, Figuera LE, Vasquez AI. Translocation/duplication of 9p onto a duplicated 4q. *Genet Couns* 1992;3:201-3.
- 14 Phelan MC, Stevenson RE, Anderson EV. Recombinant chromosome 9 possibly derived from breakage and reunion of sister chromatids within a paracentric inversion loop. *Am J Med Genet* 1993;46:304-8.
- 15 Petty EM, Gibson LH, Breg WR, *et al*. Mosaic dup (9p) diagnosed by fluorescence in situ hybridization (FISH). *Am J Med Genet* 1993;45:770-3.
- 16 Fryns JP, Casaer P, Van den Berghe H. Partial duplication of the short arm of chromosome 9 (p13→p22) in a child with typical 9p trisomy phenotype. *Hum Genet* 1979;46: 231-5.
- 17 Fujimoto A, Lin MS. De novo direct duplication of chromosome segment 22q11.2-q13.1. *Am J Med Genet* 1996; 62:300-1.