

Familial persistent pulmonary hypertension of the newborn resulting from misalignment of the pulmonary vessels (congenital alveolar capillary dysplasia)

Humberto B Vassal, Marion Malone, Andy J Petros, Robin M Winter

Abstract

Misalignment of the pulmonary veins with congenital alveolar capillary dysplasia, although rare, has been reported as a cause of persistent pulmonary hypertension of the newborn. Reported cases have been mainly sporadic. Familial occurrence has been reported in only three instances. We present affected sibs with this condition. In addition to pulmonary abnormalities, urogenital abnormalities, including ureteric and urethral obstruction, seem to be common. Autosomal recessive inheritance is suggested.

(J Med Genet 1998;35:58-60)

Keywords: congenital alveolar capillary dysplasia; misalignment of the pulmonary vessels; persistent pulmonary hypertension of the newborn; autosomal recessive

Persistent pulmonary hypertension of the newborn (PPHN) can be secondary to chronic fetal hypoxia, pulmonary hypoplasia, perinatal asphyxia, meconium aspiration syndrome, congenital heart disease, pneumonia (particularly group B streptococcal pneumonia), septicaemia, and hyaline membrane disease.¹⁻⁴ Maternal ingestion of prostaglandin synthetase inhibitors can also be associated with PPHN.⁵ However, in some infants PPHN seems to be idiopathic and no predisposing factors can be found.³

A condition known as misalignment of pulmonary vessels (MPV) or alveolar capillary dysplasia (ACD) has been reported as a cause of "idiopathic" PPHN. To date, about 19 sporadic cases have been reported.⁵⁻¹² Familial occurrence was reported in only three instances.^{1-3 13 14} This is the fourth familial report, giving support to the suggestion of an autosomal recessive gene in some families with this condition.

Case reports

The affected brother and sister were born to healthy, unrelated, white parents. Two previous sibs, a girl and a boy, are normal. There was no history of other unexpected fetal or neonatal deaths in the family.

CASE 1

This was the third child, a male infant. The pregnancy was complicated by bilateral hydronephrosis with oligohydramnios diagnosed on antenatal scan at 35 weeks of gestation. Delivery was induced at 39 weeks. The Apgar

score was 4 at one minute and 9 at three minutes. He had a poor perfusion and a heart rate of less than 100 at birth. At the age of 2 hours he was cyanosed and tachypnoeic. Echocardiography showed an enlarged right ventricle and pulmonary hypertension; cardiac anatomy was normal.

His respiratory condition deteriorated with recurrent pneumothoraces and increased ventilatory requirement. He had extracorporeal membrane oxygenation (ECMO) for 12 days. The subsequent course was characterised by respiratory and renal deterioration and he died on the 20th day of life.

Necropsy showed a heart with moderate hypertrophy of the right ventricle and a patent ductus arteriosus. The lungs were of appropriate volume and weight for gestational age (the right lung weighed 65.8 g and the left lung 45.6 g). There was severe bilateral hydronephrosis with both megaureters measuring about 8 cm in diameter. The bladder was hypertrophied and its wall was 1 cm thick. Posterior urethral valves were present.

On microscopy, the lungs showed muscular arteries and veins lying in juxtaposition to the bronchi and bronchioles. There was medial hypertrophy of the pulmonary arteries, many of which shared their adventitia with thin walled and widened veins (fig 1). Alveolar septa were thickened with a paucity of capillaries. There was secondary lymphangiectasia. There was no pulmonary hypoplasia. The appearances were of misalignment of pulmonary vessels (congenital alveolar capillary dysplasia).

Sections of the kidneys confirmed the presence of bilateral hydronephrosis and showed tubular and glomerular cysts in the superficial cortex; in the medulla there was an

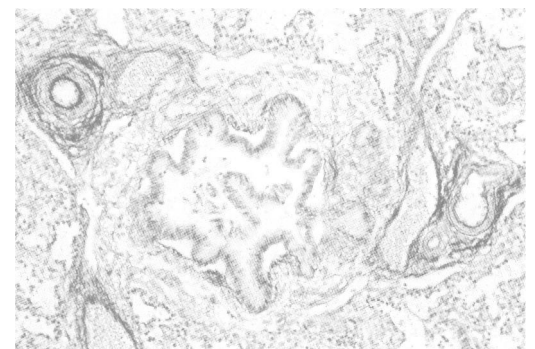


Figure 1 Photomicrograph of a bronchovascular bundle showing close apposition of the pulmonary artery and vein which share an adventitial wall. (Elastic van Gieson stain.)

Mothercare Unit of
Clinical Genetics and
Fetal Medicine,
Institute of Child
Health, 30 Guilford
Street, London WC1N
1EH, UK
H B Vassal
R M Winter

Department of
Histopathology, Great
Ormond Street
Hospital for Children
NHS Trust, London
WC1N 3JH, UK
M Malone

Neonatal Intensive
Care Unit, Great
Ormond Street
Hospital for Children
NHS Trust, London
WC1N 3JH, UK
A J Petros

Correspondence to:
Professor Winter.

Received 5 May 1997
Revised version accepted for
publication 24 July 1997

occasional dilated tubule. Patchy mild chronic inflammation was found in the medulla and pelvis. Apart from some liver and spleen congestion no other abnormalities were detected on histopathology.

CASE 2

This was a term female infant, weighing 3600 g after normal vaginal delivery. She was the fourth child. The pregnancy was uneventful. She was discharged home after six hours, but by 12 hours she had increasing respiratory distress and had a respiratory and cardiac arrest at home. A right sided pneumothorax was drained. Echocardiography showed evidence of persistent pulmonary hypertension with a structurally normal heart.

The striking clinical similarity with her sib was apparent, and after discussion it was decided not to offer ECMO. She died at 21 hours of age, following a further sudden deterioration with a gross pneumoperitoneum and pneumothorax.

Necropsy showed a patent foramen ovale, measuring up to 1 cm in diameter. Lung weight was normal for gestational age (the right lung weighed 40.2 g and the left lung 38.6 g). Microscopy showed similar features to those seen in case 1, without secondary lymphangiectasia. There were no urogenital or other abnormalities.

Discussion

"Congenital alveolar dysplasia", "congenital alveolar capillary dysplasia", "misalignment of lung vessels", or "misalignment of the pulmonary veins with congenital alveolar capillary dysplasia" is characterised histologically by (1) failure of formation and ingrowth of alveolar capillaries that do not make contact with alveolar epithelium, (2) medial muscular thickening of small pulmonary arterioles with (3) extension of muscularisation to the smallest, intra-acinar arterioles, (4) thickened alveolar walls, (5) anomalously situated pulmonary veins running alongside pulmonary arterioles and often sharing a common adventitial sheath, (6) reduced number of alveoli, and (7) dilated lymphatics in some cases.^{1-3 5 7 9}

The infants reported by McMahon in 1948 were probably the first description of this entity.^{5 10} About 19 sporadic cases have been reported.⁵⁻¹² The histological features have been noted to be sometimes variable.^{3 5 10}

All infants have been born at or near term. There is no sex predilection. Other congenital abnormalities have been described in six cases: these included retro-oesophageal left subclavian artery and bicornuate uterus; absent right umbilical artery and stenosis of distal ureters with bilateral hydronephrosis; volvulus of the small bowel, duodenal stenosis, and aganglionosis of the colon; intestinal malrotation and a decreased number of ganglion cells in the distal colon; phocomelia; and Meckel diverticulum.⁵⁻¹² All cases have presented with respiratory distress resulting from pulmonary hypertension in the early postnatal period (at 1 hour to 2 days of life) and all have died within the newborn period.⁵⁻¹²

The first familial report of this condition was by Shohet *et al*¹ in 1984. They described two affected brothers and a sister of healthy, first cousin, Tunisian, Jewish parents. McDonald-McGinn *et al*² and Boggs *et al*³ described affected male and female sibs of apparently unrelated, healthy parents, both of Ukrainian Jewish descent. The male infant also had bilateral ureteropelvic junction obstruction with hydronephrosis and bilateral cryptorchidism. It should be emphasised that there was no pulmonary hypoplasia. Simonton *et al*⁴ reported two affected sibs. The brother had brachial amelia and distal phocomelia of the lower limbs. The sister had phocomelia of the lower extremities. In the latter there was also duplication of the uterus.

Abdallah *et al*⁵ reported a male newborn with PPHN and a sister who presented with pulmonary hypertension just after 5 weeks of age. Both had misalignment of the pulmonary vessels. Manouvrier-Hanu *et al*⁶ reported a similar sibship. One of the sibs presented with pulmonary hypertension from birth (PPHN) and the other one after 15 days of life. They had misalignment of the pulmonary vessels. In both there was associated pelviureteric junction obstruction.

This is the fourth example of concordant sibs with PPHN with MPV/ACD to be reported. As described in other published cases, both sibs developed respiratory distress soon after birth. Clinical, echocardiography, and necropsy data showed pulmonary hypertension. There was no history of predisposing factors. Morphological pulmonary findings were identical to those of the patients reported previously. In the families reported by Manouvrier-Hanu *et al*⁶ and Abdallah *et al*,¹⁵ one sib presented with pulmonary hypertension outside the neonatal period. This suggests that mutations in the same putative autosomal recessive gene could be responsible for some cases of pulmonary hypertension in infancy.

It should be emphasised that in case 1, the histological findings of alveolar capillary dysplasia cannot be put down to his associated posterior urethral valves with oligohydramnios. Pulmonary hypoplasia, with small and poorly developed lungs in relation to the rest of the body, with only subtle histological abnormalities, is a distinct entity and is not compatible with the histological findings in this case.^{5 7}

There are three other reports of renal anomalies. Wagenvoort *et al*⁸ reported a female infant and Boggs *et al*³ reported a male infant, both with bilateral ureteropelvic junction obstruction with hydronephrosis. The two male sibs reported by Manouvrier-Hanu *et al*⁶ also had ureteropelvic junction obstruction. It seems possible that the urogenital anomalies are a pleiotropic manifestation of the same gene.

This family reinforces the suggestion that persistent pulmonary hypertension of the newborn with misalignment of the pulmonary vessels/alveolar capillary dysplasia can be caused by an autosomal recessive gene in some families and can be associated with urinary tract anomalies.

- 1 Shohet I, Reichman B, Schibi G, Brish M. Familial persistent pulmonary hypertension. *Arch Dis Child* 1984;59:783-5.
- 2 McDonald-McGinn DM, Ruchelli E, Uri A, *et al*. Familial persistent pulmonary hypertension of the newborn: a new autosomal recessive disease with histologic findings. *Am J Hum Genet Suppl* 1992;51:A102.
- 3 Boggs S, Harris MC, Hoffman DJ, *et al*. Misalignment of pulmonary veins with alveolar capillary dysplasia: affected siblings and variable phenotypic expression. *J Pediatr* 1994;124:125-8.
- 4 Fox WW, Duara S. Persistent pulmonary hypertension in the neonate: diagnosis and management. *J Pediatr* 1983;103:505-14.
- 5 Janney CG, Askin FB, Kuhn C. Congenital alveolar capillary dysplasia - an unusual cause of respiratory distress in the newborn. *Am J Clin Pathol* 1981;76:722-7.
- 6 Haworth SG, Reid L. Persistent fetal circulation: newly recognized structural features. *J Pediatr* 1976;88:615-20.
- 7 Khorsand J, Tennant R, Gillies C. Congenital alveolar capillary dysplasia: a developmental vascular anomaly causing persistent pulmonary hypertension of the newborn. *Pediatr Pathol* 1985;3:299-306.
- 8 Wagenvoort CA. Misalignment of lung vessels: a syndrome causing persistent pulmonary hypertension. *Hum Pathol* 1986;17:727-30.
- 9 Cater G, Thibeault DW, Beatty EC, Kilbride HW, Huntracoon M. Misalignment of lung vessels and alveolar capillary dysplasia: a cause of persistent pulmonary hypertension. *J Pediatr* 1989;114:293-300.
- 10 Newman B, Yunis E. Primary alveolar capillary dysplasia. *Pediatr Radiol* 1990;21:20-2.
- 11 Langston C. Misalignment of pulmonary veins and alveolar capillary dysplasia. *Pediatr Pathol* 1991;11:163-70.
- 12 Cullinane C, Cox PN, Silver MM. Persistent pulmonary hypertension of the newborn due to alveolar capillary dysplasia. *Pediatr Pathol* 1992;12:499-514.
- 13 McKusick's On-line Mendelian Inheritance in Man (OMIM).
- 14 Simonton S, Chrenka B. Familial persistent pulmonary hypertension in two siblings with phocomelia and alveolar capillary dysplasia (ACD): a new syndrome? *Mod Pathol* 1993;6:9P.
- 15 Abdallah HI, Karmazin N, Marks LA. Late presentation of misalignment of lung vessels with alveolar capillary dysplasia. *Crit Care Med* 1993;21:629-30.
- 16 Manouvrier-Hanu S, Devisme L, Farre I, *et al*. Pulmonary hypertension of the newborn and urogenital anomalies in two male siblings: a new family with misalignment of pulmonary vessels. *Genet Couns* 1996;7:249-55.