

Analysis of a familial three way translocation involving chromosomes 3q, 6q, and 15q by high resolution banding and fluorescent in situ hybridisation (FISH) shows two different unbalanced karyotypes in sibs

Dagmar Wiczorek, Hartmut Engels, Renate Viersbach, Barbara Henke, Gesa Schwanitz, Eberhard Passarge

Abstract

We report on a familial three way translocation involving chromosomes 3, 6, and 15 identified by prometaphase banding and fluorescence in situ hybridisation (FISH). Two mentally retarded sibs with different phenotypic abnormalities, their phenotypically normal sister and mother, and two fetuses of the phenotypically normal sister were analysed. The terminal regions of chromosomes 3q, 6q, and 15q were involved in a reciprocal translocation, in addition to a paracentric inversion of the derivative chromosome 15. Conventional cytogenetic studies with high resolution GTG banding did not resolve this rearrangement. FISH using whole chromosome paints (WCPs) identified the chromosomal regions involved, except the aberrant region of 3q, which was undetectable with these probes. Investigation of this region with the subtelomeric FISH probe D3S1445/D3S1446 showed a balanced karyotype, 46,XX,t(3;15;6)(q29;q26.1;q26), inv der(15)(q15.1q26.1) in two adult females and one fetus. It was unbalanced in two sibs, showing two different types of unbalanced translocation resulting in partial trisomy 3q in combination with partial monosomy 6q in one patient and partial trisomy 15q

with partial monosomy 6q in the other patient and one fetus. These represent apparently new chromosomal phenotypes.

(J Med Genet 1998;35:545-553)

Keywords: three way translocation; partial trisomy 3 (q29→qter); partial trisomy 15 (q26.1→qter); partial monosomy 6 (q26→qter)

Institut für Humangenetik, Universitätsklinikum Essen, Hufelandstrasse 55, 45122 Essen, Germany
 D Wiczorek
 B Henke
 E Passarge

Institut für Humangenetik, Universitätsklinikum Bonn, Wilhelmstrasse 31, 53111 Bonn, Germany
 H Engels
 R Viersbach
 G Schwanitz

Correspondence to: D Wiczorek or H Engels.

Received 23 June 1997
 Revised version accepted for publication 10 December 1997

Complex chromosomal rearrangements (CCRs) involve three or more chromosomes and have at least three breakpoints.^{1,2} CCRs with up to seven chromosomes involved³ and 10 breakpoints⁴ have been described. The interpretation of CCRs or complex translocations by conventional banding techniques alone may be impossible, especially when deletions, insertions, or inversions are present in addition to the reciprocal translocations.⁵

Exact determination of the breakpoints in complex translocations is necessary to estimate the risk of unbalanced offspring and the spectrum of phenotypic abnormalities for genetic counselling. The application of FISH with chromosome specific DNA libraries^{6,7} allows the recognition of aberrant chromosomal regions and cryptic translocations beyond the previous limits of detection.

We report a familial three way reciprocal translocation involving the terminal regions of the long arm of chromosomes 3, 6, and 15. In addition, a paracentric inversion was present in the chromosome 15 involved in the translocation. Three derivative chromosomes and four breakpoints were analysed by GTG prometaphase banding and FISH using whole chromosome paints and a band specific probe (D3S1445/D3S1446) for the smallest translocated segment which was undetectable by the whole chromosome paint.

The proband and her mother are carriers of a balanced three way translocation, whereas her two mentally retarded adult sibs have different unbalanced karyotypes. They represent previously undescribed combinations of chromosomal imbalances, partial monosomy 6q with partial trisomy 3q and partial monosomy 6q with partial trisomy 15q, respectively.

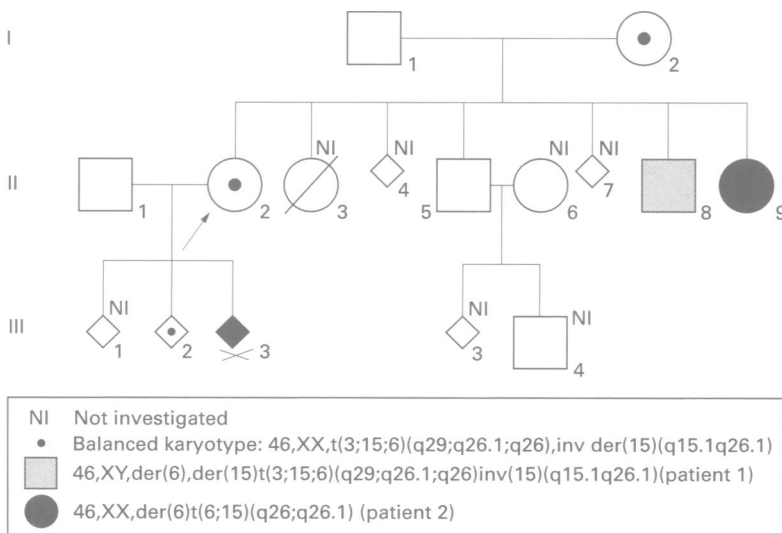


Figure 1 Pedigree of the family.

Table 1 Clinical findings in patients with partial monosomy 6q

	This report (patient 1)	This report (patient 2)	[15], [29]	[13], [14], [17], [18], [19, patient 1], [29, patient 2], [20, patient 2], [21] [30, patient 1], [30, patient 2], [31], [42], [43], [44]	[21], [22], [45]	[14], [20, patient 2], [46], [47]
Monosomy	6q26-qter	6q26-qter	6q26-qter	6q25-qter	6q24-qter	6q23-qter
Trisomy	3q29-qter	15q26.1-qter	1q44-qter ⁹	17q25-qter ¹⁰ 22q11.2-qter ¹⁸	-	-
Sex	M	F	2M	5M/8F	2M/2F	2M/1F
Mental retardation	+	+	2/2	10/10	3/3	1/1
Seizures	-	-	1/2	5/5	4/4	...
Motor coordination disturbed	+	+
Feeding problems	-	-	...	2/2	1/1	...
Muscular hypotonia	+	+	1/2	6/7	1/1	1/1
Short stature	-	-	1/2	5/9	3/3	0/2
Tall stature	+	+	0/2	1/9	0/3	1/2
Microcephaly	-	+	1/2	11/11	4/4	0/2
Brachycephaly	-	-	1/2	5/5	1/1	...
Asymmetrical head/face	-	-	1/2	4/4	...	1/1
Coarse facial features	+	+	1/2	1/10	1/1	...
Hypertelorism	-	-	2/2	5/10	2/2	0/1
Deeply set eyes	+	-	2/2	6/10	2/3	2/2
Narrow palpebral fissures	-	-	1/2	3/11	1/2	1/1
Epicanthic folds	-	-	2/2	9/11	2/2	1/1
Strabismus	+	+	2/2	6/8	1/1	1/1
Ptosis	-	-	1/2	1/9	1/1	0/1
Retinal pigmentary anomaly	1/1	2/2
High nasal bridge	-	-	0/2	4/11	0/2	0/1
Broad nasal bridge	-	-	2/2	10/11	1/1	1/1
Long nasal septum	+	-	0/2	4/10	1/2	0/1
Bulbous tip of nose	-	+	0/2	4/10	1/3	1/1
Choanal atresia	-	-	...	1/1
Long philtrum	-	-	2/2	6/10	3/4	1/1
Flat philtrum	-	-	0/2	3/8	1/3	0/1
Large mouth	+	+	1/2	5/11	1/1	0/1
High palate	+	+	1/1	4/5	2/2	...
Cleft palate	-	-	0/1	4/5	3/3	1/1
Micrognathia	-	-	2/2	11/13	3/3	3/3
Low set ears	-	-	1/2	7/12	4/4	3/3
Dysplastic ears	+	+	2/2	11/11	3/3	2/2
Preauricular pits/tags	-	-	0/2	3/3	1/1	...
Short neck	-	-	2/2	8/8	3/3	2/2
Webbed neck	+	+	0/2	2/2	2/2	2/2
Narrow thorax	-	-	0/2	...	1/2	...
Scoliosis	-	+	1/2	2/2	...	1/1
Situs inversus	-	-	...	1/1
Diaphragmatic hernia	-	-	...	1/1	...	1/1
Congenital heart defect	-	-	1/2	6/10	2/2	2/2
Hydrocephalus	-	-	1/1	3/4	1/1	1/1
Imperforate anus	-	-	1/1	...
Sacral dimple	-	-	...	3/3
Spina bifida	-	-	...	1/1
Genital anomalies	-	-	2/2	4/9	2/3	1/1
Deformity of fingers	-	+	2/2	3/3	2/2	1/1
Tapering fingers	-	-	1/1	...
Brachydactyly	-	-	1/1	...	1/2	2/2
Arachnodactyly	-	+	0/2
Dysplastic nails	-	-	...	1/1	1/1	1/1
Dysplastic hips	-	+	1/2	4/5
Overriding toes	-	-	1/2	1/1	2/2	...

... Not reported. Numbers in square brackets are reference numbers.

Methods

ASCERTAINMENT AND FAMILY HISTORY

The consultand (II.2) asked for genetic counselling during the early gestational weeks of her first pregnancy because of two sibs with mental retardation (II.8 and II.9, fig 1). One younger sister with hydrocephalus (II.3) died at the age of 6 months (further data are not available). One younger brother (II.5) is normal and chromosomal analysis (GTG banding) in an outside laboratory was reported to be normal (fig 1).

In routine chromosomal analysis of the consultand (II.2) using GTG banding at a resolution level of 400 bands per haploid genome, we found a paracentric inversion of chromosome 15 with breakpoints in 15q15 and 15q26. Prometaphase G banding analysis at a resolution of 650 bands showed a translocation involving chromosomes 3, 6, and 15. In order to clarify these findings, the mother (I.2), the two mentally retarded sibs (II.8, II.9), one sponta-

neous abortion (III.2), and the third pregnancy (III.3) of the consultand were studied as described below.

CYTOGENETIC METHODS

Metaphase and prometaphase chromosome preparations were obtained from PHA stimulated lymphocyte cultures from the consultand, her parents, and her mentally retarded sibs using the MTX/bromodeoxyuridine (BrdU) method of Pai and Thomas.⁸ Fibroblast and amniotic cell cultures of her two fetuses were performed using standard methods. Chromosome banding was performed using the trypsin-Giemsa technique of Seabright.⁹

FLUORESCENCE IN SITU HYBRIDISATION

Slides were hybridised with whole chromosome 3 paint (Angewandte Gentechnologie Systeme Heidelberg, Germany) and the probe "telomere 3q" (D3S1445/D3S1446, Oncor-Appligene, Gaithersburgh, VA, USA) according to the manufacturer's instructions.

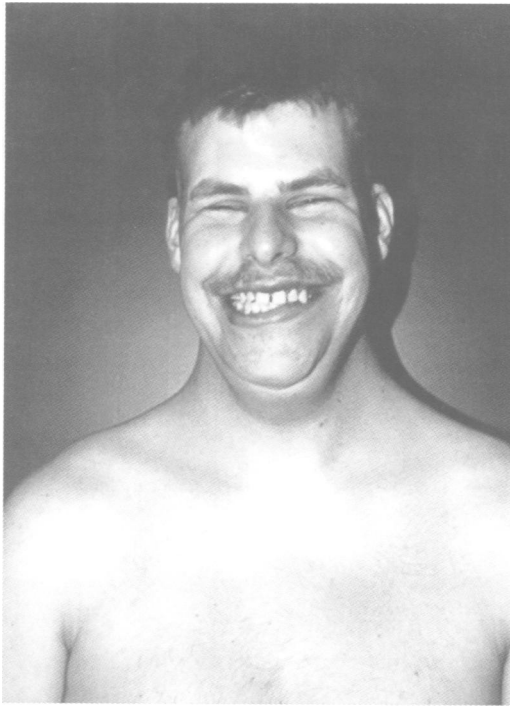


Figure 2 Front view of patient 1 showing long and narrow face with prominent chin, small eyes, hypoplastic nasal alae, large mouth with prominent lips, widely spaced teeth, and broad neck. (Photographs reproduced with permission.)

Simultaneous hybridisation and detection of whole chromosome 6 paint (personal gift from J W Gray)¹⁰ and whole chromosome 15 paint (Angewandte Gentechnologie Systeme Heidelberg, Germany) were performed as follows. The whole chromosome 6 paint was labelled with digoxigenin in a nick translation reaction using 10 × DIG DNA Labelling Mixture (Boehringer Mannheim, Germany) and DNA polymerase 1/DNAseI mixture (Gibco Life Technologies) according to the manufacturer's instructions, mixed with 2 µg cot1-DNA and 10 µg salmon sperm DNA, and precipitated. The probe was dissolved in 10 µl 50% deionised formamide/1 × SSC/10% dextran sulphate, mixed with 10 µl whole

chromosome 15 paint (Angewandte Gentechnologie Systeme), and denatured at 75°C for five minutes. Preannealing was performed at 37°C for 20 minutes. Slide denaturation, hybridisation, and high stringency washes were performed according to the manufacturer's instructions. Signals were detected and enhanced simultaneously by consecutive 30-45 minute incubations with fluorescein-avidin (Vector)/mouse anti-digoxigenin (Sigma), biotinylated goat anti-avidin-IgG (Vector)/rabbit anti-mouse IgG-TRITC (Sigma), and fluorescein-avidin (Vector)/goat-anti-rabbit IgG-TRITC (Sigma).

Chromosomes were counterstained with DAPI, documented, and analysed with an Applied Imaging Cytovision 3.1 system equipped with a CCD camera mounted on a Leitz Diaplan epifluorescence microscope.

Results

CLINICAL DATA

Patient 1 (II.8) is a 26 year old male with severe mental retardation and a distinct dysmorphic phenotype (fig 2, table 1). His height is 192 cm (+2.1 SD), weight 95.5 kg, and head circumference 56.5 cm (normal). He has a long and narrow face with a prominent chin, deeply set eyes of normal distance apart, strabismus, and a broad neck. His nose is prominent with hypoplastic nasal alae. His mouth is large, lips prominent, and teeth widely spaced and normal in number. The palate is normal. The ears are normally set, but small and dysplastic (fig 2). The distal phalanx of the right thumb is broader and shorter than the left. This difference in thumb size was also present in his mother and his mentally retarded sister. When excited, he develops torsion dystonia of his upper extremities. Cranial CT scan showed no anomalies.

This patient was born at term after an uneventful pregnancy with a birth weight of 4500 g (+2.3 SD) and a length of 54 cm (+0.1 SD). Head circumference at birth is not known. He was able to walk without help at the age of 18 months and began to speak at the age of 24 months. His further development was retarded. Childhood photographs show coarse facial features with deep set eyes. The similarity to his sister's face at that time is remarkable. He attended kindergarten and a school for mentally retarded children before he began to work in an institution for handicapped people. He can write by copying, but cannot write his own text or calculate. His speech development is surprisingly good and exceeds his general intelligence. IQ tests were not done. His motor control does not allow him to ride a bicycle. He lives in a secure institution for the mentally retarded because he has been convicted of sexual assault of children.

Patient 2 (II.9) is a 25 year old female with mental retardation and a distinct, very slender ("marfanoid") phenotype that differs from her brother (table 1). Her height is 190 cm (+3.9 SD), weight 55 kg, and head circumference 53 cm (-1.4 SD). She cannot speak whole sentences, but single words only with a hoarse voice. Her face is long and narrow with a

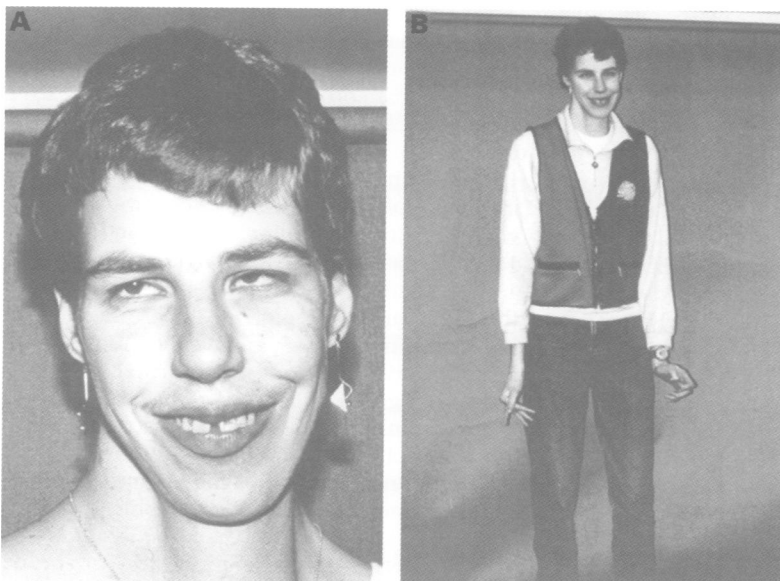


Figure 3 (A) Front view of the face of patient 2 showing narrow face with small eyes, strabismus, large mouth with prominent lips, and widely spaced teeth. (B) Patient 2 showing thin build, broad neck, and torsion dystonia of the hands.

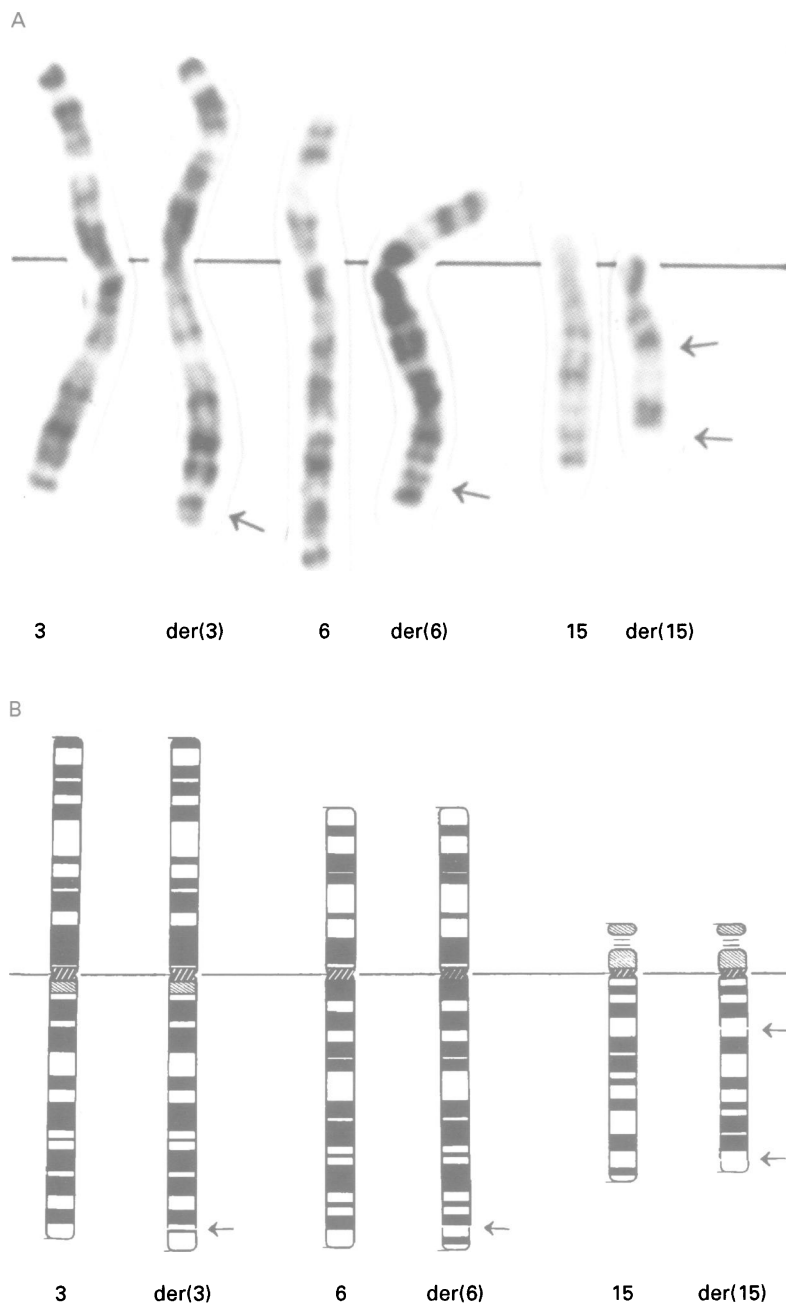


Figure 4 (A) GTG banded karyotype of the proband showing normal chromosomes 3, 6, and 15 on the left, and the derivative chromosomes on the right, respectively. (B) Ideograms of the chromosomes: *der(3): 3pter-3q29::6q26-qter*, *der(6): 6pter-6q26::15q26.1-qter*, and *der(15): 15pter-15q15.1::15q26.1-15q15.1::3q29-3qter*.

prominent chin similar to her brother, deeply set eyes, and strabismus. Her mouth is wide with prominent lips, widely spaced teeth (fig 3A), and a high palate with normal vaulting. Her ears are small and normally set and her neck is broad. She has long, slender, dystrophic extremities. Marked arachnodactyly with a bilateral hand length of 20 cm (+2 SD) is present and her thumbs differ in width and length like her brother's and mother's. She has marked thoracolumbar scoliosis and torsion dystonia of all extremities, especially of her arms and hands (fig 3B). Striae distensae are present on both thighs.

Patient 2 was born at term after an uneventful pregnancy with a birth weight of 5000 g (+4.7 SD) and a length of 59 cm (+3.5 SD). Head circumference at birth is not known. Because of hip dysplasia she was treated with




Figure 5 GTG banded karyotype of patient 1 with partial trisomy 3q, partial monosomy 6q, and an inversion 15. The two normal chromosomes 3 and normal chromosomes 6 and 15 are shown on the left, and the derivative chromosomes on the right.

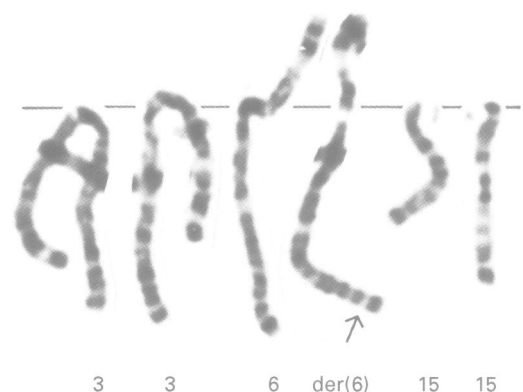


Figure 6 GTG banded karyotype of patient 2 with partial monosomy 6q and partial trisomy 15q. The normal chromosome 6 is shown on the left, the derivative on the right.

an abduction device. She could walk alone at the age of 3 years. Speech development was severely delayed. IQ tests were not performed. She went to a school and an institution for mentally retarded children. She lives with her parents.

CYTOGENETIC DATA

Prometaphase analysis

The consultand (II.2) and her mother (I.2) had an abnormal GTG banding pattern in the terminal regions of the long arm of three chromosomes, 3, 6, and 15, interpreted after FISH analysis as a three way balanced translocation of 3 to 15 to 6, involving breakpoints 3q29, 15q26.1, and 6q26. In addition, a paracentric inversion of the rearranged chromosome 15 with presumed breakpoints in 15q15.1 and 15q26.1 was present (fig 4). In contrast, patient 1 (II.8) had an abnormal banding pattern in the subtelomeric region of a chromosome 6 and a chromosome 15, an inversion in the same chromosome 15, and two normal chromosomes 3 (fig 5). Patient 2 (II.9) had two normal chromosomes 3 and 15 and no inversion 15. However, chromosome 6 had abnormal bands in the telomeric region of the long arm (fig 6). No permanent cell lines are available.

FLUORESCENT IN SITU HYBRIDISATION

Consultand (II.2)

Using whole chromosome 3 paint (WCP3), the aberrant chromosome 3 showed positive

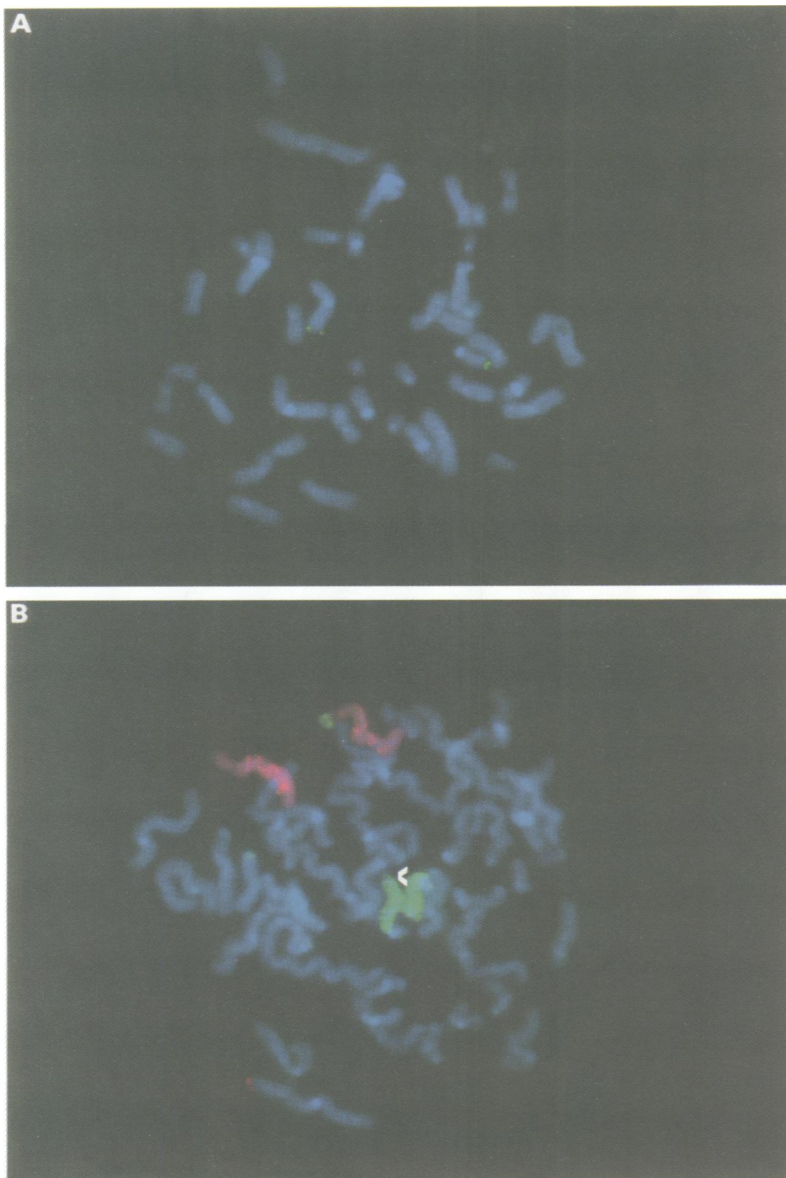


Figure 7 FISH results of the consultand. (A) D3S1445/D3S1446: one chromosome 3 and one chromosome 15 show clear hybridisation signals in their long arm terminal regions. (B) Whole chromosome 6 paint (red/TRITC) and whole chromosome 15 paint (green/FITC): with WCP6 (red) one chromosome 6 is painted entirely while the second one lacks hybridisation signals in its long arm terminal region. An additional signal is visible in the terminal region of one chromosome 3q. Using WCP15 (green), one chromosome 15 is painted brightly while the second one shows fainter hybridisation signals in its long arm terminal region (arrowhead). An additional signal is visible in the terminal region of one chromosome 6q. Cross hybridisation can be seen in the short arm regions of acrocentric chromosomes.

hybridisation signals along its entire length except for a diminished signal intensity over the telomeric region of the long arm. No additional signals were detected (data not shown). The subtelomeric FISH probe telomere 3q (D3S1445, D3S1446) yielded distinct hybridisation signals in the telomeric regions of the normal chromosome 3 and one chromosome 15 (fig 7A). Whole chromosome 6 paint (WCP6) gave positive hybridisation signals along the entire euchromatic length of the aberrant chromosome 6 except for the distal part of the long arm (fig 7B). Additional signals were detected over the terminal region of one chromosome 3. Whole chromosome 15 paint (WCP15) showed fainter hybridisation signals in the terminal portion of the long arm of the aberrant chromosome 15 than in the proximal

region of the long arm, which was painted normally. An additional signal was present in the terminal long arm region of the aberrant chromosome 6 (fig 7B).

Based on these findings we determined the karyotype to be 46,XX,t(3;15;6)(q29;q26.1;q26) inv der(15)(q15.1q26.1).ish t(3;15;6)(wcp3+, wcp6+, D3S1445/D3S1446-; wcp15+, D3S1445/D3S1446+; wcp6+, wcp15+).¹¹

Analysis of fibroblast cultures from the second fetus (III.2) showed a balanced karyotype as in the mother, the consultand (II.2), by all three WCPs and the probe "telomere 3q". Owing to limited quality of banding (320 band stage) and signal production, this conclusion is not entirely certain. Maternal origin of these fibroblast cultures was excluded by Q polymorphism analysis using quinacrine/actinomycin D staining¹² based on the existence of double satellites of chromosomes 15 and 22 in the fetus, which were clearly absent in the mother.

Analysis of amniotic cell cultures of the third pregnancy (III.3) of the consultand showed the same karyotype as in patient 2 with partial trisomy 15q and partial monosomy 6q, as mentioned below. Because the consultand's family moved to Cambridge, UK, the amniocentesis was performed there. The analysis from amniotic cells was done in parallel at Addenbrooke's Hospital, Cambridge (Drs A J Green and L Willatt) and in our laboratory with identical results. Based on these findings the third pregnancy was terminated.

Consultand's mother (I.2)

The karyotype of the mother (I.2) was identical to that of her daughter.

Patient 1 (II.8)

After hybridisation with WCP3, both chromosomes 3 were painted entirely, without additional signals present (data not shown). Using telomere 3q (D3S1445, D3S1446), both chromosomes 3 and one chromosome 15 showed positive hybridisation signals in the telomeric region of the long arm (fig 8A). After hybridisation with WCP6, one chromosome 6 did not show hybridisation signals in the terminal region of the long arm, whereas the rest of chromosome 6 was painted normally (fig 8B). No other signals were detected. With WCP15 the findings were identical to the mother (I.2) and the consultand (II.2) (fig 8B).

According to FISH analysis the karyotype of II.8 is 46,XY,der(6),der(15)t(3;15;6)(q29;q26.1;q26) inv(15)(q15.1q26.1).ish t(3;15;6)(wcp3+, D3S1445/D3S1446+, wcp6-; wcp15+, D3S1445/D3S1446+; wcp6+,wcp15+) giving rise to partial trisomy of chromosome 3q29 to 3qter and partial monosomy 6q26 to 6qter, as shown in fig 5.

Patient 2 (II.9)

After hybridisation with WCP3, both chromosomes 3 were painted entirely (data not shown). No additional signals were found. Using the FISH probe telomere 3q (D3S1445, D3S1446), both chromosomes 3 showed signals (fig 9A).

Table 2 Clinical findings in patients with partial trisomy 15q

	This report (patient 2)	[27], [48]	[23, patient 1], [23, patient 2], [49]	[24, patient 2], [50]	[24, patient 1], [25, patient 1], [25, patient 2], [28, patient 1,2,4,5], [51], [52, patient 1], [53], [54, patient 1],
Trisomy	15q26.1-qter	15q26-qter	15q25-qter	15q23-qter	15q22-qter
Monosomy	6q26-qter	2q37-qter ²⁷ 4p16-pter ⁴⁸	12p13-pter ⁴⁹	6q27-qter ²⁴ 7p22-pter ⁵⁰	21q22-qter ^{24,51} , 8p23.3-pter ²⁵ 11q25-qter ²⁸ , 13q32.3-qter ²⁸ 10q26-qter ⁵⁰ , 12q24.33-qter ⁵³ 14q32-qter ⁵⁴
Sex	F	2M	3M	6M/4F	6M/6F
Mental retardation	+	2/2	3/3	9/9	9/9
Seizures	-	1/1	...	3/8	4/7
Motor coordination disturbed	+
Feeding problems	-	1/1	...	1/1	1/1
Muscular hypotonia	+	1/2	2/3	5/7	5/6
Short stature	-	0/1	...	6/8	4/7
Tall stature	+	0/1	2/2	0/8	2/9
Microcephaly	+	0/1	...	6/9	6/10
Brachycephaly	-	0/1	0/2	...	3/6
Asymmetrical head/face	-	0/1	2/2	8/8	4/10
Coarse facial features	+	0/1	0/1	7/9	1/3
Hypertelorism	-	0/1	0/1	1/1	0/4
Deeply set eyes	-	1/1	0/1	1/1	1/3
Narrow palpebral fissures	-	0/1	0/1	4/10	6/9
Epicanthic folds	-	0/1	0/1	1/1	4/5
Strabismus	+	...	1/1	1/1	3/4
Ptosis	-	...	0/1	5/9	3/4
Retinal pigmentary anomaly
High nasal bridge	-	0/1	0/1	0/1	3/5
Broad nasal bridge	-	0/1	0/1	8/9	7/9
Long nasal septum	-	1/1	0/1	1/1	1/3
Bulbous tip of nose	+	1/2	0/1	0/1	3/5
Choanal atresia	-
Long philtrum	-	0/1	3/3	6/9	9/9
Flat philtrum	-	0/1	1/1	0/9	0/6
Large mouth	+	1/2	0/1	0/1	2/4
High palate	+	1/1	3/3	8/8	4/4
Cleft palate	-	0/1
Micrognathia	-	1/2	3/3	4/7	9/9
Low set ears	-	0/1	3/3	1/1	6/8
Dysplastic ears	+	2/2	1/1	1/1	7/7
Preauricular pits/tags	-	2/6	1/5
Short neck	-	1/2	2/2	6/10	3/8
Webbed neck	+	0/1	...	0/1	3/5
Narrow thorax	-	0/1	...	0/1	...
Scoliosis	+	1/1	...	8/8	2/2
Situs inversus	-
Diaphragmatic hernia	-	0/1
Congenital heart defect	-	0/1	1/1	5/9	7/9
Hydrocephalus	-	...	3/3	...	1/1
Imperforate anus	-	1/4
Sacral dimple	-
Spina bifida	-
Genital anomalies	-	1/1	...	7/7	3/5
Deformity of fingers	+	1/1	2/2	1/1	8/9
Tapering fingers	-	...	2/2	...	2/2
Brachydactyly	-	0/1	0/1	1/1	1/2
Arachnodactyly	+	1/1	1/1	0/1	4/4
Dysplastic nails	-
Dysplastic hips	+
Overriding toes	-

With WCP6 the aberrant chromosome 6 did not show hybridisation signals in the terminal region of its long arm, whereas the rest of this chromosome was painted (fig 9B). No other signals were detected. Using WCP15, both chromosomes 15 were painted entirely and an additional hybridisation signal was detected in the terminal region of one chromosome 6 (fig 9B). These results are consistent with monosomy 6q26 to qter and trisomy 15q26.1 to qter (46,XX,der(6)t(6;15)(q26; q26.1).ish t(3;15;6)(wcp3+,D3S1445/D3S1446+, wcp6-, wcp15+,D3S1445/D3S1446-, wcp6+,wcp15+), as shown in fig 6.

Discussion

In a sequential approach using cytogenetic techniques with increasing power of resolution and chromosomal specificity, we recognised a familial complex translocation involving three chromosomes with breakpoints in 3q29, 6q26, and 15q26.1 and a paracentric inversion

15q15.1-26.1. This allowed the identification of two different unbalanced karyotypes in two adult sibs with distinct phenotypes. Patient 1 (partial monosomy 6q/partial trisomy 3q) had profound mental retardation, tall stature, strabismus, macrostomia, and webbed neck in addition to other features (table 1). Patient 2 (partial monosomy 6q/partial trisomy 15q) had microcephaly, scoliosis, arachnodactyly, and dysplastic hips among others features (tables 1 and 2).

Owing to the complex chromosomal imbalances present in both patients, it is difficult to relate particular signs to specific chromosomal regions, for example, monosomy 6q26-qter and trisomy 15q26.1-qter. Both patients are as severely retarded as all other patients with monosomy 6q (listed in table 1) and all patients with partial trisomy 15q (listed in table 2).

The tall stature in both patients is noteworthy. This may have been influenced by the general height in this family, both the consultant

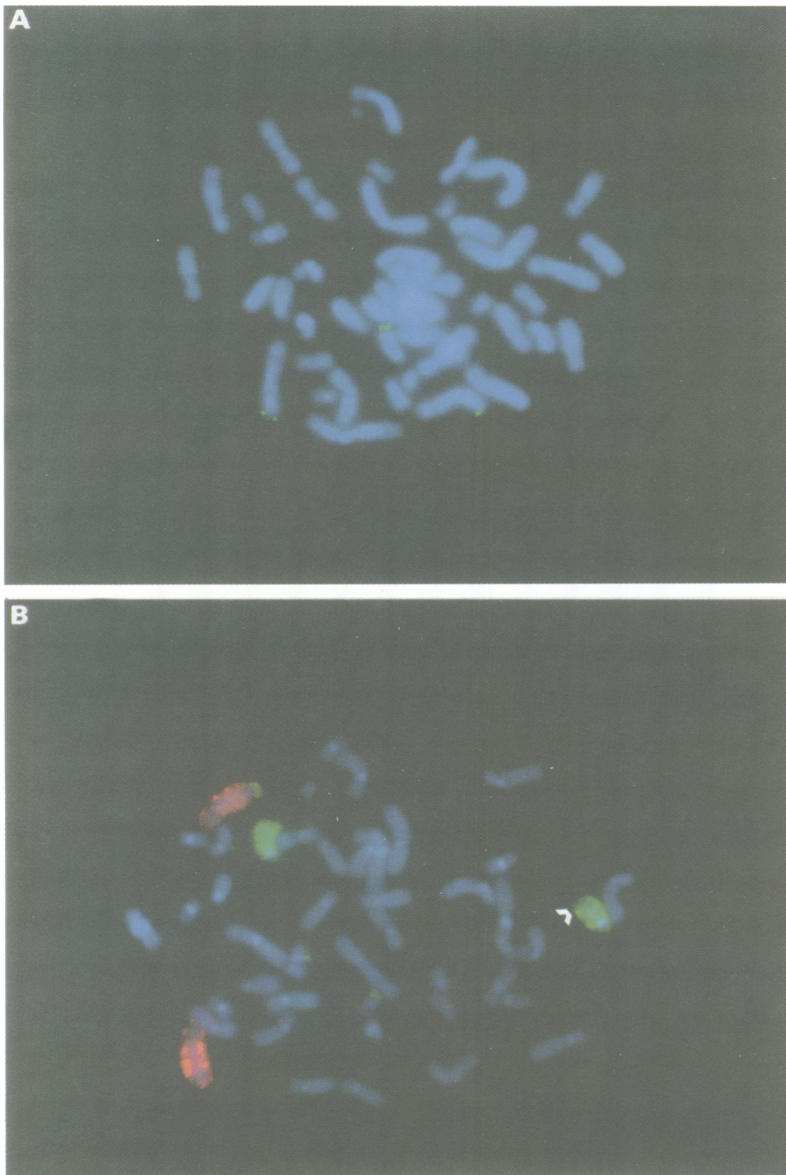


Figure 8 FISH results of patient 1. (A) D3S1445/D3S1446: both chromosomes 3 as well as one chromosome 15 show clear hybridisation signals in their long arm terminal regions. (B) Whole chromosome 6 paint (red/TRITC) and whole chromosome 15 paint (green/FITC): WCP6 (red) shows lack of hybridisation signals in the long arm terminal region of one chromosome 6, whereas the second one is painted entirely. No additional signals are visible in 3qter. WCP15 (green) gives the same hybridisation result as in the consultant.

and her mother being 180 cm tall. Neither of the carriers of the balanced translocations showed any dysmorphic signs. Reviewing published cases with partial monosomy 6q, two other patients also had tall stature,^{13,14} whereas nine patients had short stature.¹⁵⁻²² Tall stature has also been described in four patients with partial trisomy 15q.²³⁻²⁵ Therefore, height may be an inconsistent feature of both monosomy 6q and trisomy 15q, and does not help in distinguishing these chromosomal aberrations. Tallness is also a feature of a further 33 chromosomal aberrations described in the Cytogenetic Database,²⁶ not including partial trisomy 3q. In addition, patient 2 had a marfanoid habitus. A connection to the fibrillin gene mapped to 15q21.1 can be ruled out since neither the translocation nor the inversion breakpoints are near this chromosomal region.

Strabismus was also noted in both patients. This is a very common clinical feature of both

monosomy 6q (12/14 patients) and trisomy 15q (6/7 patients).

Macrostomia, another feature of both patients, cannot be used to distinguish partial monosomy 6q from partial trisomy 15q, because it is present in both chromosomal aberrations with similar frequencies (9/17 in monosomy 6q and 4/9 in trisomy 15q). Both patients had a broad and webbed neck, which has been reported in monosomy 6q (8/10 patients) and in trisomy 15q (4/8 patients).

Clinical anomalies present only in patient 2 are microcephaly, scoliosis, arachnodactyly, and dysplastic hips. Microcephaly and scoliosis are common features of many chromosomal aberrations, and also of monosomy 6q and trisomy 15q (tables 1 and 2). In contrast, arachnodactyly has not been reported in patients with monosomy 6q, but in patients with trisomy 15q.^{23,27,28} Thus, the arachnodactyly is more likely to be related to the partial trisomy 15q than to monosomy 6q in patient 2. In contrast, dysplastic hips have been described only in patients with partial monosomy 6q.^{16,19,29-31} This clinical feature in patient 2 may therefore result from monosomy 6q.

We found no report of patients with partial trisomy 3q29-qter who could be compared to patient 1. All other aberrations of the long arm of chromosome 3 have breakpoints far more proximal than we have observed in patient 1. Clinical findings in patients with dup(3)(q26→qter), the most distal duplication of 3q published,³²⁻³⁶ differed from patient 1. Some showed a phenotype resembling Cornelia de Lange syndrome, features definitely absent in our patient.

We tried to find chromosomal differential diagnoses in patients 1 and 2 using the Human Cytogenetic Database.²⁶ We found two chromosomal aberrations when matching tall stature, macrostomia, broad neck, and strabismus as differential diagnoses for patient 1 (trisomy 8 mosaicism and del(18)(q12.2→q21.19)). We combined tall stature, microcephaly, long face, and arachnodactyly for patient 2 and found six chromosomal aberrations: del(3)(pter→p25) and dup(20)(q13→qter), trisomy 8 mosaicism, del(9)(pter→p22), dup(13)(q22→qter), dup(15)(q22→qter), and trip(18p). Interestingly, duplication 15q, with more distal breakpoints present in patient 2, was mentioned. Thus, the phenotype in patient 2 may be representative of a terminal duplication of 15q.

Our investigation was preceded by routine genetic counselling during the first pregnancy of the proband because of sibs with mental retardation of unknown cause. When prometaphase analysis suggested that three chromosomes were involved, detailed investigations by molecular cytogenetic techniques were carried out. First, the exact nature of the balanced translocation was shown by FISH to be a three way terminal translocation, 3q29-qter to 15q26.1, 15q26.1-qter to 6q26, and 6q26-qter to 3q29. The translocation involved the terminal regions of the long arms of the three chromosomes, including a small translocated segment which was unrecognisable by conventional chromosome painting. The presence of a

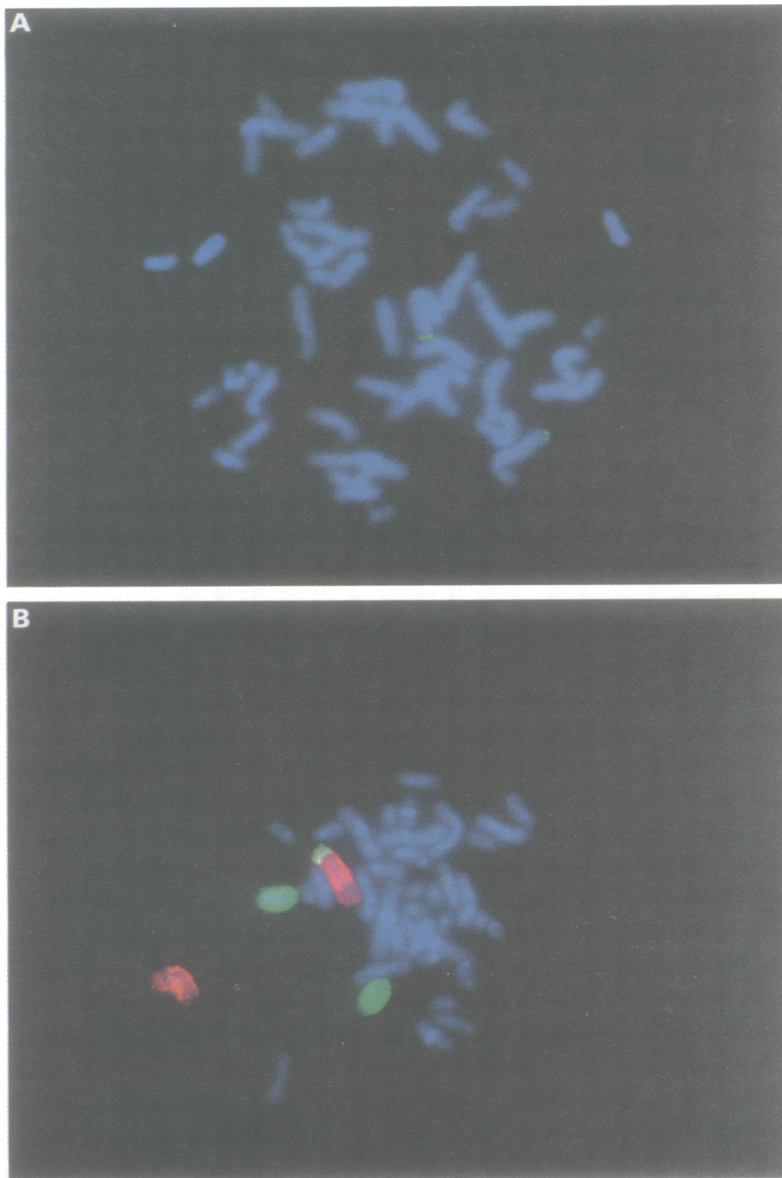


Figure 9 FISH results of patient 2. (A) D3S1445/D3S1446: both chromosomes 3 show clear hybridisation signals in their long arm terminal regions, no signal is present in 15qter. (B) Whole chromosome 6 paint (red/TRITC) and whole chromosome 15 paint (green/FITC): the results with WCP6 (red) are identical to the ones found in patient 1 while hybridisation with WCP15 (green) paints both chromosomes 15 entirely as well as the long arm terminal region of one chromosome 6.

paracentric inversion of the chromosome 15 involved in the translocation posed a particularly vexing problem. In contrast to the proximal breakpoint of the inversion (15q15.1), the distal breakpoint (15q26.1) was the same in the inversion and the translocation. In patient 2 and the balanced carriers, a subtelomeric FISH probe specific for 3q29 (D3S1445, D3S1446) showed that chromosome 3 material was translocated to chromosome 15 in patient 2 and the balanced carriers. The size of this translocation was below the resolution limit of the whole chromosome paint.³⁷ Failure to detect the correct chromosomal recipient would have resulted in false results of the prenatal diagnosis performed in the second and third pregnancy of the consultand.

This finding stresses the importance of cryptic terminal translocations in clinical cytogenetics. As Flint *et al*³⁸ pointed out for patients with so-called idiopathic mental retardation,

subtle translocations, among them terminal ones, may be present in persons whose chromosomes appear normal in high resolution banded preparations and should be checked with appropriate subtelomeric FISH probes. Judging from our findings the same is true if chromosomes give normal results after FISH with whole chromosome painting probes.

The risk for offspring of a carrier of a balanced CCR is difficult to estimate.³⁹ Batista *et al*⁴⁰ gave a risk of miscarriage of about 50% based on an extended review of 30 families with CCRs. Gorski *et al*⁴¹ analysed 25 CCR families with 67 informative pregnancies and found a risk of abnormalities of 18.4% for live births. Nearly 50% of all liveborn offspring were also CCR carriers. The overall risk of an abnormal outcome of pregnancy seems to be of the order of about 50%. The consultand's mother gave birth to two healthy children (II.2 and II.5), one of them a balanced translocation carrier, and two mentally retarded sibs with different unbalanced karyotypes. Two further pregnancies resulted in abortions which have not been investigated. One daughter died during the first weeks of life because of hydrocephalus. One might speculate that she also may have had an unbalanced karyotype, because hydrocephalus is frequently found in partial trisomy 6q and in partial monosomy 15q. Both in the consultand and her mother, abnormal outcome of pregnancy was higher than 50%.

The first two authors contributed equally to this work. We would like to thank the patients and their family for their cooperation, Dr Gabriele Gillessen-Kaesbach for helpful discussions, and Dr Albert Schinzel and Dr Olivier Cohen for reviewing their databases. In addition, we thank Drs A J Green and L Willatt for providing amniotic cell cultures from the third pregnancy.

- Kleckowska A, Fryns JP, Van den Berghe. Complex chromosomal rearrangements (CCR) and their genetic consequences. *J Genet Hum* 1982;30:199-214.
- Wang H, McLaughlin M, Thompson C, Hunter AGW. Use of fluorescence in situ hybridization to confirm the interpretation of a balanced complex chromosomal rearrangement ascertained through prenatal diagnosis. *Am J Med Genet* 1993;46:559-62.
- Batista DAS, Tuck-Muller CM, Martinez JE, Kearns WG, Pearson PL, Stetten G. A complex chromosomal rearrangement detected prenatally and studied by fluorescence in situ hybridization. *Hum Genet* 1993;92:117-21.
- Kousseff BG, Nichols P, Essig YP, Miller K, Weiss A, Tedesco TA. Complex chromosome rearrangements and congenital anomalies. *Am J Med Genet* 1987;26:771-82.
- Tupler R, Maraschio P, Gerardo A, Mainieri R, Lanzi G, Tiepolo L. A complex chromosome rearrangement with 10 breakpoints: tentative assignment of the locus for Williams syndrome to 4q33→q35.1. *J Med Genet* 1992;29:253-5.
- Pinkel D, Landegent J, Collins C, *et al*. Fluorescence in situ hybridization with human chromosome specific libraries: detection of trisomy 21 and translocations of chromosome 4. *Proc Natl Acad Sci USA* 1988;85:9138-42.
- Lichter P, Cremer T, Borden J, Manuelidis L, Ward DC. Delineation of individual human chromosomes in metaphase and interphase cells by in situ suppression hybridization using recombinant DNA libraries. *Hum Genet* 1988;80:224-34.
- Pai GS, Thomas GH. A new R-banding technique in clinical cytogenetics. *Hum Genet* 1980;54:41-5.
- Seabright M. A rapid banding technique for human chromosomes. *Lancet* 1971;ii:971-2.
- Collins C, Kuo WL, Seagraves R, Fuscoe J, Pinkel D, Gray JW. Construction and characterization of plasmid libraries enriched in sequences from single human chromosomes. *Genomics* 1991;11:997-1006.
- ISCN 1995. In: Mitelman F, ed. *An international system for human cytogenetic nomenclature*. Basel: Karger, 1995.
- Sahar E, Latt SA. Enhancement of banding patterns in human metaphase chromosomes by energy transfer. *Proc Natl Acad Sci USA* 1978;75:5650-4.
- Liberfarb RM, Atkins L, Holmes LB. Chromosome 6q- and associated malformations. *Ann Genet* 1978;21:223-5.

- 14 Fryns JP, Bettens W, van den Berghe H. Distal deletion of the long arm of chromosome 6: a specific phenotype? *Am J Med Genet* 1986;24:175-8.
- 15 McLeod DR, Fowlow SB, Robertson A, Samcoe D, Burgess I, Hoo JJ. Chromosome 6q deletions: a report of two additional cases and a review of the literature. *Am J Med Genet* 1990;35:79-84.
- 16 Bartoshesky L, Lewis MB, Pashayan M. Developmental abnormalities associated with long arm deletion of chromosome no 6. *Clin Genet* 1978;13:68-71.
- 17 Rivas F, Ruiz C, Rivera H, Möller M, Serrano-Lucas JJ, Cantu JM. De novo del(6)(25) associated with macular degeneration. *Ann Genet* 1986;29:42-4.
- 18 Jancar J, Karki CB. Unbalanced form of translocation deletion between chromosomes 6 and 22 in a mentally handicapped female (45,XX,-6,+der(6),t(6;22)q25.1:q11.2). *J Ment Defic Res* 1989;33:255-9.
- 19 Stevens CA, Fineman RM, Breg WR, Silken AB. Report of two cases of distal deletion of the long arm of chromosome 6. *Am J Med Genet* 1988;29:807-14.
- 20 Meng J, Fujita H, Nagahara N, Kashiwai A, Yoshioka Y, Funato M. Two patients with chromosome 6q terminal deletions with breakpoints at q24.3 and q25.3. *Am J Med Genet* 1992;43:747-50.
- 21 Goldberg R, Fish B, Ship A, Shprintzen RJ. Deletion of a portion of the long arm of chromosome 6. *Am J Med Genet* 1980;5:73-80.
- 22 Tajara EH, Varella-Garcia M, Tonelli GUS. A case of terminal long arm deletion of chromosome 6. *Rev Brasil Genet* 1990;13:347-51.
- 23 Kristofferson U, Bergwall B. Partial trisomy 15(q25qter) in two brothers. *Hereditas* 1984;100:7-10.
- 24 Gregoire MJ, Boue J, Junien C, Pernot C, Gilgenkrantz S, Zergollern L. Duplication of 15q22→15qter and its phenotypic expression. *Hum Genet* 1981;59:429-33.
- 25 Goldstein DJ, Ward RE, Nichols WC, Palmer CG. Familial t(8;15)(p23.3;q22.3): report of two cases with dup(15)(q22.3→qter). *J Med Genet* 1987;24:684-7.
- 26 *Human Cytogenetics Database*. Oxford: Oxford University Press, 1994.
- 27 Van Allen MI, Siegel-Bartelt J, Feigenbaum A, Teshima IE. Craniosynostosis associated with partial duplication of 15q and deletion of 2q. *Am J Med Genet* 1992;43:688-92.
- 28 Lacro RV, Jones KL, Mascarello JT, Jones OW, Wilson N, Jones MC. Duplication of distal 15q: report of five cases from two different translocation kindreds. *Am J Med Genet* 1987;26:719-28.
- 29 Nahara K, Tsuji K, Yokoyama Y, et al. Specification of small distal 6q deletions in two patients by gene dosage and in situ hybridization study of plasminogen and α -L-fucosidase 2. *Am J Med Genet* 1991;40:348-53.
- 30 Oliveira-Duarte MH, Martelli-Soares LR, Sarquis-Cintra T, Machado ML, Lison MP. Distal monosomy of the long arm of chromosome 6 (6q25-qter) inherited by maternal translocation t(6q;17q). *Ann Genet* 1990;33:56-9.
- 31 Milosevic J, Kalicanin P. Long arm deletion of chromosome no 6 in a mentally retarded boy with multiple physical malformations. *J Ment Defic Res* 1975;19:139-44.
- 32 Fineman RM, Hecht F, Ablow R, Howard RO, Breg WR. Chromosome 3 duplication q/deletion p syndrome. *Pediatrics* 1978;61:611-18.
- 33 Iwasaki H, Abe M, Kato H, Shinohara T, Miyata H. A case of leprechaunism with chromosome abnormality (46,XX,der(21),t(3;21)(q26-q27;q22)pat). *Jpn J Hum Genet* 1978;23:145-51.
- 34 Steinbach P, Adkins WN, Caspar H, et al. The dup(3q) syndrome: report of eight cases and review of the literature. *Am J Med Genet* 1981;10:159-77.
- 35 Stevenson RE, Rogers RC, Phelan MC. De Lange syndrome: dealing with the variants. *Proc Greenwood Genet Center* 1986;5:8-13.
- 36 Arizmendi JFJE, Trucios JA, Soler JLF, Gil EF, Andreu IR, Mateu JT. Síndrome de la trisomía parcial 3q. Aportación de un nuevo caso a la literatura. *Ann Esp Pediatr* 1989;30:391-3.
- 37 Rosenberg C, Blakemore KJ, Kearns WG, et al. Analysis of reciprocal translocation by chromosome painting: applications and limitations of the technique. *Am J Hum Genet* 1992;50:700-5.
- 38 Flint J, Wilkie AO, Buckle VJ, Winter RM, Holland AJ, McDermid HE. The detection of subtelomeric chromosomal rearrangements in idiopathic mental retardation. *Nat Genet* 1995;2:132-40.
- 39 Cohen O, Mermet MA, Cans C, Gilardi JL, Simonet A, Jalbert P. Les translocations réciproques autosomiques familiales humaines. *Ann Genet* 1995;38:177-86.
- 40 Batista DAS, Pai S, Stetten G. Molecular analysis of a complex chromosomal rearrangement by in situ hybridization. *Am J Med Genet* 1994;53:255-63.
- 41 Gorski JL, Kistenmacher ML, Punnett HH, Zackai EH, Emanuel BS. Reproductive risks for carriers of complex chromosome rearrangements: analysis of 25 families. *Am J Med Genet* 1988;29:247-61.
- 42 Krassikoff N, Sekhon GS. Terminal deletion of 6q and Fryns syndrome: a microdeletion/syndrome pair? *Am J Med Genet* 1990;36:363-4.
- 43 Valtat C, Galliano S, Mettey R, Toutain A, Moraine C. Monosomy 6q: report on four new cases. *Clin Genet* 1992; 41:159-66.
- 44 Evers LJM, Schrander-Stumpel CTRM, Engelen JJM, et al. Deletion of the long arm of chromosome 6: two new patients and literature review. *Clin Genet* 1996;50:138-44.
- 45 Castro-Gago M, Rodrigo-Saez E, Marwan A. Delección distal del brazo largo del cromosoma 6 (46,XX,del 6(q24-qter). *Ann Esp Pediatr* 1991;34:167-9.
- 46 Lozzio CB, Maclean R, Lewis S. High resolution banding in subtle chromosome rearrangements. *Am J Hum Genet* 1982;34:133A.
- 47 Shen-Schwarz S, Hill LM, Surti U, Marchese S. Deletion of terminal portion of 6q: report of a case with unusual malformations. *Am J Med Genet* 1989;32:81-6.
- 48 Baldinger S, Arthur DC, Pierpont MEM. Long term survival in distal 15q trisomy. *Am J Hum Genet* 1984;36: 85S.
- 49 Pedersen C. Letters to the editor. *Clin Genet* 1976;9:378-82.
- 50 Schnatterly P, Bono KL, Robinow M, Wyandt HE, Kardon N, Kelly TE. Distal 15q trisomy: phenotypic comparison of nine cases in an extended family. *Am J Hum Genet* 1984;36:444-51.
- 51 Fujimoto A, Townner JW, Ebbin AJ, Kahlstrom EJ, Wilson MG. Inherited partial duplication of chromosome no 15. *J Med Genet* 1974;11:287-91.
- 52 Coco R, Penchaszadeh VB. Inherited partial duplication deficiency of chromosome 15 (p12;q22). *J Genet Hum* 1978;26:203-10.
- 53 Ieshima A, Takeshita K. Distal 15q trisomy with Dandy-Walker malformation in a female infant. *Jpn J Hum Genet* 1985;30:227-32.
- 54 Orye E, Laureys G, Verhaaren H. Mosaic and non-mosaic trisomy 15q2. *Ann Genet* 1985;28:58-60.