

# Presence of the Apert canonical S252W FGFR2 mutation in a patient without severe syndactyly

Maria Rita Passos-Bueno, Antonio Richieri-Costa, Andréa L. Sertié, Alexander Kneppers

**Abstract**

**Apert syndrome, characterised by craniosynostosis, craniofacial anomalies, and symmetrical syndactyly of the digits (cutaneous and bony fusion), has been associated with two canonical mutations in the FGFR2 gene (S252W, P253R) in the great majority of cases. Since these two alterations have been observed exclusively among these patients, it has been suggested that the S252W and P253R changes may play an important role in the occurrence of syndactyly. In order to verify whether the mutations S252W and P253R could also cause a milder phenotype, without involvement of the limbs, we have screened 22 patients with clinical characteristics compatible with Crouzon or Pfeiffer syndrome for these two particular changes. Surprisingly, we identified a Pfeiffer-like patient with the mutation S252W, and therefore we have shown for the first time the occurrence of one of the canonical Apert mutations without severe abnormalities of the upper and lower extremities.**

(J Med Genet 1998;35:677-679)

**Keywords:** Apert syndrome; Pfeiffer syndrome; FGFR2 mutations

Apert syndrome is a relatively rare condition characterised by craniosynostosis, craniofacial anomalies, and symmetrical syndactyly of the digits (cutaneous and bony fusion). It has been considered one of the most severe forms of the craniosynostotic syndromes.<sup>1-3</sup>

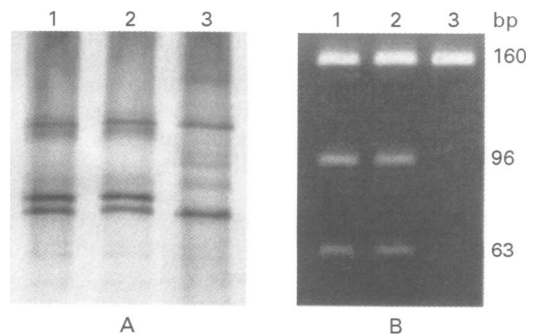
Fibroblast growth factor receptor 2 (FGFR2) mutations have been associated with the Apert phenotype as well as with other craniosynostotic conditions, such as Crouzon, Pfeiffer, and Jackson-Weiss syndromes, which differ from Apert syndrome mainly by the lack of severe abnormalities of the extremities.<sup>1,2,4</sup> Several missense and splicing mutations in exons IIIa and IIIc of the FGFR2 gene have been found in patients with Crouzon, Pfeiffer, and Jackson-Weiss syndromes.<sup>4-7</sup> In contrast, 98.6% of Apert syndrome patients have the S252W or P253R changes, which are located in FGFR2 exon IIIa.<sup>4,8-13</sup> Since these two alterations have been observed exclusively among Apert patients, it has been suggested that these two specific changes always result in syndactyly of the upper and lower limbs.

In order to verify whether the mutations S252W and P253R could also cause a milder phenotype, without severe involvement of the extremities, we have screened 17 Crouzon and

five Pfeiffer syndrome patients for these two particular changes, according to methods previously reported.<sup>7,10,13</sup>

Surprisingly, we identified the S252W change in a Pfeiffer-like subject and this finding was confirmed in two independent DNA samples (fig 1). Subsequently, we sequenced the 5' portion of exon IIIa of this patient which allowed us to confirm the presence of this mutation and to verify that there was no other change in this region of exon IIIa. In addition, we have sequenced FGFR2 exon IIIc of this patient, which was found to be normal (data not shown).

This patient, an African-Brazilian boy, currently aged 4 years (fig 2), is the only affected child of a non-consanguineous, clinically normal couple (mother aged 28 years, father aged 37 years). The pregnancy was normal and delivery was at term by caesarean section. Birth weight was 3900 g (75th centile) and total body length 52 cm (50th centile). Craniofacial and upper and lower limb anomalies were noted at birth. Examination at 5 months of age showed an active child. Height was 67.5 cm (50th centile), weight was 7.9 kg (50th centile), and OFC was 44 cm (<50th centile). He had brachycephaly, a prominent forehead, wide anterior fontanelle and metopic suture, large ears, hypertelorism, sparse eyebrows and lashes, flat supraorbital ridges, prominent eyes, broad nasal root, short neck, brachydactyly, bilateral skin syndactyly between fingers 3 and 4, short and broad terminal phalanges, radial deviation of the fingers, club foot, and short toes with tibial deviation. CT head scan showed mild dilatation of the frontal horn of the lateral ventricles and coronal and lambdoid sutures; the anterior cranial fossa was also slightly wider than the posterior. X rays of the



**Figure 1** Mutational analysis by SSCP (A) and restriction enzyme digestion (B) of genomic DNA from the Pfeiffer-like patient described here (lane 1), one typical Apert patient with S252W (lane 2), and one control (lane 3). The 5' end of the exon IIIa PCR product was digested with *Sfi*I and analysed on an 8% acrylamide gel. The S252W mutation cuts, with *Sfi*I, into 96 bp + 63 bp fragments. Primers and PCR conditions were used as previously reported by Slaney et al.<sup>10</sup>

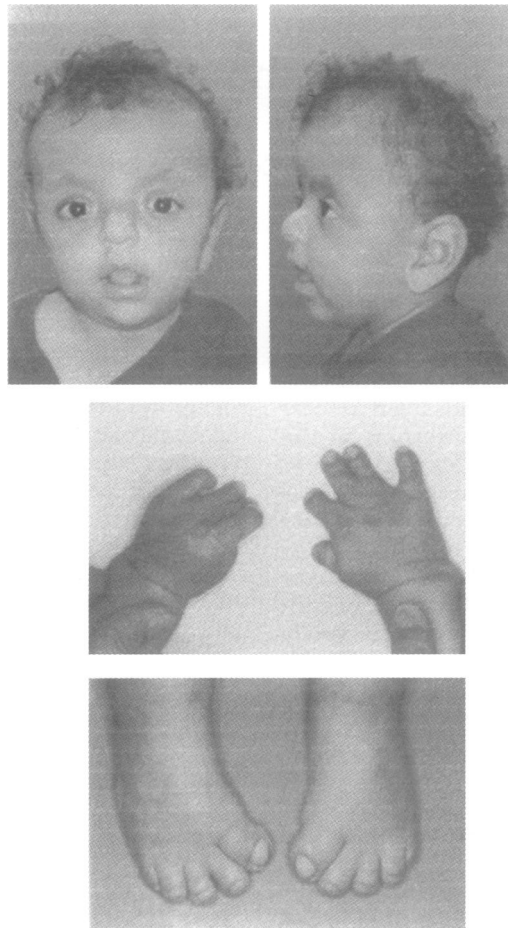
Departamento de Biologia, Instituto de Biociências, Universidade de São Paulo, Rua do Matão 277, São Paulo, SP, Brazil 05508-900  
M R Passos-Bueno  
A L Sertié

Hospital de Pesquisa e Reabilitação de Lesões Lábio Palatais, Bauru, SP, Brazil  
A Richieri-Costa

University of Leiden, The Netherlands  
A Kneppers

Correspondence to:  
Dr Passos-Bueno.

Received 16 October 1997  
Revised version accepted for publication 12 January 1998



**Figure 2** Photographs of the patient with the S252W mutation and a phenotype more compatible with Pfeiffer syndrome. Note the typical facial features of prominent forehead, hypertelorism, and midface hypoplasia. Only soft syndactyly between fingers 3-4 and between toes 2-3 was observed. Hand and foot x ray findings are detailed in the text.

hands showed shortening of the proximal, middle, and distal phalanges of all digits, particularly of the distal phalanges, proximally set and adducted thumbs, and soft tissue syndactyly between fingers 3-4. X rays of the feet showed shortened phalanges of all toes, a short big toe, an increased distance between the first and second toes, and soft tissue syndactyly between toes 2-3. Based on these clinical findings, we considered Pfeiffer syndrome as the most likely diagnosis for this patient (fig 2).

Wilkie *et al*<sup>8</sup> first reported that Apert syndrome was caused by mutations S252W or P253R within exon IIIa of the FGFR2 gene. This narrow spectrum of mutations was confirmed by other studies, since 284 out of the reported 288 Apert syndrome patients have one of these two mutations.<sup>4-13</sup> It is important to point out that although mutation S252W was associated with a milder syndactyly than was P253R, all these patients had fusion of three or more digits in both hands and feet.<sup>10</sup> These DNA alterations lie in the region linking the immunoglobulin (Ig)-like domains II and III of FGFR2, which is a highly conserved sequence among the different FGFRs. It has been proposed that the S252W and P253R substitutions alter the relative orientation of Ig-like domains II and III or the local

conformation of the ligand binding site or both, and hence accentuate binding of fibroblast growth factors (FGFs).<sup>8</sup> Oldridge *et al*<sup>14</sup> have recently described three new mutations in residues 252 and 253; however, only one is associated with Apert syndrome, suggesting that the critical conformation of FGFR2 giving rise to this more severe phenotype also depends on specific amino acids at neighbouring sites.

The present finding of one of the canonical mutations of Apert syndrome not associated with severe syndactyly is intriguing, showing for the first time that S252W may be associated with mild limb anomalies. Since the 5' end of exon IIIa of this patient has no other nucleotide alteration, this milder phenotype is not the result of changes in amino acids bordering residue 252. FGFR2 mutations seem to cause the phenotype according to a gain of function or dominant negative models.<sup>4</sup> Therefore, we could speculate that this patient may have another mutation in some other gene, which is decreasing the function of the mutated FGFR2 molecule. The analysis of other genes in this particular patient, such as the ligands that bind to this receptor, would be important to improve our understanding of the function of FGFR2 as well as for the identification of the mechanisms causing limb malformations.

Variability of the clinical phenotype in subjects carrying the same mutation has been shown for other FGFR2 mutations as well as in other diseases.<sup>7,14-20</sup> Recently, Asher *et al*<sup>21</sup> showed through genetic crosses between two mice species that the Pax3 mutation can produce distinct phenotypes depending on the genetic background. Interestingly, the non-Apert patient reported here is of African Brazilian descent, suggesting that different racial backgrounds, which may reflect variability in some molecules that interact with FGFR2, might interfere differently in the expression of the mutated allele. It will be important to verify if there are other patients with these canonical Apert mutations and absence of severe syndactyly.

In addition to the difficulties in establishing a genotype-phenotype correlation for these conditions, as previously discussed,<sup>16,22,23</sup> the description of this patient provides further evidence for the existence of other factors (or genes) playing an important role in the determination of the phenotype.

The authors gratefully acknowledge the help of Constância Urbani, Antonia M P Cerqueira, Marta Canovas, Eloísa S Moreira, and Luis Alonso; Professor Marcus for allowing us to contact patients who are scheduled for plastic surgery; and Drs Mayana Zatz and Andrew Wilkie for valuable suggestions. This work was supported by grants from Fundação de Amparo a Pesquisa do Estado de São Paulo (FAPESP), Conselho Nacional de Desenvolvimento Científico e Tecnológico (CNPq), and Programa de Apoio ao Desenvolvimento Científico e Tecnológico (PADCT), PRONEX. The research of MRPB was supported in part by an International Research Scholars grant from the Howard Hughes Medical Institute.

- 1 Cohen MM Jr. *Craniosynostosis: diagnosis, evaluation and management*. New York: Raven Press, 1986.
- 2 Gorlin RJ, Cohen MM, Levin LS. *Syndromes of the head and neck*. 3rd ed. Oxford: Oxford University Press, 1990:519-39.
- 3 Kreiborg S, Cohen Jr MM. Epidemiologic, genetic and statistical aspects of Apert syndrome. *Braz J Dysmorphol Speech-Hearing Disord* 1997;1:67-72.
- 4 Wilkie AOM. Craniosynostosis: genes and mechanisms. *Hum Mol Genet* 1997;6:1647-56.

- 5 Reardon W, Winter RM, Rutland P, Pulleyn LJ, Jones BM, Malcolm S. Mutations in the fibroblast growth factor receptor 2 gene cause Crouzon syndrome. *Nat Genet* 1994; 8:98-103.
- 6 Jabs EW, Li X, Scott AF, et al. Jackson-Weiss and Crouzon syndromes are allelic with mutations in fibroblast growth factor receptor 2. *Nat Genet* 1994;8:275-9.
- 7 Rutland P, Pulleyn LJ, Reardon W, et al. Identical mutations in the FGFR2 gene cause both Pfeiffer and Crouzon syndrome phenotypes. *Nat Genet* 1995;9:173-6.
- 8 Wilkie AOM, Slaney SF, Oldridge M, et al. Apert syndrome results from localized mutations of FGFR2 and is allelic with Crouzon syndrome. *Nat Genet* 1995;9:165-72.
- 9 Park WJ, Theda C, Maestri NE, et al. Analysis of phenotypic features and FGFR2 mutations in Apert syndrome. *Am J Hum Genet* 1995;57:321-8.
- 10 Slaney SF, Oldridge M, Hurst JA, et al. Differential effects of FGFR2 mutations on syndactyly and cleft palate in Apert syndrome. *Am J Hum Genet* 1996;58:923-32.
- 11 Hollway GE, Suthers GK, Hann EA, et al. Mutation detection in FGFR2 craniosynostosis syndromes. *Hum Genet* 1997;99:252-5.
- 12 Wada C, Ishigaki M, Toyo-Oka Y, et al. Nucleotide sequence at intron 6 and exon 7 junction of fibroblast growth factor receptor 2 and rapid mutational analysis in Apert syndrome. *Jpn J Clin Pathol* 1996;44:435-8.
- 13 Passos-Bueno MR, Sertié AL, Richieri-Costa A, et al. Description of a new mutation and characterization of FGFR1, FGFR2 and FGFR3 mutations among Brazilian patients with syndromic craniosynostosis. *Am J Med Genet* (in press).
- 14 Oldridge M, Lunt PW, Zackai EH, et al. Genotype-phenotype correlation for nucleotide substitutions in the IgII-IgIII linked form of FGFR2. *Hum Mol Genet* 1997;6:137-43.
- 15 Meyers GA, Day D, Goldberg R, et al. FGFR2 exon IIIa and IIIc mutations in Crouzon, Jackson-Weiss, and Pfeiffer syndromes: evidence for missense changes, insertions and a deletion due to alternative RNA splicing. *Am J Hum Genet* 1996;58:491-8.
- 16 Gorry MC, Preston RA, White GJ, et al. Crouzon syndrome: mutations in two spliceforms of FGFR2 and a common point mutation shared with Jackson-Weiss syndrome. *Hum Mol Genet* 1995;4:1387-90.
- 17 Passos-Bueno MR, Richieri-Costa A, Sertié A, Zatz M. A Pfeiffer mutation in an Apert patient: how wide is the spectrum of variability due to mutations in the FGFR2 gene? *Am J Med Genet* 1997;71:243-5.
- 18 La Spada AR, Wilson EM, Lubahn DB, Harding AE, Fischbeck KH. Androgen receptor mutations in X-linked spinal and bulbar muscular atrophy. *Nature* 1991; 352:77-9.
- 19 McPaul MJ, Marcelli M, Zoppi S, Griffin JE, Wilson JD. Genetic basis of endocrine disease: the spectrum of mutations in the androgen receptor gene that causes androgen resistance. *J Clin Endocrinol Metab* 1993;76:17-23.
- 20 Bellus GA, Gaudenz K, Zackar EH, et al. Identical mutations in three different fibroblast growth factor receptor genes in autosomal dominant craniosynostosis syndromes. *Nat Genet* 1996;14:174-6.
- 21 Asher JH, Harrison RW, Morell R, Carey ML, Friedman TB. Effects of Pax3 modifier genes on craniofacial morphology, pigmentation, and viability: a murine model of Waardenburg syndrome variation. *Genomics* 1996;34: 285-98.
- 22 Cohen MM. Craniosynostoses: phenotypic/molecular correlations. *Am J Med Genet* 1995;56:334-9.
- 23 Winter RM, Reardon W. Lumpers, splitters and FGFRs. *Am J Med Genet* 1996;63:501-2.