

Distal 6p deletion syndrome: a report of a case with anterior chamber eye anomaly and review of published reports

Caroline J Law, Andrew M Fisher, I Karen Temple

Abstract

We describe a 32 year old male with a distal 6p24.3→pter deletion. He has specific developmental anomalies of the anterior chamber of the eye and a cleft uvula which is consistent with the recent localisation of genes for iris development and orofacial clefting to distal 6p. In addition he has progressive sensorineural deafness and this may localise a gene for deafness to this region. We conclude that a refined distal 6p deletion syndrome exists and includes a characteristic facial appearance with hypertelorism, downward slanting palpebral fissures, tented mouth, smooth philtrum, palatal malformation, ear anomalies, anterior chamber eye defects, progressive sensorineural deafness, cardiac defects, abdominal herniae, small external genitalia, and motor and speech delay.

(J Med Genet 1998;35:685-689)

Keywords: chromosome 6; deletion; anterior chamber eye defects; progressive sensorineural deafness

There have been 18 cases previously reported with a 6p deletion, excluding ring chromosome 6.¹⁻¹² A distinct 6p deletion syndrome has emerged and Palmer *et al*⁶ in their review included mental retardation, microcephaly, abnormal sutures, broad nasal bridge, various eye and ear abnormalities, a short neck with excess skin folds, pectus excavatum, and heart defects. A cleft or high arched palate was common (table 1).

We report a patient with a distal 6p deletion who at the age of 32 years is the oldest reported patient. He has specific malformations of the eye, palate, and ear which further delineates the distal 6p deletion syndrome.

Case report

The proband is the eldest child of non-consanguineous parents. He has two healthy sibs and there is no family history of relevance. He was born following a normal pregnancy at 39 weeks' gestation to a 23 year old woman. Birth weight was 3290 g (25th-50th centile). On review aged 9 weeks he was found to have marked hypertelorism, downward slanting palpebral fissures with an eccentric left pupil, choanal narrowing, short philtrum, a high arched palate, low set ears, umbilical hernia, left inguinal hernia, a small, left, undescended testis, small genitalia, systolic cardiac murmur,

single palmar crease, and generalised hypotonia. He had extensive eczema and was failing to thrive.

By the age of 3 months there was concern about his hearing and by 9 months it was clear he only localised sound to the right and was apparently deaf on the left. Examination by a consultant ophthalmologist at 13 months found a small angle right divergent squint with a right oval pupil, left iris hypoplasia, left eccentric pupil, and multiple bilateral anterior synechiae reported as bilateral Rieger anomaly. More recent ophthalmological examination has not been possible.

There was developmental delay. At 18 months he could not pull himself up to sit or feed himself. He started to walk at 27 months. He spoke three words by 42 months. Early photographs showed he had distinctive facial features (fig 1). His mother described his teeth as being poor with many caries. His first dentition was reported as having poor enamel but no further details are available.

Throughout his infancy he had regular audiometry which showed variable bilateral loss of between 25 to 70 db bilaterally although always worse on the left. It was initially thought to be

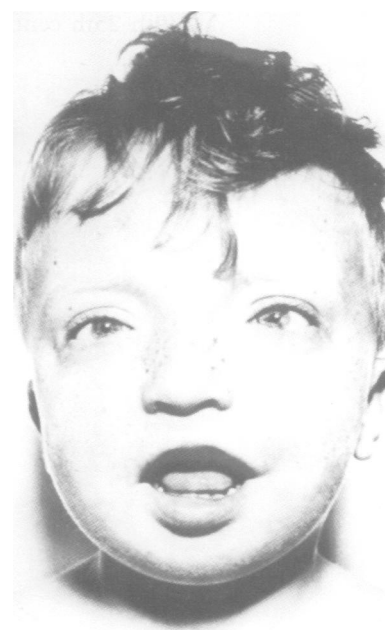

Figure 1 The proband as a child, showing marked hypertelorism with downward slanting palpebral fissures, smooth, short philtrum, and thin, downturned lips.

Wessex Regional Genetics Service, Southampton University Hospitals Trust, Southampton, UK

C J Law
I K Temple

Wessex Regional Genetics Laboratory, Salisbury District Hospital, Salisbury, Wiltshire, UK
A M Fisher

Correspondence to: Dr Law.

Received 26 June 1997
Revised version accepted for publication 13 January 1998

Table 1 Comparison of clinical findings in cases of 6p deletion

Author	11	7	3	1	5	2
Case	2				1	2
Deletion	6p24.3→pter	6p24.1/24.2→pter	6p24→pter	6p24→p25	6p23→pter	6p23→pter
Sex	M	F	F	F	F	M
Age at last follow up	32 y	11 mth	2 y 4 mth		5 mth	6 y
OFC centile at birth/follow up	90		>95			
Abnormal skull shape +/- hydrocephalus	+	+		+	+	+
Hypertelorism/telecanthus	+	+	+	+	0	0
Downward slanting palpebral fissures	+	0	+	0	0	0
Anterior chamber eye anomaly	+	0	0	+	0	0
Other eye anomaly structural or functional	-	+	+	0	0	0
Tented mouth	+	0	+	0	0	0
Palatal anomaly	+	+	+	0	+	0
Cleft lip	-	+	0	0	+	0
Ear anomalies	+	+	+	+	+	+
Short neck +/- redundant nuchal skin	+	0	+	0	+	0
Chest deformity	+	0	0	0	+	0
Heart defect	+	-	-	+	+	0
Genital anomaly	+	0	-	0	+	+
Hernia umbilical/inguinal	+	0	-	0	0	+
Sensorineural deafness	+	0	+	0	0	0
Developmental delay/hypotonia	+	0	+	0	+	+

Feature present +, feature absent -, feature not mentioned 0.

a conductive loss and he had bilateral myringotomies and adenotonsillectomy at the age of 6 years. His hearing deteriorated and later audiograms showed a progressive sensorineural deafness. In adult life he has a 60-70 db loss on the right and a 100 db loss on the left. He attended a special school for the deaf.

Puberty occurred normally at 14 years. Aged 17 he developed a recurrent supraventricular tachycardia controlled with medication and he was shown to have a stenosed and incompetent bicuspid aortic valve. At 21 he developed an intermittent petechial rash over his feet, ankles, and shins. A vasculitis was diagnosed following a biopsy. He was otherwise well.

When seen aged 32 he was living with his parents and worked full time as a machine operator in a factory. He had been in the post 10 years. He has just passed his driving test.

On examination, height was 171.45 cm (9th-25th centile) and occipitofrontal circum-

ference was 56.8 cm (90th centile). He was brachycephalic with a broad forehead. He had hypertelorism with mild downward slanting palpebral fissures and puffiness beneath both eyes and along the lateral border of the nose. The philtrum was short and smooth. He had a downturned mouth with an absent Cupid's bow. His ears were mildly posteriorly rotated (fig 2). His neck was short and he had sloping shoulders and a flared costal margin. His genitalia were small with small testes. There was a single palmar crease bilaterally and mild bilateral fifth finger clinodactyly. He had short big toes bilaterally and petechiae over the feet.

CYTOGENETIC INVESTIGATIONS

The initial cytogenetic investigation (1964) was on unbanded metaphases from unsynchronised culture of PHA stimulated blood lymphocytes; no abnormality was found at that time. Recent investigation involved the now

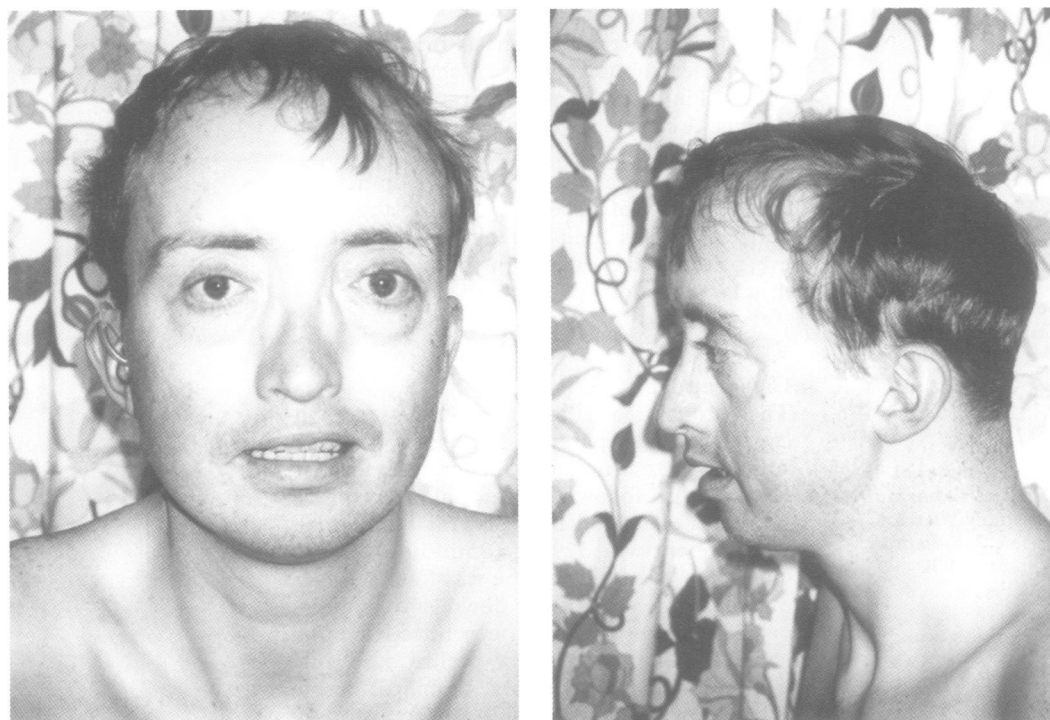

Figure 2 The proband aged 32 showing characteristic facial appearance.

Table 1 continued

6	8	9	2	3	4	5	10	2	4
6p23→pter M 18 mth	6p23→pter 4 y 3 mth	6p23→pter F 3 mth	6p23→pter M 75	6p23→pter M 6 mth	6p23→pter F 2 y	6p23→pter F 18 y	6p23→pter F 3 y 4 mth 3 to 10	6p22.2→pter F	6p22.33→pter/6p22.2→p25.2 M 3 y 6 mth
2	0.4	25	75	5	75				95
+	+	+	+	+	0	0	+	0	+
+	+	0	+	0	0	0	0	0	0
+	+	-	+	0	0	0	0	0	0
+	-	0	0	0	0	0	0	0	0
0	+	0	0	+	0	+	+	+	0
+	0	0	+	0	0	0	0	0	0
0	+	0	+	0	+	+	0	+	0
-	+	0	-	0	+	0	-	+	0
+	+	0	+	+	+	0	+	+	+
0	0	0	+	+	0	0	+	+	0
0	+	+	+	0	0	0	0	0	+
+	-	+	+	+	0	-	+	+	+
+	0	0	+	+	0	0	+	0	+
0	+	0	0	0	0	0	0	0	+
+	0	0	0	0	0	0	0	0	0
+	+	+	0	+	0	+	+	0	+

conventional techniques of G banded analysis of prometaphase chromosomes from PHA stimulated and FdU synchronised blood lymphocytes. On this occasion the patient was shown to have a male karyotype with a small terminal deletion of the short arm of chromosome 6 in all cells examined (fig 3). Fluorescence in situ hybridisation (FISH) was performed as previously described¹³ using a PAC subtelomere probe, 36I2, specific for the short arm of chromosome 6.¹⁴ This was shown to hybridise to the distal short arm of the normal chromosome 6 but was absent from the deleted homologue (fig 4), providing further evidence as to the terminal nature of the deletion. The chromosomes of the patient's parents were examined by G banded analysis and found to be normal. The patient's karyotype is therefore 46,XY,del(6)(p24.3)de novo.ish del(6)(p25p25)(36I2-). A cell line is available, deposit number DD2952, from The European Collection of Cell Cultures, Centre for Applied Microbiology and Research, Salisbury, Wiltshire SP4 OJG.

Discussion

Although the distal 6p deletion syndrome has been characterised by Palmer *et al*⁸ (mental retardation, microcephaly, abnormal sutures, broad nasal bridge, various eye and ear abnormalities, a short neck with excess skin folds, and a normal birth weight and length), our

review of the reported cases has shown quite marked variation between patients in facial appearance and reported congenital anomalies (table 1). Many of the features are non-specific which makes it very difficult to establish a diagnosis without the karyotypic evidence. However, this may reflect under-reporting in the past of sometimes subtle but specific anatomical anomalies such as the anterior chamber findings and progressive deafness seen in our patient.

Two patients have been previously reported with distal 6p deletions and anterior chamber anomalies although the clinical descriptions are brief with no detailed description of the eye findings. Kelly *et al*⁹ described corneal opacity secondary to Rieger anomaly and Reid *et al*³ reported corneal opacities which they have interpreted as being a Peters anomaly. Our patient was diagnosed as having a bilateral Rieger anomaly although he has not been reviewed recently. Iridogoniodysgenesis characterised by iris stromal hypoplasia, abnormal iridocorneal angle, and subsequent glaucoma has been mapped to distal 6p25 following linkage in two large dominant families.¹⁵ Rieger anomaly characterised by a prominent, anteriorly displaced Schwalbe's line, iris stromal hypoplasia, and displaced pupil has also been mapped to distal 6p25 in the seven affected members of a 13 member family.¹⁶ There are many similarities between iridogoniodysgenesis and Rieger anomaly, the latter differing only by the inclusion of a displaced or prominent Schwalbe's line with iris adhesions. The fact that both conditions have been mapped to 6p25 would suggest that they are allelic or that there are several genes involved in anterior chamber formation at this locus. In addition, corneal opacities are common in iridogoniodysgenesis and Rieger anomaly and similar to those seen in Peters anomaly. It is likely, therefore, that the anterior chamber findings in the 6p deletion cases are within the same spectrum and are consistent with haploinsufficiency for one or more genes involved in anterior chamber development.

It is surprising that these eye findings have not been reported in all 6p deletion cases. This



Figure 3 Ideogram, with breakpoint arrowed, and partial karyotypes showing the normal chromosome 6 on the left and the del(6p) on the right.

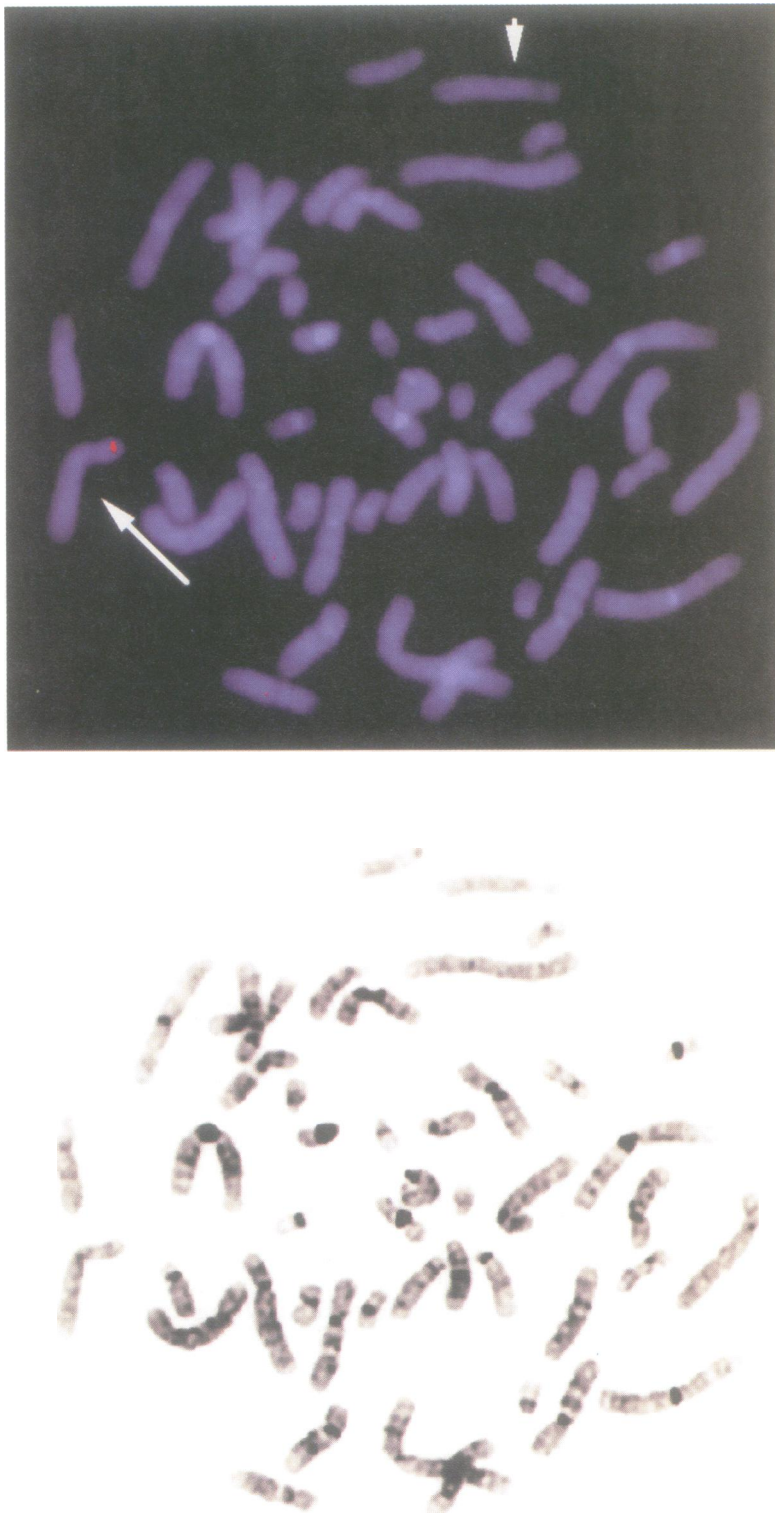


Figure 4 A metaphase on which FISH was performed using the subtelomeric probe 36I2, as described, and counterstained with DAPI. (Above) The probe 36I2 is present (red signal) on the distal short arm of the normal chromosome 6 (arrow) and absent from the del(6) (arrowhead). (Below) Computer generated G banded-like image of the same metaphase.

could be because the eyes were not examined specifically with a slit lamp. Several reports include structural eye anomalies (table 1) which are less specific, including microphthalmia,^{2 8 9} corneal opacity,^{3 6 11} miosis,¹⁰ retinal coloboma,¹¹ and Brushfield spots.⁹ Functional abnormalities include nystagmus,^{2 4} squint,^{7 10} myopia,¹² and hyperopia.⁷ Another possibility is that some of

the reported cases were not deleted for 6p25. The majority of the patients reported with distal 6p deletions have deletions extending from 6p23→pter (table 1), but as Davies *et al.*² have shown it is only with the advent of molecular characterisation of a deletion that the monosomic region can be precisely delineated. They report two cases previously described as having terminal 6p23 deletions which they now show have interstitial deletions that do not involve deletion of 6p25; interestingly neither patient has an anterior chamber anomaly.

Our patient also highlights the tendency of this group of patients to have herniae of the umbilicus and inguinal region (table 1) and small and abnormal development of the genitalia in males.

The proband has striking facial features (fig 2) with marked hypertelorism, short philtrum, and a thin, downturned upper lip. He has a similar facial appearance to a subset of the reported 6p deletion cases including patient 2 of Palmer *et al.*,⁹ the male patient reported by Kelly *et al.*,⁶ and the patient described by Zurcher *et al.*⁷ In this latter report, the deletion is also 6p24→pter and it is possible that the size and site of the deletion is crucial for the development of these specific facial features. The cleft uvula is in keeping with the mapped locus for orofacial clefting at 6p24.3.¹¹ Those patients with a cleft lip in association with abnormal palatal development are those described with larger deletions involving 6p23 (table 1).

It is of interest that our patient had sensorineural deafness. This has also been reported in the context of distal 6p deletion by Kelly *et al.*⁶ and Zurcher *et al.*⁷ and it is possible that this phenomenon is under-reported because it is progressive. It was not fully appreciated in our patient until he was 6 years of age. Many of the reported cases had profound language delay^{4-7 12} and communicated with sign language.⁵ This could reflect an undiagnosed hearing loss. We speculate that there is a gene for progressive deafness at 6p24→pter.

Our patient is the oldest patient described to date. Despite some learning difficulties, exacerbated by poor vision and profound hearing deficit, he is generally healthy and maintains a full time job.

This report defines a more specific distal 6p deletion phenotype which includes a characteristic facies with hypertelorism, downturned, tented mouth and smooth philtrum, cleft palate, anterior chamber maldevelopment of the eye, progressive sensorineural deafness, a short neck, cardiac defects, hypogonadism, abdominal herniae, and speech and motor delay. Further investigations are required to define the extent of the deletion more precisely and to locate genes on distal 6p of possible relevance to the phenotype.

We thank Adele Murrell for the initial G banded analysis, Nick Wire, Jane Early, Chrisy Joyce, Kirk Moore, and John Crolla for help in the course of this work and the National Institutes of Health and Institute of Molecular Medicine Collaboration for kindly providing the probe 36I2. Image analysis equipment was financed by a grant from the Wellcome Trust.

- 1 Ouchi K, Kasai R. A case of partial monosomy 6p. *Jpn J Hum Genet* 1982;27:214.
- 2 Sachs ES, Hoogeboom AJM, Niermeijer MF, Schreuder GM. Clinical evidence for localisation of HLA proximal of chromosome 6p22. *Lancet* 1983;i:659.
- 3 Reid CS, Stamberg J, Phillips JA. Monosomy for distal segment 6p: clinical description and use in localising a region important for expression of Hageman factor. *Pediatr Res* 1983;17:A217.
- 4 Van Swaay E, Beverstock GC, Van De Kamp JJP. A patient with an interstitial deletion of the short arm of chromosome 6. *Clin Genet* 1988;33:95-101.
- 5 Jalal SM, Macias VR, Roop H, Morgan F, King P. Two rare cases of 6p partial deletion. *Clin Genet* 1989;36:196-9.
- 6 Kelly PC, Blake WW, Davis JR. Tandem Y/6 translocation with partial deletion 6(p23-pter). *Clin Genet* 1989;36:204-7.
- 7 Zurcher VL, Golden WL, Zinn AB. Distal deletion of the short arm of chromosome 6. *Am J Med Genet* 1990;35:261-5.
- 8 Kormann-Bortolotto MH, Farah LMS, Soares D, Corbani M, Muller R, Adell ACA. Terminal deletion 6p23: a case report. *Am J Med Genet* 1990;37:475-7.
- 9 Palmer CG, Bader P, Slovak ML, Comings DE, Pettenati MJ. Partial deletion of chromosome 6p: delineation of the syndrome. *Am J Med Genet* 1991;39:155-60.
- 10 Plaja A, Vidal R, Soriano D, et al. Terminal deletion of 6p: report of a new case. *Ann Genet* 1994;37:196-9.
- 11 Davies AF, Stephens RJ, Olavesen MG, et al. Evidence of a locus for orofacial clefting on human chromosome 6p24 and STS content map of the region. *Hum Mol Genet* 1995;4:121-8.
- 12 Davies AF, Olavesen MG, Stephens RJ, et al. A detailed investigation of two cases exhibiting characteristics of the 6p deletion syndrome. *Hum Genet* 1996;98:454-9.
- 13 Pinkel D, Landegent J, Collins C, et al. Fluorescence in situ hybridization with human chromosome-specific libraries: detection of trisomy 21 and translocations of chromosome 4. *Proc Natl Acad Sci USA* 1988;85:9138-42.
- 14 Ning Y, Roschke A, Smith ACM, et al. A complete set of human telomeric probes and their clinical application. *Nat Genet* 1996;14:86-9.
- 15 Mears AJ, Mirzayans F, Gould DB, Pearce WG, Walter MA. Autosomal dominant iridogoniodysgenesis anomaly maps to 6p25. *Am J Hum Genet* 1996;59:1321-7.
- 16 Gould DB, Mears AJ, Pearce WG, Walter MA. Autosomal dominant Axenfeld-Rieger anomaly maps to 6p25. *Am J Hum Genet* 1997;61:765-8.