

Discordant phenotypes and 45,X/46,X, idic(Y)

Thaddeus E Kelly, James B Franko, Alan Rogol, Wendy L Golden

Abstract

Mosaicism introduces wide variability into the clinical expression of numerical and unbalanced structural chromosomal abnormalities. The phenotypic range of variability of 45,X/46,XY mosaicism extends from Turner syndrome to mixed gonadal dysgenesis to normal males. The specific phenotype is primarily dependent on the chromosomal constitution of the developing gonad. Similar phenotypic variability is observed with mosaicism for 45,X and a second cell line with an abnormal sex chromosome. This report describes a patient with Turner syndrome and a patient with mixed gonadal dysgenesis who have identical karyotypes, namely 45,X/46,X, idic(Y)(p11.2). While mosaicism alone might have accounted for the phenotypic differences, by PCR analysis the Turner syndrome patient was SRY and ZFY negative and the mixed gonadal dysgenesis patient was SRY and ZFY positive.

(*J Med Genet* 1998;35:862-864)

Keywords: mixed gonadal dysgenesis; Turner syndrome; dicentric Y chromosome; testis determining factor

Structurally abnormal Y chromosomes are often seen in mosaicism with a 45,X cell line. The associated phenotype displays wide variability. Similarly, mosaicism for 45,X/46,XY exhibits wide variability ranging from Turner syndrome to mixed gonadal dysgenesis to normal males. With the latter karyotype it is apparent that the phenotypic diversity is primarily dependent on the dominant cell line present in the developing gonad; that is, if the predominant cell line is 45,X the phenotype is Turner syndrome, if the predominant cell line is 46,XY the phenotype is that of a male, and if both cell lines are well represented in the gonad, the result is mixed gonadal dysgenesis. With 45,X/46,XY mosaicism, the frequency of 45,X and 46,XY cells in peripheral leucocytes often does not correlate with the phenotype. In cases with 45,X and mosaicism for a second cell line with a structurally abnormal Y chromosome, another mechanism for phenotypic diversity is possible, that is, the presence or absence of the sex determining gene, SRY, on the structurally abnormal Y chromosome. This report describes two patients with a similar karyotype, namely 45,X/46,X, idic(Y)(p11.2). One patient presented with Turner syndrome, the other with mixed gonadal dysgenesis. Molecular analysis of the abnormal Y chromosome suggests that despite the karyotypic similarity of the abnormal Y,

molecular differences explain the differences in the observed phenotypes.

Case reports

Case 1 is a 54 year old male referred to the genetics clinic for evaluation of ambiguous external genitalia. He had been seen by the referring physician (JF) because of headaches and hypertension.

He was the third born child in a sibship of six delivered at home. The attending physician had signed the birth certificate designating the infant a male and this was never later questioned by the family. No medical records are available from his childhood, but the family reports that he was delayed in his development and shorter than his peers.

At 6 years of age he entered public school, but as he was unable to learn he was withdrawn from school and had no further formal education. As a teenager he remained short and experienced no secondary sexual development. He was said to have enjoyed good general health until his hypertension prompted medical evaluation at 54 years of age.

His physical examination showed a height of 140 cm, weight of 42.5 kg, and blood pressure of 165/83 mm Hg. This obviously short and obese man spoke only in single words. He had a paucity of body hair with no beard and a female escutcheon. In addition to his obesity he had a modest degree of gynaecomastia. Femoral pulses were full and equal. The external genitalia comprised a 2 cm phallus with a redundant ventral foreskin. The glans contained the external urethral meatus. The labioscrotal folds were fused with minimal rugation and hyperpigmentation. No gonadal structures were palpable. At the base of the phallus, there was a 2 mm orifice that was not probed.

Case 2 is a 13 year old female referred to the paediatric endocrine clinic for initial evaluation of short stature. She began to deviate from the growth curve at approximately 2 years of age and showed further slowing of her growth rate at 6 years of age. She had no serious illnesses and was on no medication. On her initial visit she expressed greater concern about her lack of secondary sexual development than her short stature.

Physical examination showed a height of 134.5 cm which was well below the 5th centile on a standard growth chart, but at the 75th centile on a Turner syndrome growth chart. Weight was 32 kg (slightly below the 5th centile) and blood pressure was 107/64 mm Hg. She did not have webbing of her neck, a low posterior hairline, or other stigmata of Turner syndrome. The cardiac examination was normal and there was no peripheral oedema. Her metacarpals were of normal

Division of Medical Genetics, University of Virginia School of Medicine, Charlottesville, Virginia, USA
T E Kelly
W L Golden

Division of Pediatric Endocrinology, University of Virginia School of Medicine, Charlottesville, Virginia, USA
A Rogol

Roanoke Memorial Hospital, Roanoke, Virginia, USA
J B Franko

Correspondence to:
Dr Kelly, Box 386, Health Science Center,
Charlottesville, VA 22908,
USA.

Received 5 January 1998
Revised version accepted for
publication 2 March 1998

Table 1 Distribution of cell lines

Patients	45,X	46,X,idic(Y)	47,X,idic(Y)×2	46,XY
Case 2	88/100	10/100	1/100	1/100
Case 1	53/69	14/69	1/69	1/69

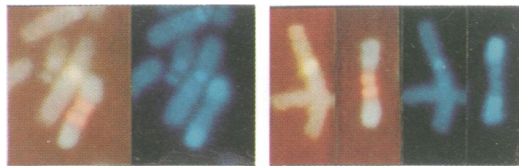


Figure 1 Partial karyotypes from fluorescent in situ hybridisation analysis using alpha satellite probes for the X (green signals) and Y (red signals) chromosomes. (Left) Case 1. Left panel shows a normal X and the dicentric nature of the Y chromosome. Right panel shows the two heterochromatic regions of the abnormal Y using DAPI. (Right) Case 2. Left panel shows a normal X chromosome and the similar nature of the dicentric Y. Right panel shows the two heterochromatic regions of the abnormal Y using DAPI.

length and her finger and toe nails were normal. She had bilateral breast buds with immature nipples and pale areolae and Tanner stage 1 sexual development. The vaginal mucosa did not show any significant oestrogen effect.

Laboratory investigations

FSH was at postmenopausal levels in both patients (case 1 37.2 mIU/l and case 2 181 mIU/l). Case 2 had normal thyroid function studies and normal levels of IGF-1 and IGFBP-3. An abdominal ultrasound on case 2 showed normal kidneys and ureters with a prepubertal sized uterus. A pelvic ultrasound on case 1 showed a tubular structure with a craniocaudal dimension of 4 cm and an AP dimension of 1 cm thought to represent a rudimentary uterus. A 1 cm structure in the left inferior pelvis was felt to represent a rudimentary ovary; no structure was seen on the right.

In both patients the majority of cells were 45,X and each had a cell line with an isodicentric Y chromosome. The breakpoint appeared to be at Yp11.2. Both cases also had a single cell that contained two copies of the abnormal Y and each had a single normal 46,XY cell. The distribution of cell lines is shown in table 1.

Dual colour fluorescent in situ hybridisation (FISH) analysis using the alpha satellite probes for the X (DXZ1) and Y (DYZ3) chromosomes (Vysis, Inc) showed the dicentric nature of the abnormal Y chromosomes. The dicentric Y chromosome in these two cases was indistinguishable (fig 1).

Y DNA was analysed by PCR in both cases using Y specific DNA primers (Research Genetics) as previously described.¹ DNA extracted from peripheral leucocytes of both patients amplified the Y centromeric marker DYZ1. The DNA from case 1 amplified both SRY and ZFY while the DNA from case 2 amplified neither of these two loci.

Discussion

Mosaicism introduces considerable phenotypic variability regardless of whether the abnormality involves an aneuploidy or a cell line with an

unbalanced structural rearrangement and is a common finding in both situations. Mosaicism for 45,X/46,XY is observed in patients with Turner syndrome, mixed gonadal dysgenesis, and apparently normal males. It is clear that sexual determination in mosaic subjects is primarily dependent on the dominant cell type in the undifferentiated gonad, that is, 45,X leads to Turner syndrome, 46,XY to a male phenotype, and the presence of both cell lines results in mixed gonadal dysgenesis. Kocova *et al*² and Sugarman *et al*³ have reported cases with a streak gonad on one side that was 45,X and negative for Y DNA by FISH and PCR, while the other gonad contained testicular elements and was positive for Y DNA by FISH and PCR. Fugimoto *et al*⁴ reported monozygotic twins discordant for sex with 45,X/46,X,idic(Y) mosaicism.

Mosaicism involving an abnormal Y chromosome is associated with a similar pattern of wide phenotypic diversity. It is clear from studies with transgenic mice that the presence of *sry* alone is sufficient to initiate testicular development. Thus, the presence or absence of SRY on the abnormal Y chromosome introduces another factor leading to phenotypic diversity. Mendez *et al*⁵ described the clinical, cytogenetic, endocrinological, and histopathological findings in 16 patients with mixed gonadal dysgenesis. All but one had genital ambiguity and 10 had features of Turner syndrome. While 45,X/46,XY was the most commonly observed karyotype, four patients were mosaic for 45,X and a cell line with a dicentric Y chromosome. They suggested that further knowledge of the status of the testis determining factor in these patients was necessary for an understanding of the basis for the wide variability characteristic of this disorder.

In each of the patients described in this report, a single, apparently normal 46,XY cell was found. This suggests that the karyotype of the zygote was 46,XY with an early mitotic error generating the idic(Y) that subsequently was lost from most cells generating the 45,X cell line. In our experience, DNA of a 46,XY male diluted 1 to 1000 with DNA of a 46,XX female will allow amplification of Y DNA, such as SRY and ZFY. However, such amplification was not observed with DNA from case 2. The presence of one cell in each patient with two idic(Y) chromosomes is considered to be phenotypically insignificant and probably reflects mitotic instability of cells with a structurally abnormal Y chromosome. The Turner syndrome patient described here was unambiguously female despite the presence of an idic(Y) chromosome, presumably because the abnormal Y chromosome did not contain SRY. The mixed gonadal dysgenesis patient's phenotype is more like that of a partially virilised female with Turner syndrome. This presumably resulted from gonadal mosaicism for cells bearing the idic(Y) chromosome that contained the SRY gene.

In patients with Turner syndrome or mixed gonadal dysgenesis the presence of a normal or abnormal Y chromosome raises concerns about the potential for gonadoblastoma.

Among the large series of patients with Y chromosome aneuploidy reported by Hsu⁶ were 44 cases with a dicentric Y chromosome. Of these, 42 occurred in mosaicism with 45,X and two were apparently non-mosaic. Fourteen of these patients were clinically called males and none developed gonadoblastoma. Among 18 patients with Turner syndrome and 12 patients with genital ambiguity, four had gonadoblastomas.

With mosaicism for 45,X with either 46,XY or a cell line with a structurally abnormal Y, the presence of SRY may be protective against gonadoblastoma given near normal testicular development and a male phenotype. With dysgenetic gonads and a Turner syndrome or mixed gonadal dysgenesis phenotype, gonadoblastoma is more likely to occur. Studies by Tsuchiya *et al*,⁷ Petrovic *et al*,⁸ and Salo *et al*⁹ suggest that the gonadoblastoma susceptibility region of the Y chromosome is a 1-2 Mb region near the Y centromere. It is not clear whether this region near the Y chromosome centromere is on Yp or Yq. The detection of Y centromeric DNA either by FISH or PCR in these patients should serve as an adequate indication for removal of the dysgenetic gonadal tissue. In patients with a Turner syndrome phenotype, the presence of genital ambiguity should be assumed probably to represent gonadal mosaicism. The absence of sexual ambiguity in a patient with Turner syndrome is not a reliable indication of the lack of a second Y bearing cell line and risk for gonadoblastoma. Bisat *et al*¹⁰ reported such a patient whose lymphocytes were 45,X and SRY negative but whose gonadal tissue was SRY positive. We have observed a female with classical features of

Turner syndrome and no genital ambiguity whose lymphocytes were 50% 45,X and 50% 46,XY who, at 5 years of age, was found by laparoscopic surgery to have bilateral gonadoblastomas. While the two patients with an idic(Y) described in this report were phenotypically different, presumably reflecting the presence and absence of SRY, both are considered as being at increased risk for gonadoblastoma.

- 1 Shashi V, Golden WL, Allinson PS, Kelly TE. Molecular analysis of recombination in a family with a large pericentric X-chromosome inversion. *Am J Hum Genet* 1996;58:1231-8.
- 2 Kocova M, Siegel SF, Wenger SL, Lee PA, Nalesnik M, Trucco M. Detection of Y chromosome sequences in a 45,X/46,XXq- patient by Southern blot analysis of PCR-amplified DNA and fluorescent in situ hybridization (FISH). *Am J Med Genet* 1995;55:483-8.
- 3 Sugarman ID, Crolla JA, Malone PS. Mixed gonadal dysgenesis and cell line differentiation. Case presentation and literature review. *Clin Genet* 1994;46:313-15.
- 4 Fugimoto A, Boetler WD, Sparkes RS, Lin MS, Battersley K. Monozygotic twins of discordant sex both with 45,X/46,X,idic(Y) mosaicism. *Am J Med Genet* 1991;41:239-45.
- 5 Mendez JP, Ulloa-Aguirre A, Kofman-Alfaro S, *et al*. Mixed gonadal dysgenesis: clinical, cytogenetic, endocrinological and histopathological findings in 16 patients. *Am J Med Genet* 1993;46:263-7.
- 6 Hsu LY. Phenotype/karyotype correlations of Y chromosome aneuploidy with emphasis on structural aberrations in postnatally diagnosed cases. *Am J Med Genet* 1994;53:108-40.
- 7 Tsuchiya K, Reijo R, Page DC, Distchele CM. Gonadoblastoma: molecular definition of a susceptibility region on the Y chromosome. *Am J Hum Genet* 1995;57:1400-7.
- 8 Petrovic V, Nasioulas S, Chow CW, Voullaire L, Schmidt M, Dahl H. Minute Y chromosome derived marker in a child with gonadoblastoma: cytogenetic and DNA studies. *J Med Genet* 1992;29:542-6.
- 9 Salo P, Kaariainen H, Petrovic V, Peltomaki P, Page DC, de la Chapelle A. Molecular mapping of the putative gonadoblastoma locus on the Y chromosome. *Genes Chrom Cancer* 1995;14:210-14.
- 10 Bisat T, May K, Litmer S, Broeder B. Y chromosome mosaicism in the gonads, but not in the blood, of a girl with the Turner phenotype and virilized external genitalia. *Clin Genet* 1993;43:142-5.