

Mutations of PTEN in patients with Bannayan-Riley-Ruvalcaba phenotype

Michel Longy, Valérie Coulon, Bernadette Duboué, Albert David, Marc Larrègue, Charis Eng, Patrizia Amati, Jean-Louis Kraimps, Armand Bottani, Didier Lacombe, Dominique Bonneau

Abstract

We report three new mutations in PTEN, the gene responsible for Cowden disease in five patients with Bannayan-Riley-Ruvalcaba syndrome from three unrelated families. This finding confirms that Cowden disease, a dominant cancer predisposing syndrome, and Bannayan-Riley-Ruvalcaba syndrome, which includes macrocephaly, multiple lipomas, intestinal hamartomatous polyps, vascular malformations, and pigmented macules of the penis, are allelic disorders at the PTEN locus on chromosome 10q.

(*J Med Genet* 1998;35:886-889)

Keywords: Bannayan-Riley-Ruvalcaba syndrome; Cowden disease; PTEN

The term "Bannayan-Riley-Ruvalcaba" syndrome (BRR) (MIM 153480) has been proposed¹ to encompass three autosomal dominant conditions previously described as separate entities: Bannayan-Zonana, Riley-Smith, and Ruvalcaba-Myhre syndromes. Typical clinical features of BRR include macrocephaly, multiple lipomas, intestinal hamartomatous polyps, vascular malformations, and pigmented macules of the penis. At least half of the patients affected with BRR have hypotonia, delayed psychomotor development, mild to severe mental deficiency, and seizures.² BRR exhibits a number of clinical similarities to Cowden disease (CD), a dominant cancer predisposing syndrome, also known as multiple hamartoma syndrome. CD is characterised by mucocutaneous findings that include facial trichilemmomas, oral papillomatosis, and acral/palmoplantar keratosis. Patients with CD can also exhibit hamartomas in several organs and are at an increased risk for both thyroid and breast cancers, breast cancer developing in 20-25% of women and thyroid cancer in 3-10% of all affected subjects.³ In addition, about 25% of CD patients have lipoma and macrocephaly.² In contrast, hyperpigmented macules of the penis are rare in subjects with CD, having only been reported twice.⁴

Given the clinical similarities between these disorders, the idea of a possible common genetic pathogenesis between BRR and CD was previously put forward.⁴ Recently, mutations in the putative tumour suppressor gene PTEN, encoding a protein tyrosine phosphatase, were detected in patients with CD.^{5,6} Subsequently, Marsh *et al*⁷ discovered germline

mutations in PTEN in six BRR patients from two unrelated families, suggesting that CD and BRR are indeed allelic disorders.

In this paper, we report three new mutations in PTEN in five subjects with BRR from three unrelated, European families, confirming that mutations in PTEN result in both CD and BRR phenotypes.

Patients, materials, and methods

FAMILY A

Patient 1

The proband (III.3, fig 1), a 17 year old French male, was mildly mentally retarded and had enuresis and encopresis since early childhood. At the age of 15, a fibroscopic examination of the upper gastrointestinal tract showed multiple 0.5 to 5 mm polyps in the stomach which were hamartomatous on pathological examination. Colonoscopic examination was normal. At 17 years of age, physical examination showed macrocephaly (occipitofrontal circumference (OFC) 64 cm, >97th centile) and a vascular malformation of the right buttock, which on arteriography was shown to be a haemangioma. Mucocutaneous findings included multiple oral papillomas, 2 small café au lait macules, and multiple 1 to 5 mm pigmented macules on the glans and the shaft of the penis. A colonoscopic examination showed about 10 1 to 5 mm hamartomatous polyps in the rectum. Thyroid ultrasonography and scintigraphy were normal.

Patient 2

The father of the proband (II.2, fig 1) had a history of mild mental retardation, psychiatric disorder, and alcoholism. At the age of 41, he was obese and had an adenoid facies with macrocephaly (OFC 66 cm, >97th centile). Mucocutaneous examination showed multiple oral papillomas, multiple facial papules, palmar keratosis, and skin tags in the axillae and the right flank. He had no pigmented macules of the genitalia. A colonoscopic examination showed multiple polyps in the colon and in the

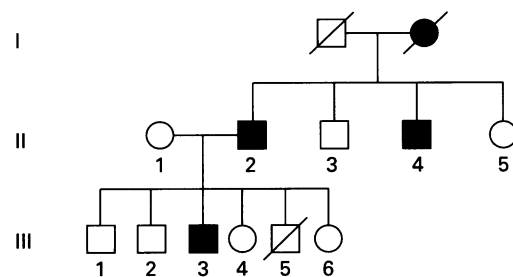


Figure 1 Pedigree of family A.

Laboratoire
d'Oncologie
Moléculaire, Institut
Bergonié, Bordeaux,
France
M Longy
V Coulon
B Duboué

Service de Pédiatrie et
Génétique, CHU
Nantes, France
A David

Services de
Dermatologie, de
Chirurgie
Endocrinienne et de
Génétique, CHU
Poitiers, France
M Larrègue
J-L Kraimps
P Amati
D Bonneau

Translational Research
Laboratory,
Department of Adult
Oncology, Human
Cancer Genetics Unit,
Dana-Farber Cancer
Institute, Harvard
Medical School,
Boston,
Massachusetts, USA
C Eng

Service de Génétique
Médicale, CHU
Bordeaux, France
D Lacombe

Division of Medical
Genetics, CMU,
Geneva, Switzerland
A Bottani

Correspondence to:
Dr Bonneau, Service de
Génétique, CHU de Poitiers,
BP 577, 86021 Poitiers
Cedex, France.

Received 10 February 1998
Revised version accepted for
publication 8 April 1998

rectosigmoid, which were found to be ganglioneuromatous on histological examination. There was no palpable thyroid tumour but scintigraphy showed a large multinodular endotheracic goitre. Hormonal testing showed an abnormal level of calcitonin after stimulation with pentagastrin (205 ng/l at five and 10 minutes, normal <10 ng/l), suggesting medullary carcinoma of the thyroid. The gland was surgically removed and histological examination showed features of both benign adenoma and C cell hyperplasia without any signs of medullary carcinoma. The subject's pentagastrin stimulated level of calcitonin was normal six months after the removal of the thyroid.

Patient 3

The paternal uncle of the proband (II.4, fig 1) also had a history of mental delay, psychiatric disorder, alcoholism, and seizures. At the age of 29, he had had a benign polyp removed from the stomach. An examination, when he was 37 years old, showed adenoid facies, macrocephaly (OFC 61 cm, >97th centile), and the same mucocutaneous findings as his brother (III.2). In addition, he had numerous 3 to 10 mm brown macules on the glans and the penile shaft. A colonoscopic examination showed four 1 to 2 mm hamartomatous polyps in the rectosigmoid. Thyroid ultrasonography and scintigraphy were normal.

Patient 4

It is noteworthy that the paternal grandmother of the proband (I.2, fig 1), who was dead at the time of the study, was probably affected with the disease. She was said to have had the same mucocutaneous lesions as her son (II.2) and she died at the age of 53 years of breast cancer and adenocarcinoma of the endometrium.

FAMILY B

Patient 1

The proband is a 24 year old French woman. Little is known about her family history. At 9 years of age, she had several lipomas excised from the nuchal region. At 19 years of age, a large juvenile polyp was removed from the colon. A year later, colonoscopic examination showed multiple polyps that were histologically diagnosed as ganglioneuromas. At 21 years of age, she had subcutaneous vascular malformations removed from the third finger of the right hand and from the right thigh and another lipoma was removed from the right clavicular region. At 24 years of age, she was noted to have macrocephaly (OFC 59.3 cm, >97th centile) and examination showed subcutaneous lipomas of the left ankle and multiple small lingual papillomas. She had normal intellect. Thyroid ultrasonography, thyroid scintigraphy, and mammography were normal.

Patient 2

The first son of the proband was born prematurely after 38 weeks of gestation. At birth, he weighed 2980 g. During his first year of life, weight and height followed the +2 SD curve. OFC was 49 cm (>97th centile) and 52.5 cm (>97th centile) at the ages of 7 and 15 months,

respectively. Cutaneous findings included one small café au lait macule on the right ankle and one achromic macule and two small verrucae vulgaris on the right leg. Early motor development was normal. This boy has not been tested for mutations in PTEN.

FAMILY C

The patient is the first of two boys born to healthy, non-consanguineous, Portuguese parents. At birth, the father was 29 years old and the mother 24. OFC of the father was 59 cm (97th centile) and that of the mother 57 cm (75th centile). His younger brother has no medical problems. A paternal uncle was said to have a unilateral congenital haemangioma of the leg, but no further details are available. Following an unremarkable pregnancy, the proband was born at term by spontaneous vaginal delivery. Birth weight was 4280 g (>90th centile), birth length 53 cm (50th-90th centile), and OFC 39.5 cm (>90th centile). A systolic heart murmur, first heard at the age of 1 month, led to the diagnosis of aortic stenosis at the age of 4 months. Psychomotor development was normal. Between 1 and 2 years of age, a soft tumour progressively developed over the mid back. At the time of surgical excision at the age of 3 years, it had reached a diameter of 13 cm. The lesion was a lipoma on histological examination. Another soft indolent mass in the right inguinal region was noted from the age of 9 years. Though there was no history of trauma, the patient started to complain at the age of 10½ years of limited extension of his right elbow. X rays and MRI examination were compatible with a lipoma, compressing the anterior brachial muscle. At the time of evaluation at the age of 11 years, weight was 40 kg (75th centile), height 151 cm (50th centile), and OFC 60.5 cm (>97th centile). There were no dysmorphic facial features. Heart auscultation indicated a 4/6 systolic murmur, maximal over the second right intercostal space and radiating over both carotid arteries. Apart from clinodactyly of the fifth fingers and the presence of brown macules on the penile shaft (but not on the glans), no other abnormal physical sign was noted. Peripheral blood karyotype was 46,XY. Tumours excised from both the right arm and right groin were again histologically diagnosed as lipomas. In addition, Doppler echocardiography showed a severely remodelled and anatomically tricuspid, but functionally bicuspid, aortic valve with a gradient of 60 mm Hg. Mild aortic incompetence was also present. Since his first year of life, the patient has carried the diagnosis of Beckwith-Wiedemann syndrome, despite the absence of cardinal features such as omphalocele, macroglossia, or neonatal hypoglycaemia. Based on the history of macrosomia and recurring lipomas, together with brown macules on the penile shaft, Bannayan-Riley-Ruvalcaba syndrome was finally diagnosed following genetic consultation at the age of 11 years.

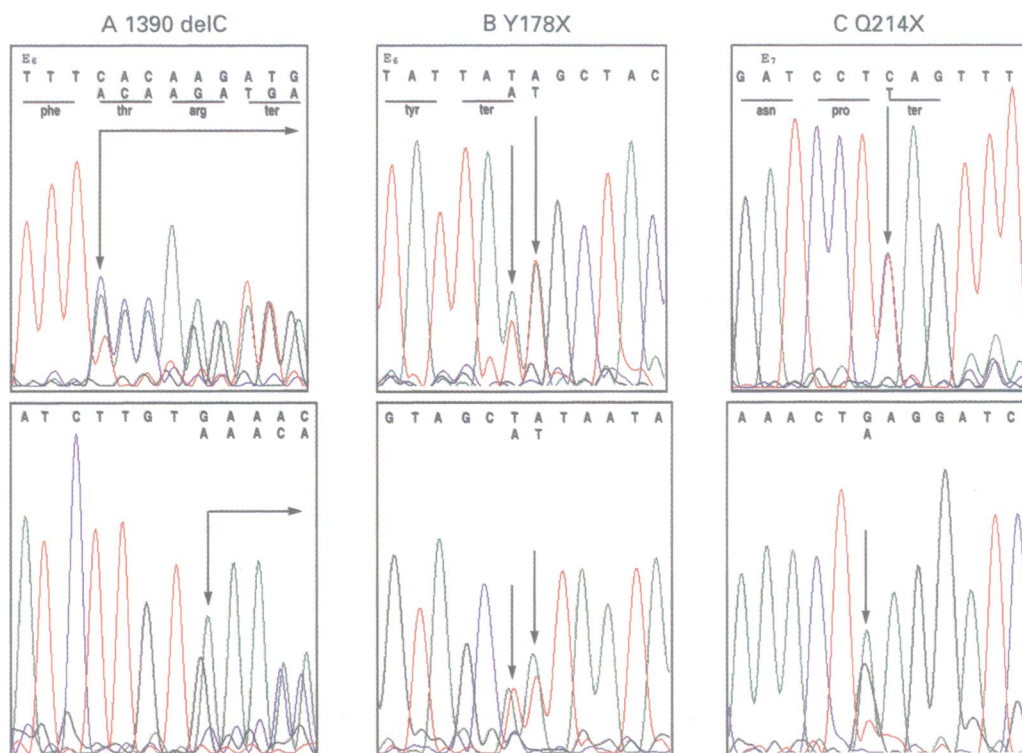


Figure 2 Electrophoretograms of nucleotide sequences showing the mutations detected in exons 6 (E6) and exon 7 (E7) of PTEN. Upper panel: forward strand, lower panel: reverse strand. (A) III.3 from family A. (B) Proband from family B. (C) Proband from family C.

MOLECULAR ANALYSIS

Genomic DNA was obtained from blood leucocytes using standard techniques. The nine exons of PTEN were amplified by using M13 tailed primers. All the primers were intronic except the forward primer for exon 8, corresponding to the 5' part of exon 8, because a poly T tract in the splice junction of intron 7 does not allow good quality sequence by dye primer technology. Products of amplification were purified by using the Wizard™ PCR purification system. Sequencing reactions were done directly from this purified, PCR amplified DNA with the ABI PRISM® dye primer cycle sequencing kit and run on an automated DNA sequencer, the ABI PRISM 377 from P E Applied Biosystem.

Results

In family A, a heterozygous deletion of a C at position 1390 in exon 6 was found in the three affected members tested (III.3, II.2, II.4). This frameshift mutation results in a premature stop at codon 198 (1390delC) (fig 2).

In family B, a heterozygous mutation in exon 6 was found in the proband. This mutation is a heterozygous pattern T/A for both nucleotides 1338 and 1339, probably corresponding to a small inversion of these nucleotides (1338invTA) and consequently results in a stop codon at position 178 (Y178X) (fig 2).

In family C, a heterozygous mutation in exon 7, 1444 C→T, was found in the proband. This mutation results in a premature stop at codon 214 (Q214X) (fig 2). Neither parent had evidence of the mutation, suggesting that the mutation in PTEN was de novo (the paternity was confirmed by DNA polymorphism analysis).

Discussion

In this paper we present three previously undescribed mutations of the putative tumour suppressor gene PTEN, the gene responsible for CD, in patients with the BRR phenotype, confirming that these diseases are allelic.⁷

In family A, the diagnosis of BRR was made in III.6 and II.4, given mild mental retardation, macrocephaly, vascular malformations, intestinal polyposis, and pigmented macules of the penis. However, the mucocutaneous features and the thyroid involvement of patient II.2 were more suggestive of CD. The coexistence of features common in CD and BRR within the same family has already been pointed out by Fargnoli *et al.*,⁴ who hypothesised that these disorders might have a common genetic origin. In contrast, the diagnosis of BRR was unambiguous in families B and C. The proband in family B had macrocephaly, digestive tract polyposis, subcutaneous lipomatosis, and only mild lingual papillomatosis. In this patient, thyroid and breast examinations were normal and there were neither the facial nor acral cutaneous features typically found in CD. Similarly, the clinical features of the proband from family C were also characteristic of BRR.

Previous reports have now shown that CD and BRR are allelic disorders at the PTEN locus on chromosome 10q. PTEN, which stands for "phosphatase and tensin homologue deleted on chromosome 10", is a putative tumour suppressor gene which has been recently cloned⁸ from a region of the chromosome 10 frequently deleted in glioblastomas, advanced prostate cancers,⁹ and thyroid tumours.¹⁰ The same gene was independently isolated by Steck *et al.*¹¹ (who referred to it as

Table 1 PTEN mutations in Bannayan-Riley-Ruvalcaba syndrome

Mutations	Exon	References
M233X	7	7
S170R	6	7
N196N	6	7
Y68H	3	14
S170R	6	14
c.520-544del	6	14
R233X	7	14
1390delC	6	Family A
Y178X	6	Family B
Q214X	7	Family C

MMAC1 for "mutated in multiple advanced cancers 1") and by Li and Sun¹² (who named it TEP1 for "TGF β regulated and epithelial cell enriched phosphatase"). PTEN encodes a protein with both a tyrosine phosphatase domain and a large region of homology to both chicken tensin (a protein that interacts with actin filaments at focal adhesions) and bovine auxilin. Somatic mutations in PTEN have been detected in glioblastoma, sporadic breast cancer, prostate cancer, and endometrial carcinoma.^{11,13} Subsequently, germline mutations in PTEN were identified in patients affected with CD^{5,6} and with BRR.^{7,14}

So far (including the three mutations presented here), seven different germline point mutations have been found in subjects affected with BRR from unrelated families (table 1). In addition, an interstitial deletion at 10q23-q24 leading to the complete allelic loss of PTEN has also been reported in a 18 month old boy with a BRR phenotype.¹⁵

Interestingly, four out of the seven point mutations discovered in BRR patients result in a truncated protein, indicating that the molecular defect responsible for BRR corresponds to an inactivating mutation.

Also worthy of note, four BRR mutations occur in exon 6 of PTEN while two mutations occur in exon 7. In typical CD, by contrast, the mutations are spread over the entire gene with the exception of exons 1, 4, and 9.¹⁴ Further studies of patients affected with BRR will show whether mutations in exon 6 preferentially result in this phenotype. It must be noted, however, that at least three different mutations in exon 6 have been observed in patients affected with typical CD^{6,14} and that a mutation (R233X) has been reported in two independent families, one affected with CD and the other with BRR.⁷ It is therefore expected that no clear phenotype-genotype correlation will be made. It is noteworthy, however, that none of the mutations responsible for BRR has been found so far in exon 5, the site of the phosphatase domain of the PTEN protein.

In conclusion, the three new mutations found in PTEN in patients with BRR syndrome confirm that CD and BRR, long

considered as separate entities, are allelic. Furthermore, as the features of both diseases can in childhood be limited to macrosomia/macrocephaly with or without mental retardation, it now seems important to screen patients presenting with these clinical signs for PTEN mutations. Finally, as one affected subject from a family reported in this paper died of breast and endometrial cancer, it may be warranted to consider BRR as a disorder also predisposing to cancer and to follow these patients accordingly in adulthood.

Note added in proof

Since the submission of this manuscript, we have studied another patient affected with BRR. Briefly, this 2 year old boy had mild psychomotor retardation and macrocephaly (55 cm, +4.5 SD). He had two subcutaneous lipomas but no pigmented macule of the penis. Molecular analysis showed a de novo mutation in exon 7 of PTEN (1570G→T) resulting in a codon stop at position 256 (E256X).

This work was supported by "La Ligue Nationale Française Contre le Cancer et les Comités Départementaux de la Corrèze et de la Gironde de la Ligue Contre le Cancer". We are grateful to Dr Celia DeLozier-Blanchet for useful advice and discussion.

- Cohen MM. Bannayan-Riley-Ruvalcaba syndrome: renaming three formerly recognized syndromes as one etiologic entity. *Am J Med Genet* 1990;35:291.
- Starink TM, Van der Arwert JPW, De Waal LP, De Lange GG, Gille JJP, Eriksson AW. The Cowden syndrome: a clinical and genetic study in 21 patients. *Clin Genet* 1986;29:222-33.
- Eng C. Cowden syndrome. *J Genet Counsel* 1997;6:181-91.
- Fargnoli MC, Orlow SJ, Semel-Concepcion J, Bologna JL. Clinicopathologic findings in the Bannayan-Riley-Ruvalcaba syndrome. *Arch Dermatol* 1996;132:1214-18.
- Liaw D, Marsh DJ, Li J, et al. Germline mutations of the PTEN gene in Cowden disease, an inherited breast and thyroid cancer syndrome. *Nat Genet* 1997;16:64-7.
- Nelen MR, van Staveren WC, Peeters EA, et al. Germline mutations in the PTEN/MMAC1 gene in patients with Cowden disease. *Hum Mol Genet* 1997;6:1383-7.
- Marsh DJ, Dahia PLM, Zheng Z, et al. Germline mutations in PTEN are present in Bannayan-Zonana syndrome. *Nat Genet* 1997;16:333-4.
- Li J, Yen C, Liaw D, et al. PTEN, a putative protein tyrosine phosphatase gene mutated in human brain, breast, and prostate cancer. *Science* 1997;275:1943-6.
- Ittman M. Allelic loss on chromosome 10 in prostate adenocarcinoma. *Cancer Res* 1996;56:2143-7.
- Marsh DJ, Zheng Z, Zedenius J, et al. Differential loss of heterozygosity in the region of the Cowden locus within 10q22-q23 in follicular thyroid adenoma and carcinomas. *Cancer Res* 1997;57:500-3.
- Steck PA, Pershouse MA, Jasser SA, et al. Identification of a candidate tumour suppressor gene, MMAC1, at chromosome 10q23.3 that is mutated in multiple advanced cancers. *Nat Genet* 1997;15:356-62.
- Li DM, Sun H. TEP1, encoded by a candidate tumor suppressor locus, is a novel protein tyrosine phosphatase regulated by TGF β . *Cancer Res* 1997;57:2124-5.
- Kong D, Suzuki A, Zou TT, et al. PTEN1 is frequently mutated in primary endometrial carcinomas. *Nat Genet* 1997;17:143-4.
- Marsh DJ, Coulon V, Lunetta KL, et al. Mutation spectrum and genotype-phenotype analyses in Cowden disease and Bannayan-Zonana syndrome, 2 hamartoma syndromes with germline PTEN mutation. *Hum Mol Genet* (in press).
- Arch EM, Goodman BK, Van Wesep RA, et al. Deletion of PTEN in a patient with Bannayan-Riley-Ruvalcaba syndrome suggests allelism with Cowden disease. *Am J Med Genet* 1997;71:489-93.