

## Genetic counselling in hereditary osteo-onychodysplasia (HOOD, nail-patella syndrome) with nephropathy

B J LOOIJ JR\*, R L TE SLAA†, B L HOGEWIND\*, AND  
J J P VAN DE KAMP‡

From the Departments of Nephrology\* and Clinical Genetics‡, University Hospital, Rijnsburgerweg, 2333 AA Leiden; and †the Department of Orthopaedic Surgery, St Joseph's Hospital, Aalsterweg, 5644 RC Eindhoven, The Netherlands.

**SUMMARY** Hereditary osteo-onychodysplasia (HOOD, nail-patella syndrome) is an autosomal dominant condition characterised by nail dysplasia, patellar hypoplasia or aplasia, and nephropathy. The risk for HOOD patients to have a child with HOOD who will develop renal failure cannot easily be deduced from published pedigrees. We have studied a large family with 30 patients with HOOD and have analysed 34 kindreds with HOOD nephropathy from published reports, comprising 213 patients. For a patient with HOOD from a family in which HOOD nephropathy occurs, the risk of having a child with HOOD nephropathy is about 1:4; the risk of having a child in whom renal failure will develop is about 1:10.

Hereditary osteo-onychodysplasia (HOOD), also known as nail-patella syndrome, is an autosomal dominant hereditary disease. The gene locus is assigned to the distal end of the long arm of chromosome 9,<sup>1</sup> linked to the ABO blood group locus,<sup>2,3</sup> with an estimated recombination rate of 10 to 15%.<sup>4</sup>

Nail dysplasia and patellar hypoplasia or aplasia are essential features for the diagnosis. Other diagnostic signs are arthrodysplasia of the elbows, leading to increased carrying angle and limited supination and extension, and iliac horns, which are pathognomonic but reported to be present in only 70% of cases.<sup>5</sup> Numerous other skeletal abnormalities have been described in patients with HOOD, but either the incidence of each of them is low or they are easily overlooked. The skeletal deformities are not usually incapacitating. Nephropathy may be the most serious complication in some families, but it does not occur in all families with HOOD; several large HOOD kindreds have been reported in which nephropathy does not occur (HOOD/NP-kindreds), for example, as described by Ter Haar and Van Dam.<sup>5</sup> When present, HOOD nephropathy may manifest itself with asymptomatic proteinuria only for many years, but end stage renal

failure is well known to occur. The incidence of nephropathy is reported in different reviews to be 30 to 55%,<sup>6-8</sup> depending on the population and the criteria for nephropathy. However, in families in which HOOD nephropathy occurred (HOOD/NP+ families), the typical ultrastructural abnormality (irregular thickening of the glomerular basement membrane and presence of fibrillar, collagen-like material within it, and fusion of epithelial foot processes) was present in all renal biopsies, even from those without any detected abnormality of renal function.<sup>6,9,10</sup> In contrast, no ultrastructural abnormality was found in a renal biopsy from a sib without HOOD.<sup>6</sup> We are not aware of any electron microscopic data on renal tissue of patients with HOOD from families in which the nephropathy does not occur (HOOD/NP- families), except possibly for the patient reported by Silverman *et al.*<sup>11</sup> They found the typical ultrastructural lesions in a woman with HOOD without proteinuria or renal insufficiency, belonging to an apparently HOOD/NP- family. On the other hand, the typical renal lesions are probably not specific for HOOD.<sup>12,13</sup> Light microscopic and immunofluorescent findings in renal biopsies from HOOD/NP+ patients vary. It is not known what determines the clinical course of the nephropathy, nor why nephropathy occurs in some kindreds with HOOD but not in others.

**Case report**

The proband was a 25 year old affected female member of a HOOD/NP+ family (figure), who had had documented asymptomatic proteinuria from the age of four years. After her first pregnancy, which terminated with an intrauterine death at 27 weeks, renal function deteriorated gradually, progressing to end stage renal failure in two years. At the age of 22 years she started on chronic intermittent haemodialysis. She received a cadaveric renal allograft one and a half years later, in October 1982, which is still functioning well. She has dysplastic fingernails and toenails, hypoplastic patellae, and iliac horns.

The skeletal deformities presented no major clinical problem in her family.<sup>14</sup> As she would not accept a substantial risk of her children developing renal failure, especially at a young age, she requested genetic counselling. As shown in the pedigree, three of her mother's sibs also required treatment for end stage renal failure, while others, including her mother, showed persistent proteinuria.

**Methods**

The proband has been treated at our institution from the time of her renal transplant. She provided us with the first outline of the pedigree. Twenty-two members of her family with HOOD consented to an interview and orthopaedic examination, and all except two also to urine analysis. Proteinuria indicating HOOD nephropathy was considered to

be present when protein excretion on several occasions exceeded 0.2 g/l or 0.15 g/day in the absence of leucocyturia and haematuria.

Our data were supplemented by those of general practitioners and attending specialists for three affected family members we could not examine ourselves. We could not obtain information on the renal status of five dead family members with HOOD.

Apart from the pedigree of our proband, we analysed the pedigrees of 34 HOOD/NP+ families published in the last 35 years.<sup>3 6 8-10 15-40</sup> As the risk of renal failure in our patient's offspring could not readily be deduced from these pedigrees, we approached the answer to her question by trying to answer the following three questions first.

- (1) How many patients with HOOD from HOOD/NP+ families also have nephropathy (defined as persistent proteinuria or renal failure)?
- (2) How many of these patients develop end stage renal failure and at what age?
- (3) Does nephropathy in a parent increase the risk of nephropathy for the child?

The final question was

- (4) Does renal failure in a parent increase the risk of renal failure for the child and, if so, at what age is renal failure likely to occur?

Frequencies were calculated for the family of our patient as well as for all the published HOOD/NP+ families on which the necessary data could be found. Most of the patients reviewed by Carbonara and

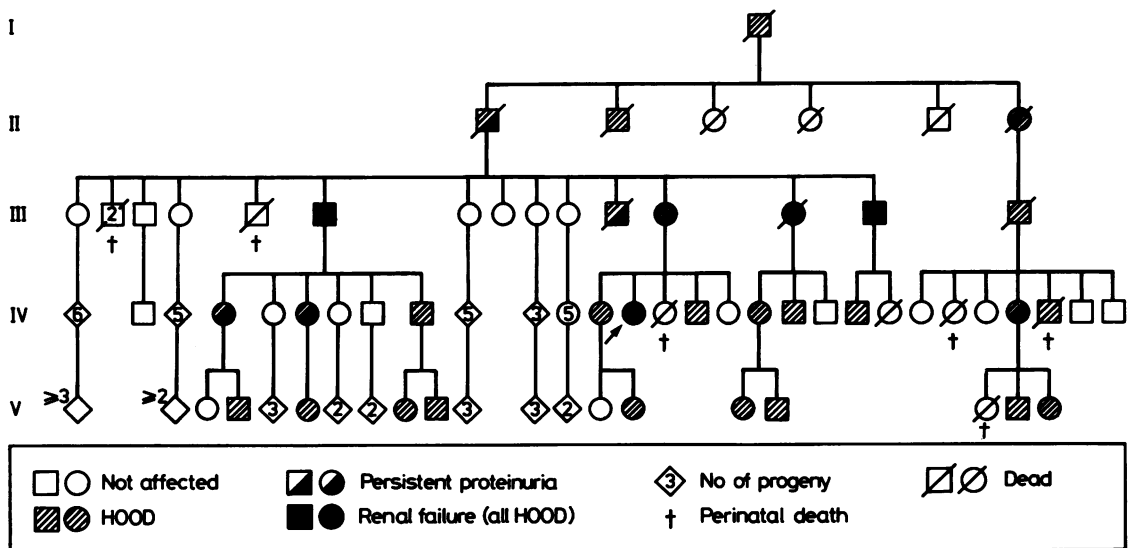


FIGURE Pedigree of HOOD family.

Alpert<sup>7</sup> are not considered here, because it is not possible to tell how many came from HOOD/NP+ families from their data. The family described by Isoda *et al*<sup>41</sup> was not included either, because in this family the syndrome was incomplete (nail dysplasia without skeletal abnormalities). All HOOD/NP+ families from the families reviewed by Similä *et al*<sup>8</sup> are included.

## Results

Neither the pedigree of our patient's family nor the pedigrees of 34 published HOOD/NP+ families showed a consistent pattern of inheritance of the nephropathy, but nephropathy was not found in the absence of HOOD, with one doubtful exception.<sup>29</sup> Regarding the questions formulated above, the following frequencies could be calculated.

- (1) Nephropathy occurred in 10/23 (43%) of patients with HOOD on which the relevant data could be obtained in the family of our patient, and in 104/213 (49%) of patients with HOOD from HOOD/NP+ families reported, assuming that subjects who were not examined did not have nephropathy.
- (2) To date, end stage renal failure has occurred in four out of the 26 (15%) HOOD members of our patient's family in which this could be assessed with certainty, that is, 4/10 (40%) of HOOD/NP+ patients. Our patient was one of these four and they required replacement of renal function at a mean age of 44 years. Among the other 34 HOOD/NP+ families end stage renal failure occurred in 29/213 (14%) of HOOD patients, that is, 29/104 (28%) of HOOD/NP+ patients. This happened at a mean age of 33 (SD 18) years (in two patients the age at renal failure was not given).
- (3) The family of our patient contains eight HOOD/NP+ parents and 18 of their 37 (49%) children had HOOD. Eight of these 18 children (44%) also had nephropathy. In the published reports, 172 to 183 children of 39 to 43 HOOD/NP+ parents were described (data were not always complete); 100 to 113 of these children had HOOD and 54 to 64 (48 to 62%) also had nephropathy. The data on the children of the 31 to 40 HOOD/NP- parents were not given in sufficient detail to allow separate analysis.
- (4) Among 10 HOOD/NP+ families from published reports, 54 children of patients with HOOD and renal failure were found, 34 (63%) of whom had HOOD. Six (18%) of these HOOD children were reported to have

HOOD and also developed renal failure at the ages of 47, 52,<sup>17 18</sup> 14, 31,<sup>6 25</sup> 13, and 29<sup>37</sup> years, respectively. In our patient's family this has not yet occurred.

## Discussion

Combining the data from our patient's family with those from published reports, we found that nephropathy occurred in 114/236 (48%) and renal failure in 33/239 (14%) of patients with HOOD. Similarly, nephropathy occurred in 62 to 72 (47 to 59%) of 118 to 131 children with HOOD from HOOD/NP+ parents, and renal failure occurred in 6/40 (15%) of HOOD children from parents with HOOD and renal failure, so that neither nephropathy nor renal failure in the parent seems to increase significantly the risk of the same condition in the child. As HOOD is a regular autosomal dominant condition, for a parent with HOOD from a HOOD/NP+ family, the risk of having a child who will develop nephropathy is calculated at 24%, and the risk of having a child in whom renal failure will occur at 7%. However, these figures should be used with caution, as there are four sources of bias.

(1) INTERPRETATION OF PUBLISHED REPORTS  
Earlier reviews contain cases from HOOD/NP- families, leading to an underestimate of the risk of nephropathy. Why nephropathy occurs in some kindreds but not in others is unknown. Some think it is the result of differences in expression (and the report by Silverman *et al*<sup>11</sup> may support such a view), but it could just as well result from different alleles. Therefore, HOOD/NP- kindreds were excluded from the present study. This explains our finding of a considerably higher prevalence of nephropathy among patients with HOOD (48%) than the 30% reported by Similä *et al*.<sup>8</sup> Recalculation after exclusion of HOOD/NP- families from their material yields a prevalence of 53/116 (46%). Carbonara and Alpert<sup>7</sup> found a frequency of proteinuria of 12/29 (41%) in their review, but they may also have included data from HOOD/NP- families. Our own estimate is conservative in assuming that 44 subjects who were not examined did not have nephropathy; if this proved to be incorrect, the frequency could maximally increase to 158/236 (67%).

## (2) SELECTION OF CASES REPORTED

Kindreds in which nephropathy was not noteworthy, either in frequency or clinical significance, may not be reported or may even go unrecognised, so that published reports may be biased towards the more severely affected families. We have noted large

differences in the prevalence of nephropathy among the HOOD/NP+ families reported: the proportion of patients with HOOD that also had nephropathy ranged from 11 to 100%. The smaller families published tend to have more HOOD/NP+ members relative to the number of HOOD/NP- members. We doubt if the large differences in prevalence are merely the result of differences in the extent to which the kindreds were examined or due to sampling. The observed frequency of HOOD in children of HOOD/NP+ parents from published reports, which was about 60% instead of 50%, supports our supposition that selection has also influenced the observed frequency of HOOD nephropathy among children of HOOD/NP+ parents, which was about 27% instead of 24% as would be predicted from the overall prevalence of nephropathy (48%) among HOOD patients. However, we cannot rule out the possibility that nephropathy in a parent increases the risk of nephropathy in a child.

### (3) AGE OF THE PATIENTS STUDIED

Some patients with HOOD from HOOD/NP+ families will develop clinically detectable nephropathy only after the study. As no preferential age of onset of the nephropathy is apparent, this applies especially to the younger members of a family. This leads to an underestimate of the risk of nephropathy, as may well have occurred in the family of our patient, in which seven of the nine members with HOOD in the fifth generation are less than 11 years of age at present. Omitting this last generation would increase the frequency of nephropathy among family members with HOOD from 43 to 71% (10/14). The only way to circumvent this problem is to follow up kindreds described earlier, as was done by Schröder,<sup>16</sup> who provided valuable additional information on the kindred described by Kieser,<sup>15</sup> and by Darlington and Hawkins,<sup>18</sup> who provided some extra data on the kindred described by Hawkins and Smith.<sup>17</sup> In fact, Kieser<sup>15</sup> found nephropathy in 7/10 HOOD members of the kindred he described, while Schröder found it in 13/15 HOOD members of the same kindred, thus raising the frequency of nephropathy from 70 to 87%. However, this type of study is rarely feasible, as other publications in this category could not be found. Today, the most promising approach to this problem would be centralised electronic storage of files, with regular follow up enquiries entered automatically.

### (4) SIZE OF THE MOST RELEVANT SUBGROUP

The subgroup on which the data are most pertinent to genetic counselling, that is, the children of those

HOOD/NP+ patients who develop renal failure, is only small. There are two reasons for this: the incidence of renal failure in patients with HOOD is not high, and until recently, procreation after development of renal failure was virtually impossible. With the introduction of the various forms of renal function replacement therapy, the prognosis of HOOD patients with end stage renal failure has improved dramatically, and since procreation is possible after successful renal transplantation, the demand for genetic counselling is expected to increase, especially in this group of patients.

The authors gratefully acknowledge the help they received from patients, their general practitioners, and their attending specialists in collecting the data for this study.

### References

- Ferguson-Smith MA, Aitken DA, Turleau C, de Grouchy J. Localisation of the human ABO:Np-1:AK-1 linkage group by regional assignment of AK-1 to 9q34. *Hum Genet* 1976;**34**: 35-43.
- Renwick JH, Lawler SD. Genetical linkage between the ABO and nail-patella loci. *Ann Hum Genet* 1955;**19**:312-31.
- Jameson RJ, Lawler SD, Renwick JH. Nail-patella syndrome: clinical and linkage data on family G. *Ann Hum Genet* 1956;**20**:348-60.
- Schleutermann DA, Bias WB, Murdoch JL, McKusick VA. Linkage of the loci for the nail-patella syndrome and adenylate kinase. *Am J Hum Genet* 1969;**21**:606-30.
- Ter Haar BG, Van Dam FE. Het nagel-patellasyndroom of de hereditaire onycho-osteo-arthrodysplasie. *Ned Tijdschr Geneeskd* 1972;**116**:2218-27.
- Bennett WM, Musgrave JE, Campbell RA, et al. The nephropathy of the nail-patella syndrome—clinicopathologic analysis of 11 kindred. *Am J Med* 1973;**54**:304-19.
- Carbonara P, Alpert M. Hereditary osteo-onycho-dysplasia (HOOD). *Am J Med Sci* 1964;**248**:139-51.
- Similä S, Vesa L, Wasz-Höckert O. Hereditary onycho-osteodysplasia (the nail-patella syndrome) with nephrosis-like renal disease in a newborn boy. *Pediatrics* 1970;**46**:61-5.
- Hoyer JR, Michael AF, Vernier RL, Sisson S. Renal disease in nail-patella syndrome: clinical and morphological studies. *Kidney Int* 1972;**2**:231-8.
- Pussell BA, Charlesworth JA, Macdonald GJ, Baker W de C. The nail-patella syndrome—a report of a family. *Aust N Z J Med* 1977;**7**:20-3.
- Silverman ME, Goodman RM, Cuppage FE. The nail-patella syndrome. *Arch Intern Med* 1967;**120**:68-74.
- Dombros N, Katz A. Nail patella-like renal lesions in the absence of skeletal abnormalities. *Am J Kidney Dis* 1982;**1**: 237-40.
- Salcedo JR. An autosomal recessive disorder with glomerular basement membrane abnormalities similar to those seen in the nail patella syndrome: report of a kindred. *Am J Med Genet* 1984;**19**:579-84.
- Te Slaa RL, Looij BJ Jr, Nollen AJG, Lommen EJP. A family with hereditary onycho-osteodysplasia. De hereditaire onycho-osteodysplasie (HOOD). *Ned Tijdschr Kindergeneeskd* (in press).
- Kieser W. Die sog. Flughaut beim Menschen—ihre Beziehung zum Status dysraphicus und ihre Erbllichkeit (dargestellt an der Sippe Fr.). *Z Menschl Vererb Konstit Lehre* 1939;**23**:594-619.
- Schröder G. Osteo-onycho-dysplasia hereditaria (albuminurica)—

- Literaturbericht und Einordnung einer Sippe in dieses Missbildungssyndrom. *Z Menschl Vererb Konstit Lehre* 1961;**36**:42-73.
- <sup>17</sup> Hawkins CF, Smith OE. Renal dysplasia in a family with multiple hereditary abnormalities including iliac horns. *Lancet* 1950;**i**:803-8.
- <sup>18</sup> Darlington D, Hawkins CF. Nail-patella syndrome with iliac horns and hereditary nephropathy—necropsy report and anatomical dissection. *J Bone Joint Surg [Br]* 1967;**49**:164-74.
- <sup>19</sup> Brixey AM Jr, Burke RM. Arthro-onychodysplasia—hereditary syndrome involving deformity of head of radius, absence of patellas, posterior iliac spurs, dystrophy of finger nails. *Am J Med* 1950;**8**:738-44.
- <sup>20</sup> Gibbs RC, Berczeller PH, Hyman AB. Nail-patella-elbow syndrome. *Arch Dermatol* 1964;**89**:196-9.
- <sup>21</sup> Pillay VK. Onycho-osteodysplasia (nail-patella syndrome)—study of a Chinese family with this condition. *Ann Hum Genet* 1965;**28**:301-7.
- <sup>22</sup> Muth RG. The nephropathy of hereditary osteo-onychodysplasia. *Ann Intern Med* 1965;**62**:1279-85.
- <sup>23</sup> Leahy MS. The hereditary nephropathy of osteo-onychodysplasia—nail-patella syndrome. *Am J Dis Child* 1966;**112**:237-41.
- <sup>24</sup> Beyer P, Girard J, Izsepy E, Ritzenthaler C. Ostéo-onycho-dysplasie héréditaire (onycharthrose)—étude de 5 cas familiaux avec atteinte musculaire associée. *Strasbourg Med* 1967;**18**:675-89.
- <sup>25</sup> Beals RK, Eckhardt AL. Hereditary onycho-osteodysplasia (nail-patella syndrome). *J Bone Joint Surg [Am]* 1969;**51**:505-16.
- <sup>26</sup> Wright LA, Fred HL. Fatal renal disease associated with hereditary osteo-onycho-dysplasia. *South Med J* 1969;**62**:833, 842.
- <sup>27</sup> Bazinet P, Krasner P, Duckett S, Lasker N. Renal abnormality in the nail-patella syndrome. *Ann Intern Med* 1970;**72**:804A.
- <sup>28</sup> Ben-Bassat M, Cohen L, Rosenfeld J. The glomerular basement membrane in the nail-patella syndrome. *Arch Pathol* 1971;**92**:350-5.
- <sup>29</sup> Manigand G, Auzepy P, Paillas J, Cohen de Lara A, Deparis M. Ostéo-onycho-dysplasie avec néphropathie—étude anatomoclinique. *Sem Hop Paris* 1971;**47**:2949-56.
- <sup>30</sup> Morita T, Laughlin LO, Kawano K, Kimmelstiel P, Suzuki Y, Churg J. Nail-patella syndrome—light and electron microscopic studies of the kidney. *Arch Intern Med* 1973;**131**:271-7.
- <sup>31</sup> Eisenberg KS, Potter DE, Bovill EG Jr. Osteo-onychodystrophy with nephropathy and renal osteodystrophy—a case report. *J Bone Joint Surg [Am]* 1972;**54**:1301-5.
- <sup>32</sup> Valdueza AF. The nail-patella syndrome—a report of three families. *J Bone Joint Surg [Br]* 1973;**55**:145-62.
- <sup>33</sup> Vernier RL, Hoyer JR, Michael AF. The nail-patella syndrome—pathogenesis of the kidney lesion. *Birth Defects* 1974;**X**:57-9.
- <sup>34</sup> Uranga VM, Simmons RL, Hoyer JR, Kjellstrand CM, Buselmeier TJ, Najarian JS. Renal transplantation for the nail-patella syndrome. *Am J Surg* 1973;**125**:777-9.
- <sup>35</sup> Huriet C, Kessler M, Guittienne B, Maurice F, Rauber G. Ostéo-onycho-dysplasie héréditaire, syndrome d' Osterreich-Turner avec atteinte rénale. *J Urol Nephrol* 1977;**83**:273-8.
- <sup>36</sup> Carrera Carbo F, Del rio Vazquez A, Arcocha Gilo V, Marco Franco J, Romero Burgos R, Vidal Carreira J. Insuficiencia renal crónica como manifestación de ósteo-ónico-displasia hereditaria. *Rev Clin Esp* 1977;**147**:645-7.
- <sup>37</sup> Kuroda M, Akiyama T, Otani I, et al. Renal disease in the nail-patella syndrome: report of an affected family and studies of renal disease susceptibility and HLA. *Nippon Jinzo Gakkai Shi* 1978;**20**:909-20.
- <sup>38</sup> Myers HS, Gregory M, Beighton P. Renal failure in a 44 year-old female. *Urol Radiol* 1980;**1**:251-3.
- <sup>39</sup> Verdich J. Nail-patella syndrome associated with renal failure requiring transplantation. *Acta Derm Venereol (Stockh)* 1980;**60**:440-3.
- <sup>40</sup> Strada U, Morisi R. La osteo-onico-distrofia ereditaria—studio su un ceppo familiare affetto. *Chir Ital* 1981;**33**:88-96.
- <sup>41</sup> Isoda K, Shishiido H, Nakazawa R, Tateno S, Hamaguchi K. A case of nail-patella syndrome presenting a steroid resistant nephrotic syndrome—in reference to clinical and morphological study. *Nippon Jinzo Gakkai Shi* 1985;**27**:409-17.

Correspondence and requests for reprints to Dr B J Looij Jr, Department of Endocrinology, Geb 1, C4-R, Academisch Ziekenhuis, Rijnsburgerweg 10, 2333 AA Leiden, The Netherlands.