

Autosomal dominant isolated ('uncomplicated') microcephaly

PAUL MERLOB, DAVID STEIER, AND SALOMON H REISNER

From the Neonatology Department, Beilinson Medical Centre, Petah Tiqva and Tel Aviv University Sackler School of Medicine, Israel.

SUMMARY A large family (13 affected members in three generations) is reported in which isolated microcephaly occurred without any other dysmorphic or neurological abnormalities. The family pedigree confirms the autosomal dominant mode of inheritance with incomplete penetrance, including one example of male to male transmission and the occurrence of a non-manifesting heterozygote resulting in a 'skipped generation'.

There is considerable variation in the phenotypic expression of autosomal dominant microcephaly. This isolated (uncomplicated) type of microcephaly should be distinguished from other well defined, dominantly inherited forms of microcephaly.

Microcephaly strictly means abnormally small head size, but usually refers to an occipitofrontal head circumference below -2 SD from the mean for the infant's gestational age, sex, and ethnic origin.^{1,2} Microcephaly may appear as an isolated trait or in association with other malformations. It may also be sporadic or familial. Most cases of familial microcephaly appear to be inherited in an autosomal recessive fashion.³ Only 17 families in whom microcephaly was transmitted as an autosomal dominant trait have been reported.^{4–11} Six of them were reported recently¹¹ as an extension of a previously described family.⁶ We wish to present the largest family (13 affected members) in whom isolated microcephaly appears to be inherited in an autosomal dominant fashion and to distinguish clearly this form of 'pure' microcephaly (without mental retardation or other anomalies) from the other well-defined dominantly inherited types of microcephaly.

Case reports

The family pedigree is shown in fig 1. The proband (III.9) was born in 1986 after a normal pregnancy and delivery to a 27 year old, G2, P2, healthy mother and a 31 year old healthy father. There was no history of any medication, x ray examinations, alcohol intake, or smoking during pregnancy. Physical examination at birth revealed a healthy male infant with a birth weight of 2580 g, length 46

cm, and head circumference 31 cm. All these measurements were below -2 SD in accordance with Usher's curves¹² and also in comparison with our own curves.¹³ His head was normally shaped with normal fontanelles and sutures. This symmetrical, small for dates infant with microcephaly and short birth length had no other abnormalities. The following investigations were normal: complete blood count, glucose, calcium, phosphate, magnesium, electrolytes, T4, TORCH titres, examination of the optic fundi, urine analysis, urine chromatography for amino acids and sugars, skull x ray, and brain ultrasound.

The distribution of the head circumference measurements for all the members of the affected family is illustrated in fig 2. Only seven members of this family (six females and one male) had a head circumference at, or a little above, the mean for their age; the other 18 were situated between the mean and -2 SD for age. The distribution of head circumference measurements for the 13 microcephalic patients was as follows: one at -3 SD, three at -2.8 SD, five at -2.5 SD, and four at -2.2 SD.

Three cousins of the proband (III.23, III.25, III.30) also had isolated microcephaly. Another three cousins (III.11, III.22, and III.26) had borderline head circumferences (at -2 SD for age). The father of the proband (II.13), his two brothers (II.14 and II.21), his five sisters (II.16, II.17, II.18, II.20, II.22), and their mother (I.3) all had microcephaly without any other abnormalities. The proband's father, who works as a typesetter, discontinued his

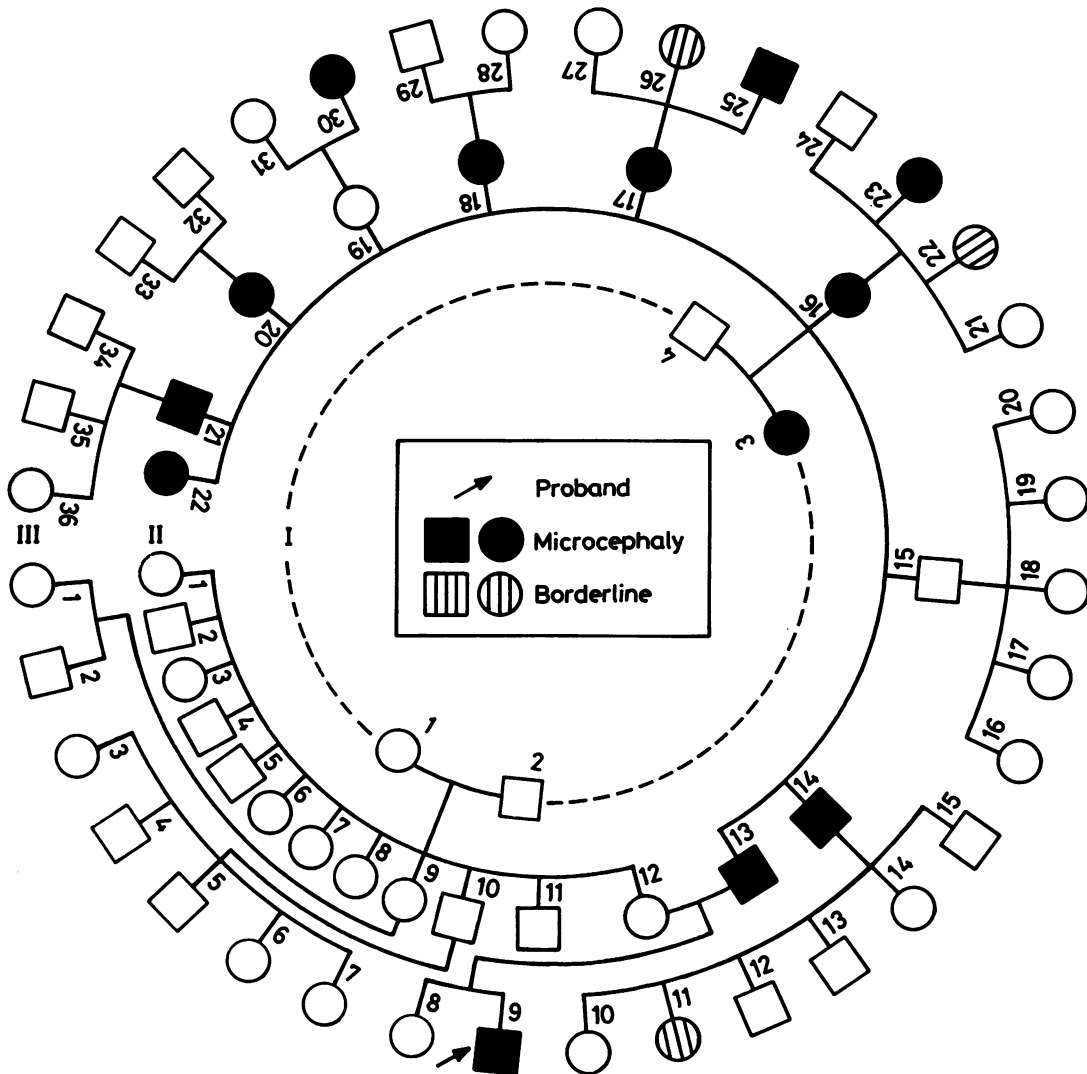


FIG 1 The pedigree of a family with autosomal dominant isolated microcephaly.

high school education at the 12th grade. He was found to be of normal intelligence as were all the other family members. None had any obvious neurological dysfunction, history of seizures, or ophthalmological problems.

The proband's mother and her family were healthy with normal head circumferences and without any abnormalities. Follow up of the proband at the age of 12 months showed a normal infant with weight and length at the 10th centile, a head circumference (43.3 cm) below -2 SD, and a

Denver Development Screening Test within the normal age range.

Discussion

Congenital microcephaly may be an isolated trait, associated with other malformations, or syndromic. Isolated microcephaly, also known as 'true' or 'pure' microcephaly, is defined as a small head circumference without other congenital malformations.¹ Isolated microcephaly is either sporadic or familial.

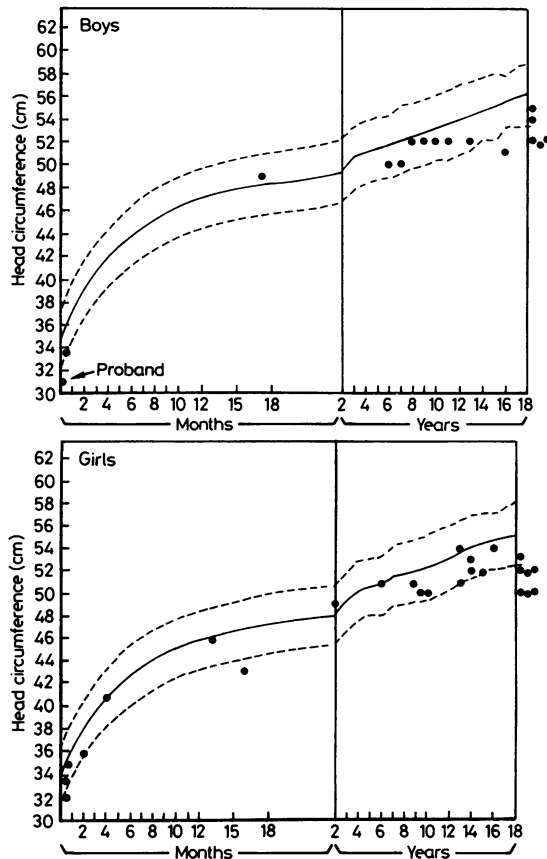


FIG 2 The head circumference of males (top) and females (bottom) in the reported family. (The family members of the proband's mother are not included.)

Familial microcephaly occurs with an estimated incidence of 1 in 25 000 to 1 in 50 000 of the total population between five and 55 years of age.¹⁴ Most cases of familial microcephaly appear to be inherited in an autosomal recessive fashion.^{1 3 4}

Only 18 families (including ours) in whom microcephaly was transmitted as an autosomal dominant trait have been reported (table). The present family is the largest one with an autosomal dominant form of microcephaly, including 13 affected members, another three having borderline head circumference. Most characteristics of the pedigree under study (fig 1) point strongly to autosomal dominant inheritance with incomplete penetrance. Subject II.19 had a normal head circumference but her daughter (III.30) was microcephalic. This phenomenon of a putative heterozygote not manifesting the trait, or 'skipped generation', was not encountered in any other published pedigrees. The penetrance in our kindred was 70.5%, but when we added the three borderline patients it was 88.2%. It is also interesting to note the variable expressivity, ranging from normal (skipped generation), through three borderline patients, to a head circumference of -3 SD.

The clinical characteristics of autosomal dominant microcephaly (established by Haslam and Smith⁴) in comparison with the autosomal recessive form are: non-distinctive facial appearance, normal stature, absence of neurological abnormalities, and mild or borderline mental retardation with poor school performance but relatively normal lives. In fact, there is considerable variation in the phenotypic expression of autosomal dominant microcephaly (table). Slightly dysmorphic facies (receding frontal region, upward slanting palpebral fissures, large,

TABLE Clinical features of reported autosomal dominant microcephaly.

Reference	Family No	M/F	Associated malformations		Mental retardation	Neurological abnormalities	Seizures	Ocular abnormalities
			Minor	Major				
4	1	0/2	—	—	Mild	Clonus	+	—
	2	2/1	Simian crease Protruding ears	Transposition of great vessels	Moderate	—	+	—
	3	0/3	Receding frontal region Upward slanting palpebral fissures	VSD VSD	Mild	—	—	—
5	4	1/3	—	—	Mild	—	—	Strabismus
6*	5	1/3	Protruding ears	Short stature	—	—	+	Nystagmus
6*	6	2/7	Dysmorphic facies	—	—	—	—	—
7	7	2/2	Protruding ears	VSD	—	Hyperactive	—	—
8	8	0/3	—	—	—	—	—	—
	9	3/3	—	—	—	—	—	—
	10	2/3	—	—	—	—	—	—
9	11	4/1	—	Lymphoedema	—	—	—	—
10	12	2/3	Micrognathia Receding frontal region Epicanthic folds Protruding ears	Lymphoedema	—	—	—	—
Present family	13	5/8	—	Short stature	—	—	—	—

*Another five families were recently reported.¹¹

protruding ears) was encountered in six families. Short stature was observed only in the family described by Burton.⁵ Our patient had a short length at birth but a normal height at the age of one year. It is interesting to note that mild mental retardation was encountered only in the four families initially reported by Haslam and Smith.⁴ Convulsive disorders were described in three families, but all patients were seizure free as adults. The only major malformation observed was congenital heart disease (ventricular septal defect (3), corrected transposition of the great vessels (1)). Therefore, 'pure' or isolated microcephaly transmitted as a familial autosomal dominant trait has been described only by Rossi and Battilana,⁶ Rossi *et al*,¹¹ Ramirez *et al*,⁸ and in this paper. This autosomal dominant isolated ('uncomplicated') microcephaly represents a special type which should be clearly distinguished from other well defined dominantly inherited forms of microcephaly, such as microcephaly and short stature,⁵ microcephaly and lymphoedema,⁹ ¹⁰ and chorioretinal dysplasia-microcephaly-mental retardation.¹⁵

We gratefully acknowledge the assistance of Dr M Friedman.

References

- ¹ Hecht F, Kelly JV. Little heads: inheritance and early detection. *J Pediatr* 1979;**95**:731-2.
- ² Nellhaus G. Head circumference from birth to eighteen years. Practical composite international and interracial graphs. *Pediatrics* 1968;**41**:106-14.
- ³ McKusick VA. *Mendelian inheritance in man*. 7th ed. Baltimore: Johns Hopkins University Press, 1986: 491, 1114-6.
- ⁴ Haslam RHA, Smith DW. Autosomal dominant microcephaly. *J Pediatr* 1979;**95**:701-5.
- ⁵ Burton BK. Dominant inheritance of microcephaly with short stature. *Clin Genet* 1981;**20**:25-7.
- ⁶ Rossi LN, Battilana MP. Autosomal dominant microcephaly. *J Pediatr* 1982;**101**:481-2.
- ⁷ Haslam RHA. Autosomal dominant microcephaly. Reply. *J Pediatr* 1982;**101**:482.
- ⁸ Ramirez ML, Rivas F, Cantu JM. Silent microcephaly: a distinct autosomal dominant trait. *Clin Genet* 1983;**23**:281-6.
- ⁹ Leung AKC. Dominantly inherited syndrome of microcephaly and congenital lymphedema. *Clin Genet* 1985;**27**:611-2.
- ¹⁰ Crowe CA, Dickerman LH. A genetic association between microcephaly and lymphedema. *Am J Med Genet* 1986;**24**:131-5.
- ¹¹ Rossi LN, Candini G, Scarlatti G, Rossi G, Prina E, Alberti S. Autosomal dominant microcephaly without mental retardation. *Am J Dis Child* 1987;**141**:655-9.
- ¹² Usher R, McLean F. Intrauterine growth of live-born Caucasian infants at sea level: standards obtained for measurements in 7 dimensions of infants born between 25 and 44 weeks of gestation. *J Pediatr* 1969;**74**:901-10.
- ¹³ Merlob P, Sivan Y, Reisner SH. Anthropometric measurements of the newborn infant (27-41 gestational weeks). *Birth Defects* 1984;**20**(7):1-52.
- ¹⁴ Book JA, Schut JW, Reed SC. A clinical and genetical study of microcephaly. *Am J Ment Defic* 1953;**57**:637-60.
- ¹⁵ Tenconi R, Clementi M, Moschini GB, Casara G, Baccichetti C. Chorio-retinal dysplasia, microcephaly and mental retardation. An autosomal dominant syndrome. *Clin Genet* 1981;**20**:347-51.

Correspondence and requests for reprints to Dr Paul Merlob, Department of Neonatology, Beilinson Medical Centre, Petah Tiqva 49 100, Israel.