

Short reports

Point mutation of the mitochondrial tRNA^{Leu} gene (A 3243 G) in maternally inherited hypertrophic cardiomyopathy, diabetes mellitus, renal failure, and sensorineural deafness

Sylvie Manouvrier, Agnès Rötig, Gery Hannebique, Jean-Dominique Gheerbrandt, Ghislaine Royer-Legrain, Arnold Munnich, Michel Parent, Jean-Pierre Grünfeld, Claude Largilliere, Anne Lombes, Jean-Paul Bonnefont

Abstract

The A 3243 G mutation of the mitochondrial tRNA^{Leu} gene was found to segregate with maternally inherited diabetes mellitus, sensorineural deafness, hypertrophic cardiomyopathy, or renal failure in a large pedigree of 35 affected members in four generations. Presenting symptoms almost consistently involved deafness and recurrent attacks of migraine-like headaches, but the clinical course of the disease varied within and across generations. The A 3243 G mutation has been previously reported in association with the mitochondrial encephalomyopathy, lactic acidosis, and stroke-like episode syndrome (MELAS) and with diabetes mellitus and deafness. To our knowledge, however, hypertrophic cardiomyopathy is not a common feature in people with the A 3243 G mutation and renal failure has not been hitherto reported in association with this mutation. The present observation gives additional support to the variable clinical expression of mtDNA mutations in humans.

(*J Med Genet* 1995;32:654-656)

In the last few years, several mitochondrial DNA (mtDNA) mutations have been described in association with maternally inherited human diseases.¹ Among them, the heteroplasmic A 3243 G mutation in the tRNA^{Leu} gene has been described in mitochondrial encephalomyopathy, lactic acidosis, and stroke-like episodes (MELAS),² in non-MELAS associated phenotypes including progressive external ophthalmoplegia (PEO),³ and in maternally inherited diabetes mellitus and hearing loss.⁴ Here, we describe hypertrophic cardiomyopathy, renal failure, and endocrine dysfunction as uncommon manifestations of the A 3243 G mutation. This observation gives additional support to the variable clinical expression of mtDNA mutations in human.

III·13 was referred for a personal and family history of hypertrophic cardiomyopathy, diabetes mellitus, and deafness (fig 1). Hearing loss occurred in the third decade, diabetes mellitus at the age of 36 years (requiring insulin administration four years later), and severe concentric hypertrophic cardiomyopathy at 44 years of age. He also had frequent migraine-like headaches and general weakness but no renal or ocular involvement was noted.

III·13 belongs to a large family of 40 affected subjects with maternally inherited multiorgan involvement over four generations (fig 1). Affected subjects were of both sexes and all had recurrent headaches and hearing loss. Several patients (14/40) had adult onset insulin dependent diabetes mellitus (IDDM) and renal failure, originally ascribed to IDDM. Renal failure was, however, present in one patient without diabetes mellitus (II·4). Focal sclerosis of glomeruli was observed in a needle biopsy of the kidney (III·12). Several people had severe cardiac involvement, including fatal hypertrophic cardiomyopathy (3/40, III·11, III·12, III·24), heart block (2/40, II·1, II·3), or sudden death (2/40, II·4, II·5). Neurological involvement included general seizures (2/40, II·5, III·5), brain infarctions, mild mental retardation, ataxia, and cerebellar atrophy (1/40, III·26) or calcification of the basal ganglia (1/40, II·5). Other endocrine manifestations included thyroid goitre (6/40) without thyroid insufficiency or hyperthyroidism (II·1, II·4, II·6, III·7, III·16, III·18), hypoparathyroidism (1/40, II·5), and hypothalamic hypocorticism (1/40, III·37). All affected females had hypertrichosis. Liver cirrhosis without evidence of alcoholism was present in II·8 and III·19. Mental retardation, cerebellar ataxia (1/40) and muscle weakness (2/40) were seldom observed. All children of generation IV (except IV·27, IV·28, IV·29, and IV·42) were asymptomatic at the time of examination, but IV·27, IV·28, and IV·29 had headaches and hearing loss. IV·42 suffered from recurrent "pallor attacks" without abnormal movements or mental retardation from 18 months of age. Interestingly,

Service de Pédiatrie,
Hôpital Huriez,
59000 Lille,
and Département de
Néphrologie et Unité
de Recherches sur les
Handicaps Génétiques
de l'Enfant INSERM
U-393,
Hôpital Necker-
Enfants Malades,
75743 Paris Cedex 15,
France
S Manouvrier
A Rötig
G Hannebique
G Royer-Legrain
A Munnich
J P Grünfeld
C Largilliere
J-P Bonnefont

Hôpital d'Arras,
62000 Arras, France
J-D Gheerbrandt

Hôpital de Douai,
59500 Douai, France
M Parent

Unité de Recherches
sur le Développement,
la Pathologie et la
Régénération du
Système
neuromusculaire
INSERM U-153,
75005 Paris,
France
A Lombes

Correspondence to:
Dr Bonnefont.

Received 16 December 1994
Revised version accepted for
publication 15 March 1995

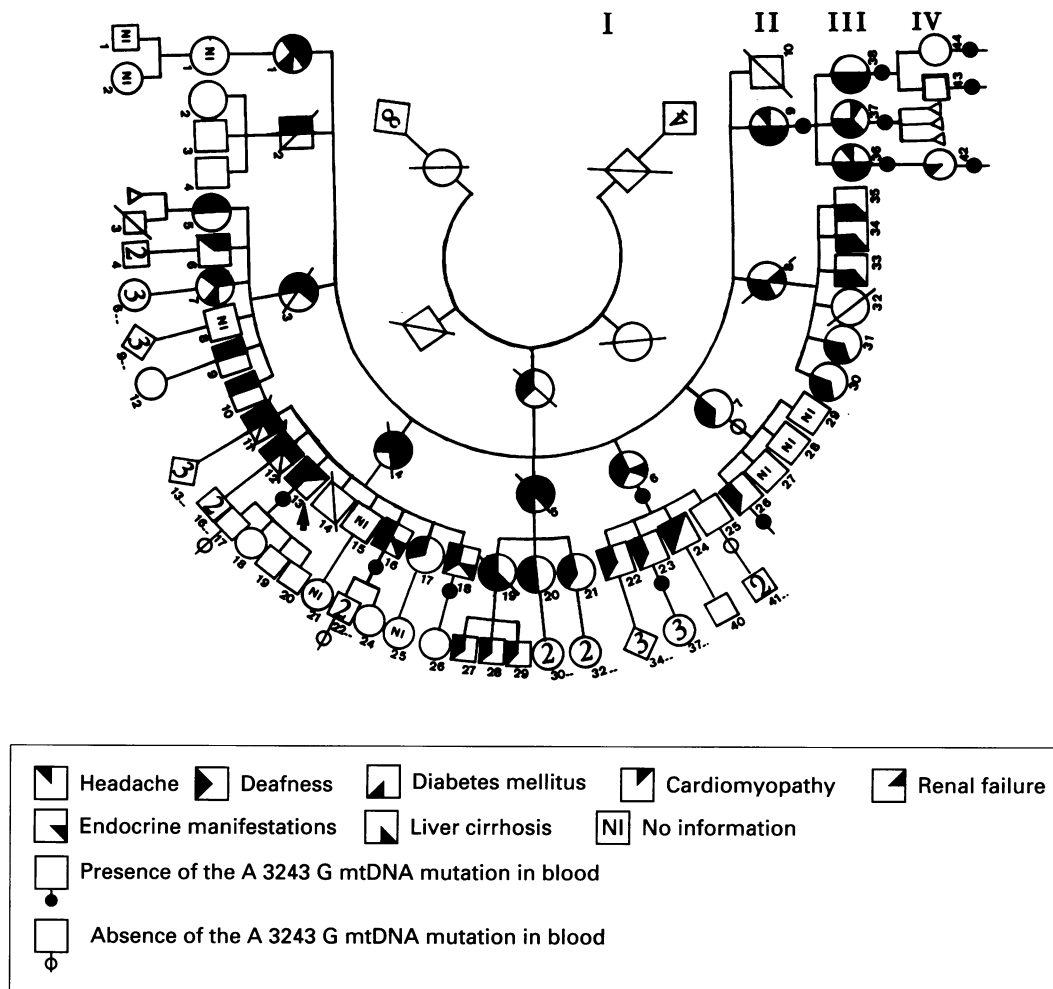


Figure 1 Segregation of the A 3243 G mutation in a four generation pedigree.

while I-3 had hearing loss only, 8/9 affected subjects in generation II had deafness plus one (or more) additional organ involvement (diabetes mellitus, renal failure, cardiomyopathy) and 5/9 died before the age of 65 years. In generation III, hearing loss occurred before 30 years of age while it occurred after the age of 40 years in II-4, II-6 and II-9.

Fibres of decreased size with few internal nuclei and a number of intermyofibrillar and subsarcolemmic basophilic deposits were observed in the muscle biopsy of patient III-13. PAS staining showed abundant glycogen matrix and red oil O staining fatty infiltrations. The modified Gomori stain showed numerous ragged red fibres and histoenzymological studies showed normal ATPase activity, non-homogeneous NADH-tetrazolium reductase activity (predominantly in subsarcolemmic regions), and, in ragged red fibres, increased SDH but decreased COX activities.

Screening for the A 3234 G mutation was carried out using oligonucleotide primers nt 3214-3238 and nt 3779-3803 (amplification conditions were: 95°C for 30 seconds, 55°C for 30 seconds, 72°C for 30 seconds). Amplification products (590 bp) were either digested with *ApaI* or submitted to direct sequencing on an automatic DNA sequencer (Applied Biosystems 373A) using *Taq* Dye Deoxy TM Terminator cycle sequencing kit (Applied Biosystems). Heteroplasmy for the A

3243 G mutation was shown by *ApaI* digestion and direct sequencing of amplified mtDNA from patient III-13 skeletal muscle and leucocytes. A heteroplasmic A 3243 G mutation was also present in circulating leucocytes of patients II-6, II-7, II-9, III-16, III-18, III-23, III-26, III-36, III-37, III-38, IV-42, IV-43, and IV-44 (fig 2). The relative amount of normal

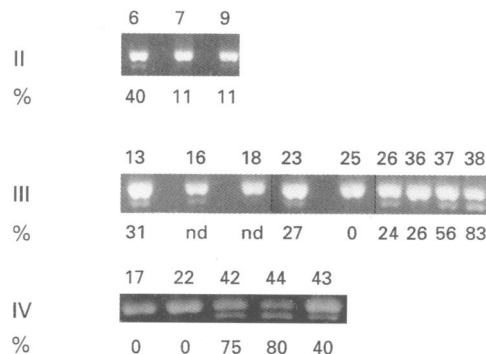


Figure 2 Identification and quantitation of the A 3243 G mutation of the mitochondrial tRNA^{Leu} gene in lymphocyte DNA. A 589 bp fragment encompassing the A 3243 G mutation was submitted to PCR amplification, *ApaI* digestion, and agarose gel electrophoresis. The 589 bp amplification product is normally digested in two fragments of 559 and 30 bp (not shown) respectively. Quantitation of the mutant DNA was achieved through Southern blotting of *ApaI* digested genomic DNA. The restriction fragments were hybridised and quantitated by densitometry. The proportion of mutant mtDNA molecules is shown and the numbers refer to the pedigree (fig 1).

and mutant mtDNA was quantitated by Southern blot and densitometry analysis of *ApaI* restriction fragments in lymphocytes (fig 2). No correlation between the amount of mutated molecules and the clinical profile of the patients could be observed, but an unaffected obligate carrier (III-25) did not apparently bear the A 3243 G mutation in his circulating leucocytes.

In this hitherto unreported four generation pedigree (40 patients) the association of symptoms (sensorineural hearing loss, migraine-like headaches, diabetes mellitus, hypertrophic cardiomyopathy, renal failure, and thyroid goitre) along with the maternal inheritance of the disease were suggestive of a mitochondrial disorder. Histopathological and molecular investigations in III-3 allowed us to ascribe this maternally inherited disease to a point mutation of the mitochondrial tRNA^{Leu} gene (A 3243 G).

The A 3243 G mutation of the mitochondrial tRNA^{Leu} gene has been previously reported in patients with MELAS,² PEO,³ diabetes with deafness,⁴ and occasionally with hypertrophic cardiomyopathy.⁵⁻⁸ Hitherto, however, renal failure, thyroid goitre, or hypoparathyroidism have not been reported in association with the A 3243 G mutation. The present observation emphasises the variable clinical expression of the A 3243 G mutation, a variability which could be ascribed to random segregation of mutated mitochondria in the different tissues, to a particular mtDNA haplotype, to the nuclear genetic background, or even to epigenetic phenomena. It is worth noting, however, that a variety of clinical symptoms have been reported in association with other tRNA^{Leu} mutations, including myoclonic epilepsy and ragged red fibres (C 3256 T),⁹ hypoparathyroidism and diabetes mellitus (A 3252 G),¹⁰ and myopathy with cardiomyopathy (A 3260 G).¹¹

All affected subjects tested bore the A 3243 G mutation in their circulating leucocytes. Again,

the failure to detect the tRNA^{Leu} mutation in leucocyte DNA of III-25 can be ascribed to random drift. Yet, why the disease apparently worsened with generations is unknown. Although this phenomenon may be because of ascertainment bias, it could also be related to either random drift or replicative advantage of mutant mtDNA molecules, as shown in the MELAS syndrome.¹² It appears therefore that the clinical expression of the A 3243 G mutation is particularly broad. This mutation should be considered in patients presenting an unexplained association of symptoms with an early onset and a progressive course, when hearing loss or diabetes mellitus is present.

- 1 Wallace DC, Lott MT, Shoffner JM, *et al.* Diseases resulting from mitochondrial DNA point mutations. *J Inher Metab Dis* 1992;15:472-9.
- 2 Goto Y, Nonaka I, Horai S. A mutation in the tRNA-Leu(UUR) gene associated with the MELAS subgroup of mitochondrial encephalomyopathies. *Nature* 1990;348:651-3.
- 3 Di Mauro S, Moraes CT. Mitochondrial encephalomyopathies. *Arch Neurol* 1993;50:1197-208.
- 4 Van den Ouweland JM, Lemkes H, Ruitenbeek W, *et al.* Mutation in mitochondrial tRNA leu (UUR) gene in a large pedigree with maternally transmitted type II diabetes mellitus and deafness. *Nature Genet* 1992;1:368-71.
- 5 Ciafaloni E, Ricci E, Shanske S, *et al.* MELAS: clinical features, biochemistry and molecular genetics. *Ann Neurol* 1992;31:391-8.
- 6 Reardon W, Ross RJM, Sweeney MC, *et al.* Diabetes mellitus associated with a pathogenic point mutation in mitochondrial DNA. *Lancet* 1992;340:1376-9.
- 7 Yoshida R, Ishida Y, Hozumi T, *et al.* Congestive heart failure in mitochondrial diabetes mellitus. *Lancet* 1994;334:1375.
- 8 Dougherty FE, Ernst SG, Aprille JR. Familial recurrence of atypical symptoms in an extended pedigree with the syndrome of mitochondrial encephalomyopathy, lactic acidosis and stroke-like episodes (MELAS). *J Pediatr* 1994;125:758-61.
- 9 Moraes CT, Ciacci F, Bonilla E, *et al.* Two novel pathogenic mitochondrial DNA mutations affecting organelle number and protein synthesis. *J Clin Invest* 1993;92:2906-15.
- 10 Morlen KJ, Cooper JM, Brown GK, *et al.* A new point mutation associated with mitochondrial encephalomyopathy. *Hum Molec Genet* 1993;2:2081-7.
- 11 Zeviani M, Gellera C, Antozzi C, *et al.* Maternally inherited myopathy and cardiomyopathy associated with mutation in mitochondrial DNA tRNA^{Leu}(UUR). *Lancet* 1991;338:143-7.
- 12 Yoneda M, Chomyn A, Martinuzzi A. Marked replicative advantage of human mtDNA carrying a point mutation that causes the MELAS encephalomyopathy. *Proc Natl Acad Sci USA* 1992;89:11164-8.