

# WAGR syndrome and multiple exostoses in a patient with del(11)(p11.2p14.2)

J M McGaughran, H B Ward, D G R Evans

## Abstract

**The WAGR syndrome (Wilms' tumour, aniridia, genital anomalies, and mental retardation) is well documented to be associated with a deletion of 11p13. We present a patient with a del(11)(p11.2p14.2) who as well as all the features of WAGR syndrome has multiple exostoses. We suggest that this could be a possible locus for hereditary multiple exostoses.**

(J Med Genet 1995;32:823-824)

The association of Wilms' tumour, aniridia, genital anomalies, and mental retardation (WAGR) was first described by Miller *et al.*<sup>1</sup> Most affected subjects have a de novo 11p13 deletion and study of these subjects has led to the assignment of a Wilms' tumour gene (WT1) to 11p13 and an autosomal dominant aniridia gene slightly distal, also within the 11p13 region.<sup>2</sup> Recently it has been suggested that the occurrence of obesity in a patient with typical del(11p13) WAGR syndrome raises the possibility of a gene contiguous with the WAGR region responsible for obesity.<sup>3</sup> We report on a young man who has all the features of WAGR syndrome as well as multiple exostoses and suggest that a further possible contiguous gene deletion within the WAGR region may be responsible for the hereditary multiple exostoses in his case.

## Case report

The proband is a 26 year old man, the second child of non-consanguineous parents. He weighed 3700 g at birth at term and was initially difficult to feed. At 9 weeks of age, bilateral aniridia was diagnosed and it was noted he had two large lacunae in the left parietal region and a large fontanelle. Subsequently bilateral buphthalmos, glaucoma, and lens opacities were diagnosed. He was also noted to have hypospadias, undescended testes, and a small penis. He had some dysmorphic features with posteriorly angulated low set ears and coarse facies. His neck was noted to be short and broad. He had numerous postoperative infections and transient hypogammaglobulinaemia was diagnosed.<sup>4</sup> He developed haematuria when aged 2 years and a Wilms' tumour was removed from the upper pole of his left kidney.<sup>5</sup> He subsequently had chemotherapy and radiotherapy. At the age of 4 years he could say only a few words and a Merrill-Palmer test showed a mental age of 2 years 1 month. He passed four items on the Stanford-

Binet scale at the 2 year level. When older, his right kidney was noted to be enlarged and he had further haematuria. The diagnosis of glomerulonephritis was made in the remaining kidney but he remains well and requires anti-hypertensive therapy.

He was also noted to have developed multiple exostoses on many of the bones. The first to be noted were on the right upper humerus and both scapulae. He subsequently was noted to have them on the long bones of his legs, the spinous process of the second lumbar vertebra, and the right posterior iliac crest. Platyspondyly, short, broad ribs, and a triradiate pelvis were also noted. Several of the exostoses have required surgical removal and in each case were confirmed histologically as being exostoses with irregular cartilage caps.

He is mentally retarded and requires support at home although he is able to go out with friends and attends a day centre. He is further restricted by his poor vision. He walks with a wide based gait. His height is 150 cm (<3rd centile) and his weight is 70 kg (75th centile).

There is no family history of eye problems or exostoses. The only history of cancer in the family is that his father died recently of carcinoma of the oesophagus at the age of 61 years.

## Cytogenetic results

Samples were taken for detailed chromosome analysis and to establish whether there was a deletion of the WT1 gene using FISH probes E1241 and D8190.<sup>6</sup>

Chromosome analysis showed an abnormal male karyotype 46,XY,del(11)(p11.2p14.2) with an interstitial deletion in the short arm of chromosome 11 (figure). Both cosmid probes for the WT1 gene were also deleted on one of the chromosome 11 homologues.

It was not possible to obtain samples for analysis from his parents.

A cell line has been established on this patient. (Contact Dr J M McGaughran, St Mary's Hospital, Hathersage Road, Manchester M13 0JH.)

## Discussion

The features of WAGR syndrome were all present in our patient. He also had the recently described feature of obesity which was suggested to be the result of the deletion of a gene concerned with growth contiguous with the WAGR deletion. Our patient had a deletion and the presence of multiple exostoses suggests that perhaps a further contiguous gene may be involved in the deleted DNA.

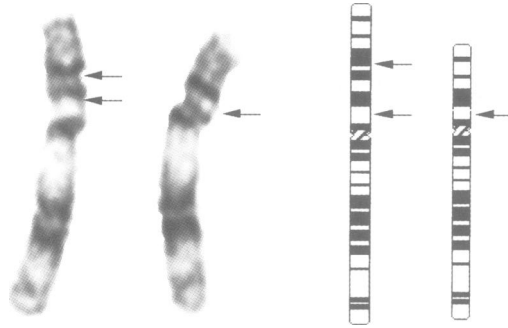
Department of  
Medical Genetics,  
St Mary's Hospital,  
Manchester M13 0JH,  
UK

J M McGaughran  
D G R Evans

Department of  
Cytogenetics,  
St Mary's Hospital,  
Manchester M13 0JH,  
UK  
H B Ward

Correspondence to:  
Dr McGaughran.

Received 8 March 1995  
Revised version accepted for  
publication 7 June 1995



Partial karyotype of the proband. On the right is the ideogram showing the breakpoints of the deletion. On the left is the chromosome 11 pair showing the deleted chromosome.

Hereditary multiple exostoses is characterised by cartilaginous excrescences near the ends of the diaphyses of the bones of the extremities. The exostoses can give rise to complications such as compression or irritation of adjacent nerves, vessels, and tendons, and urinary and intestinal obstruction (MIM 133701).<sup>7</sup> Reduced stature may be associated with the condition and there is a risk of sarcomatous degeneration in 0.5 to 2% of affected subjects.<sup>8</sup>

Langer-Giedion syndrome is a contiguous gene syndrome resulting from a deletion in the 8q24 region which has multiple exostoses as a feature. It is felt that about 70% of families with multiple exostoses show linkage to markers in the 8q24.11–q24.13 region.<sup>9</sup> The candidate gene at this locus has been designated EXT1. A case of multiple exostoses with a balanced translocation t(8;11)(q24.11;p15.1) has been described<sup>10</sup> and it was felt that the significant breakpoint was at 8q24.1. Wu *et al*<sup>11</sup> showed evidence of linkage to microsatellite markers from the proximal short and long arms of chromosome 11 (EXT2) in two large multiple exostoses pedigrees where linkage to markers from 8q24 was excluded. Le Merrer *et al*<sup>12</sup> tested for linkage to markers in the region 11p12–p11 as they had a patient with multiple exostoses and an interstitial deletion of that region. Linkage to this region was excluded.

However, in 21 families that they studied they did find linkage to 19p in 35%. The locus was mapped to 19p by linkage to a microsatellite DNA marker at the D19S221 locus. The remaining 65% of the families showed linkage to chromosome 8. This locus has been designated EXT3. No clinical differentiation could be made between the two groups of patients. In our patient, the presence of multiple exostoses could be attributed to a new mutation in any of the three putative genes described. However, the presence of a deletion involving 11p11 suggests that, as previously described, there may be a locus in this region of chromosome 11 and the deletion present in our patient might be able to refine further the suggested gene locus. In our patient's case, this would suggest he has a contiguous gene deletion causing his numerous problems, including his multiple exostoses for which there was no antecedent family history.

We would like to thank Dr K MacLavery for referring the patient. We would also like to thank Mr J Dore for performing the FISH studies for the WT1 gene.

- 1 Miller RW, Fraumeni JF Jr, Manning MD. Association of Wilms' tumour with aniridia, hemihypertrophy and other congenital malformations. *N Engl J Med* 1964;270:922–7.
- 2 Clericuzio CL. Clinical phenotypes and Wilms tumour. *Med Paediatr Oncol* 1993;21:182–7.
- 3 Marlin S, Couet D, Lacombe D, Cessans C, Bonneau D. Obesity: a new feature of WAGR (del 11p) syndrome. *Clin Dysmorphol* 1994;3:255–7.
- 4 Evans DIK, Holzel A. Wilms aniridia syndrome with transient hypogammaglobulinemia in infancy. *Arch Dis Child* 1973;48:645–6.
- 5 Shannon RS, Mann JR, Harper E, Harnden DG, Morten JEN, Herbert A. Wilms tumour and aniridia: clinical and cytogenetic features. *Arch Dis Child* 1982;57:685–90.
- 6 Kempiski H, Cowell JK. Detection of submicroscopic chromosomal deletions in aniridia patients using fluorescence in situ hybridization and a panel of cosmids covering the WT1 gene. *Int J Oncol* 1993;3:937–40.
- 7 OMIM, the on-line version of *Mendelian inheritance in man*. January 1995.
- 8 Hennekam RCM. Hereditary multiple exostoses. *J Med Genet* 1991;28:262–6.
- 9 Cook A, Raskind W, Blanton SH, *et al*. Genetic heterogeneity in families with hereditary multiple exostoses. *Am J Hum Genet* 1993;53:71–9.
- 10 Ogle RF, Dalzell P, Turner G, Wass D, Yip M-Y. Multiple exostoses in a patient with t(8;11)(q24.11;p15.5). *J Med Genet* 1991;28:881–3.
- 11 Wu YQ, Heutink P, de Vries BBA, *et al*. Assignment of a second locus for multiple exostoses to the pericentromeric region of chromosome 11. *Hum Mol Genet* 1994;3:167–71.
- 12 Le Merrer M, Legeai-Mallet L, Jeannin PM, *et al*. A gene for hereditary multiple exostoses maps to chromosome 19p. *Hum Mol Genet* 1994;3:717–22.