

# Arthroscopic Sesamoidectomy and Plantar Metatarsal Head Bone Shaving in Management of First Metatarsal Head Metatarsalgia After First Metatarsophalangeal Fusion



Sui Kit Chan, M.B.B.S., and  
Tun Hing Lui, M.B.B.S. (HK), F.R.C.S. (Edin), F.H.K.A.M., F.H.K.C.O.S.

**Abstract:** First metatarsophalangeal arthrodesis has been used to treat end-stage arthritis of the great toe (e.g., gout, post-traumatic, infection), severe hallux valgus deformity, hallux valgus caused by neuromuscular disorders, rheumatoid forefoot deformity, primary hallux varus, and rigid plantarflexion deformities, as well as a salvage procedure for failed previous operation of the great toe. As with any arthrodesis procedure, proper positioning of the hallux in first metatarsophalangeal arthrodesis is of utmost importance for good clinical outcome. The chief problem tends to be sagittal alignment. In case of the significant dorsiflexion malunion of the fusion site with excessive plantar pressure of the first metatarsophalangeal joint and abutment of the hallux to the shoebox, corrective osteotomy is indicated. If there is isolated excessive plantar pressure of the first metatarsophalangeal joint without hallux problem, arthroscopic sesamoidectomy and bone shaving of the plantar side of the first metatarsal head is another surgical option. The purpose of this technical note is to describe the details of arthroscopic sesamoidectomy and bone shaving of the plantar side of the first metatarsal head.

First metatarsophalangeal arthrodesis (either open or arthroscopic) has been used to treat end-stage arthritis of the great toe (e.g., gout, post-traumatic, infection), severe hallux valgus deformity, hallux valgus caused by neuromuscular disorders, rheumatoid forefoot deformity, primary hallux varus, and rigid plantarflexion deformities, as a salvage procedure for failed previous operation of the great toe including failed previous osteotomies for hallux valgus correction resulting in recurrent deformity, iatrogenic hallux varus

or avascular necrosis, as well as salvage after failed resection and replacement arthroplasties or failed cheilectomy.<sup>1-6</sup> This procedure usually results in good clinical outcome. However, complications can occur and include delayed union, nonunion, malunion, wound dehiscence, seroma, infection, osteomyelitis, hallux ischemia, nerve damage, hematoma, failed or prominent and irritating hardware, and hallux interphalangeal joint arthritis.<sup>2</sup> Malunion (incidence of 6.1%) can occur in the sagittal, frontal, and transverse planes, especially at the sagittal plane.<sup>2,7-9</sup> Excessive plantar pressure can occur under the first metatarsal head, and, most of the time, it is due to excessive dorsiflexion resulting in increased plantar pressure at the first metatarsophalangeal joint, compensatory interphalangeal joint hyperflexion, and dorsal impingement of the great toe against the shoe wear.<sup>2,6</sup> This is typically treated by corrective osteotomy if conservative treatment fails to relieve symptoms.<sup>9</sup> In case of excessive plantar pressure at the fused first metatarsophalangeal joint with relatively normal sagittal alignment of the great toe, sesamoidectomy is an alternative surgical option. First metatarsophalangeal sesamoidectomy is a well-established procedure for intractable plantar keratosis,

From the Department of Orthopaedics and Traumatology, North District Hospital, Hong Kong, China.

The authors report that they have no conflicts of interest in the authorship and publication of this article. Full ICMJE author disclosure forms are available for this article online, as [supplementary material](#).

Received April 6, 2023; accepted May 15, 2023.

Address correspondence to Tun Hing Lui, Department of Orthopaedics and Traumatology, North District Hospital, 9 Po Kin Road, Sheung Shui, NT, Hong Kong SAR, China. E-mail: [luithderek@yahoo.co.uk](mailto:luithderek@yahoo.co.uk)

© 2023 THE AUTHORS. Published by Elsevier Inc. on behalf of the Arthroscopy Association of North America. This is an open access article under the CC BY-NC-ND license (<http://creativecommons.org/licenses/by-nc-nd/4.0/>).

2212-6287/23530

<https://doi.org/10.1016/j.eats.2023.05.002>

sesamoiditis, painful metatarsosesamoid osteoarthritis refractory to conservative treatment, sesamoidal osteomyelitis avascular necrosis, osteochondrosis and nonunion of sesamoid fractures.<sup>10,11</sup> Classically, it is performed in an open manner with a high complication rate of 22.5%, including damage to the lateral digital nerve, which is just at the lateral side of fibular sesamoid; postoperative stiffness caused by excessive soft tissue dissection; development of hallux valgus, hallux varus, or cock-up deformity because of disruption of ligamentous and tendinous attachments to the sesamoid bones; weakness of plantarflexion strength, and transfer metatarsalgia, owing to the altered mechanical loading on the forefoot.<sup>10-13</sup> Postoperative stiffness, weakness, and deformity of the first metatarsophalangeal joint are not the risks in the cases where the first metatarsophalangeal joint is previously fused. Recently, techniques of arthroscopic sesamoidectomy have been described with the potential advantage of minimally invasive surgery.<sup>10,12,14</sup> The purpose of this technical note is to describe the details of arthroscopic sesamoidectomy and plantar metatarsal head bone shaving in management of first metatarsal head metatarsalgia after first metatarsophalangeal fusion. It is indicated in case of recalcitrant first metatarsal head metatarsalgia after fusion of the first metatarsophalangeal joint without excessive hallux dorsiflexion. It is contraindicated if there is malunion of the first metatarsophalangeal fusion site resulting in hallux valgus, hallux varus or cock-up deformity requiring corrective osteotomy. It is also contraindicated if the sesamoid bones is already fused to the first metatarsal head (Table 1).

## Technique

### Preoperative Assessment and Patient Positioning

On clinical examination, the overall alignment of the foot and ankle should be examined. Any cavus or cavovarus foot deformity should be noted. The great toe should be examined for any malposition in the sagittal, coronal, and transverse planes and any callosity present in the plantar side of first metatarsophalangeal joint and

**Table 1.** Indications and Contraindications of Arthroscopic Sesamoidectomy and Plantar Metatarsal Head Bone Shaving in Management of First Metatarsal Head Metatarsalgia After First Metatarsophalangeal Fusion

|                   |  |
|-------------------|--|
| Indications       | Recalcitrant first metatarsal head metatarsalgia after fusion of the first metatarsophalangeal joint   |
| Contraindications | Malunion of the first metatarsophalangeal fusion site resulting in hallux valgus, hallux varus or cock-up deformity requiring corrective osteotomy |
|                   | The sesamoid bones already fused to the first metatarsal head  |

dorsum of the interphalangeal joint. Radiographs are useful for assessment of the alignment of the foot and great toe and confirmation of fusion of the first metatarsophalangeal joint (Fig 1).

The patient is in the supine position with the legs spread. A thigh tourniquet is applied to provide a bloodless operative field. A 2.7-mm, 30° arthroscope (Henke Sass Wolf GmbH, Tuttlingen, Germany) is used for this procedure. Fluid inflow is by gravity and arthropump is not used.

### Portal Placement

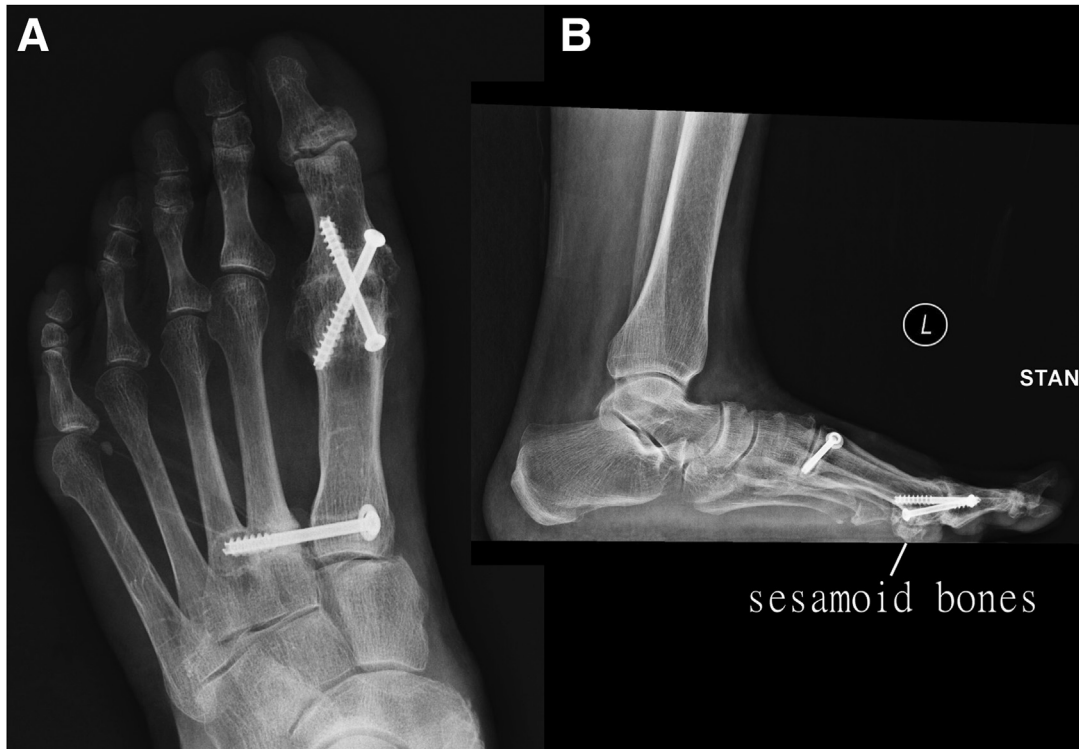Metatarsosesamoid arthroscopy is performed via the medial and proximal plantar medial portals. The medial portal is at the mid-point of the medial joint line of the first metatarsophalangeal joint and the proximal plantar medial portal is 5 to 10 mm proximal to the plantar proximal margin of the first metatarsal head and between flexor hallucis brevis and abductor hallucis tendons (Fig 2).<sup>3-5,10</sup> Skin incisions of 3 to 4 mm are made at the portal sites, and the underlying soft tissue is bluntly dissected down to the metatarsosesamoid articulation with a hemostat. The capsule of the metatarsosesamoid articulation is pierced by the tip of the hemostat.

### Medial Metatarsosesamoid Compartment Bone Shaving

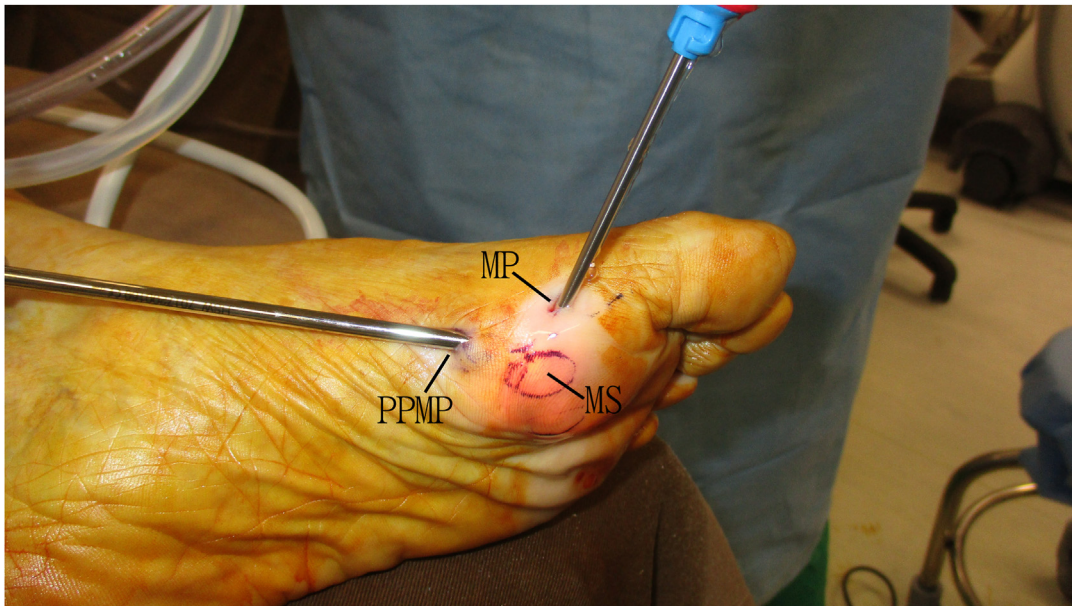
The medial portal is the viewing portal and the proximal plantar medial portal is the working portals. The fibrous tissue and synovium of the medial metatarsosesamoid compartment is resected with an arthroscopic shaver (Dyonics; Smith and Nephew, Andover, MA). The flexor hallucis longus tendon is usually exposed and should be protected from injury (Fig 3). Synovectomy of the flexor hallucis longus tendon can be performed if tenosynovitis is present. Bone shaving of the medial sesamoid bone and the corresponding plantar-medial metatarsal head is performed with an arthroscopic burr (Dyonics). The assistant can push the medial sesamoid bone toward the arthroscopic burr to stabilize the sesamoid bone during sesamoidectomy. The amount of bone shaving is titrated by regular checking of plantar pressure of the first metatarsophalangeal joint. The plantar joint capsule and the soft tissue covering the sesamoid bone should be preserved to avoid injury to the digital nerves.

### Exploration of the Lateral Metatarsosesamoid Compartment

The medial portal is the viewing portal and the proximal plantar medial portal is the working portals. The flexor hallucis longus tendon sheath is stripped from the plantar surface of the first metatarsal head by means of an arthroscopic osteotome (Acufex; Smith



**Fig 1.** Arthroscopic sesamoidectomy and plantar metatarsal head bone shaving in management of first metatarsal head metatarsalgia after first metatarsophalangeal fusion of the left foot. The patient is in supine position with the legs spread. Preoperative radiographs of the foot show no cavus or cavovarus foot deformity. There is no significant hallux deformity in the transverse or sagittal plane. (A) Dorsoplantar view; (B) lateral view.



**Fig 2.** Arthroscopic sesamoidectomy and plantar metatarsal head bone shaving in management of first metatarsal head metatarsalgia after first metatarsophalangeal fusion of the left foot. The patient is in the supine position with the legs spread. Metatarsosesamoid arthroscopy is performed via the medial and proximal plantar medial portals. The medial portal is at the midpoint of the medial joint line of the first metatarsophalangeal joint and the proximal plantar medial portal is 5 to 10 mm proximal to the plantar proximal margin of the first metatarsal head and between flexor hallucis brevis and abductor hallucis tendons. MS, medial sesamoid; MP, medial portal; PPMP, proximal plantar medial portal.

and Nephew) (Fig 4). The lateral metatarsosesamoid compartment is then exposed.

### Lateral Metatarsosesamoid Compartment Bone Shaving

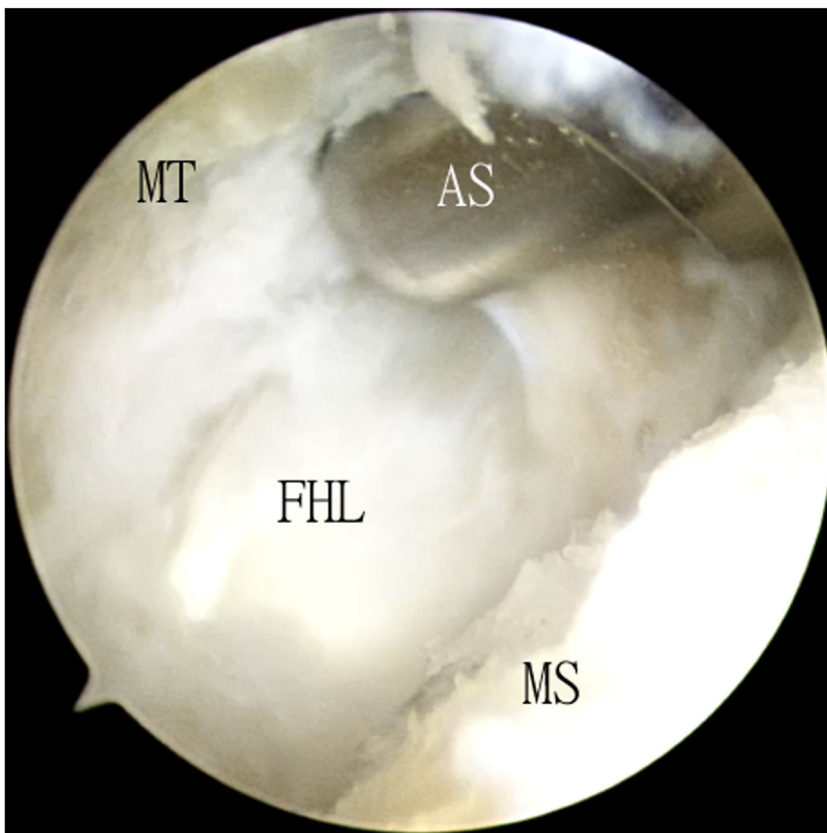
The proximal plantar medial portal is the viewing portal and the medial portal is the working portals. The fibrous tissue and synovium of the lateral metatarsosesamoid compartment is resected with the arthroscopic shaver. Bone shaving of the lateral sesamoid bone and the corresponding plantar-lateral metatarsal head is performed with the arthroscopic burr. The assistant can push the lateral sesamoid bone toward the arthroscopic burr to stabilize the sesamoid bone during sesamoidectomy (Fig 5). The amount of bone shaving is titrated by regular checking of plantar pressure of the first metatarsophalangeal joint. The plantar joint capsule and the soft tissue covering the sesamoid bone should be preserved to avoid injury to the digital nerves (Table 2, Video 1).

After surgery, weightbearing walking as pain tolerated is allowed. Active and passive mobilization of the interphalangeal joint of the great toe and the ankle is instructed to avoid adhesions around the flexor hallucis longus tendon.

### Discussion

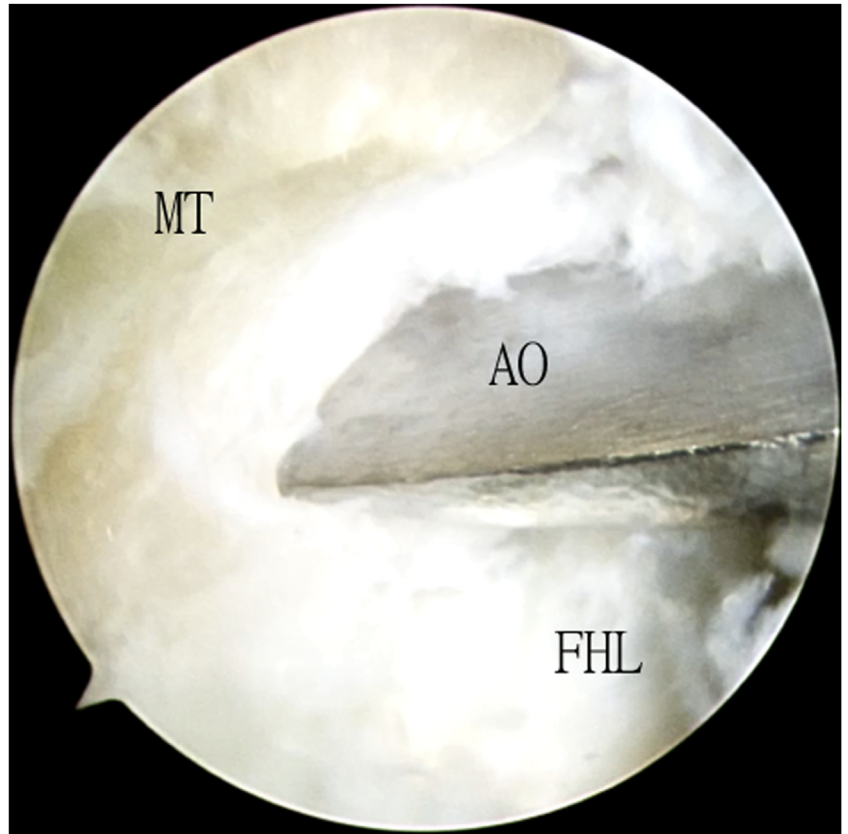
As with any arthrodesis procedure, proper positioning of the hallux in first metatarsophalangeal arthrodesis is of utmost importance for a good clinical outcome. The chief problem tends to be sagittal alignment because it is difficult to find a reference point for sagittal alignment of the first metatarsophalangeal joint.<sup>6</sup> It is also technically difficult to produce a true lateral view of the first metatarsophalangeal joint and accurately measure the fusion sagittal angle on intraoperative fluoroscopy because of the overlapping lesser metatarsals and digits.<sup>6,15</sup> In case of the significant dorsiflexion malunion of the fusion site with excessive plantar pressure of the first metatarsophalangeal joint and abutment of the hallux to the shoebox, corrective osteotomy is indicated. If there is isolated excessive plantar pressure of the first metatarsophalangeal joint without hallux problem, arthroscopic sesamoidectomy and bone shaving of the plantar side of the first metatarsal head is another surgical option. It has the potential advantages of short rehabilitation, a quick return to sporting activities, and no risk of malunion or nonunion as compared to corrective osteotomy.<sup>13</sup>

In this reported technique, the bone shaving is at the articular side rather than the plantar surface of the



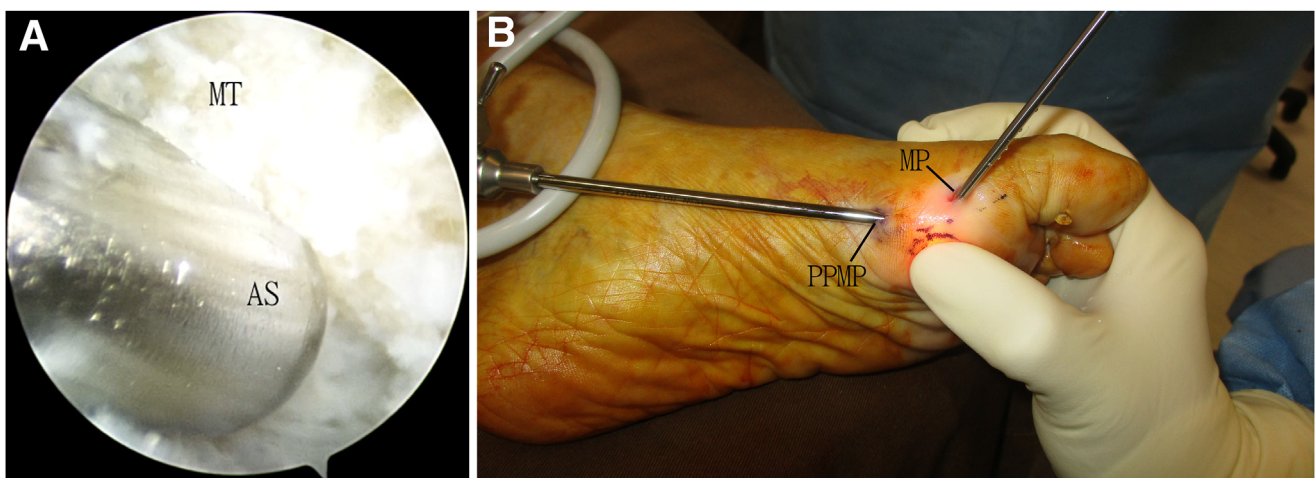
**Fig 3.** Arthroscopic sesamoidectomy and plantar metatarsal head bone shaving in management of first metatarsal head metatarsalgia after first metatarsophalangeal fusion of the left foot. The patient is in supine position with the legs spread. The medial portal is the viewing portal and the proximal plantar medial portal is the working portals. The fibrous tissue and synovium of the medial metatarsosesamoid compartment is resected with an arthroscopic shaver. MS, medial sesamoid; MT, plantar side of first metatarsal head; FHL, flexor hallucis longus tendon; AS, arthroscopic shaver.

**Fig 4.** Arthroscopic sesamoidectomy and plantar metatarsal head bone shaving in management of first metatarsal head metatarsalgia after first metatarsophalangeal fusion of the left foot. The patient is in supine position with the legs spread. The medial portal is the viewing portal and the proximal plantar medial portal is the working portals. The flexor hallucis longus tendon sheath is stripped from the plantar surface of the first metatarsal head by means of an arthroscopic osteotome. AO, arthroscopic osteotome; FHL, flexor hallucis longus tendon; MT, plantar side of first metatarsal head.



sesamoid bones. This can avoid creation of uneven weight bearing surfaces of the sesamoid bones and injury to the digital nerves especially the plantar lateral one. Intra-articular bone shaving may lead to painful

osteoarthritis of the metatarsophalangeal articulation. However, Lui<sup>16</sup> has demonstrated that cartilage lesions of the metatarsosesamoid compartment are not associated with pain. Moreover, creation of kissing raw



**Fig 5.** Arthroscopic sesamoidectomy and plantar metatarsal head bone shaving in management of first metatarsal head metatarsalgia after first metatarsophalangeal fusion of the left foot. The patient is in supine position with the legs spread. (A) The proximal plantar medial portal is the viewing portal and the medial portal is the working portals. The fibrous tissue and synovium of the lateral metatarsosesamoid compartment is resected with the arthroscopic shaver. (B) The assistant pushes the lateral sesamoid bone towards the arthroscopic burr to stabilize the sesamoid bone during sesamoidectomy. MP, medial portal; PPMP, proximal plantar medial portal; MT, plantar side of first metatarsal head; AS, arthroscopic shaver.

**Table 2.** Pearls and Pitfalls of Arthroscopic Sesamoidectomy and Plantar Metatarsal Head Bone Shaving in Management of First Metatarsal Head Metatarsalgia After First Metatarsophalangeal Fusion

|   |
|---|
| Pearls  |
| The location of the portals can be confirmed by needle insertion into the metatarsosesamoid articulation before making the portal incision. |
| The proper positioning of the needle can be confirmed under fluoroscopy.  |
| The assistant can press the sesamoid bone toward the arthroscopic burr to stabilize the bone during sesamoidectomy                          |
| Pitfalls  |
| Excessive bone shaving may lead to transfer metatarsalgia   |
| Inadequate bone shaving may lead to persistent pain at the first metatarsal head.   |

**Table 3.** Advantages and Risks of Arthroscopic Sesamoidectomy and Plantar Metatarsal Head Bone Shaving in Management of First Metatarsal Head Metatarsalgia After First Metatarsophalangeal Fusion

|  |
|--|
| Advantages   |
| Small incisions and better cosmetic outcome  |
| Minimal soft tissue trauma   |
| Titration of the location and amount of bone shaving according to the site of pressure point.                                    |
| Risks  |
| Digital nerve injury   |
| Residual first metatarsal head metatarsalgia   |
| Transfer metatarsalgia to second metatarsal  |
| Flexor hallucis longus tendon rupture or fibrous adhesions and resultant deformity of the interphalangeal joint of the great toe |

bone surfaces at the sesamoid bones and the corresponding plantar side of the first metatarsal head may induce fusion of the metatarsosesamoid articulation.

The advantages of this technique include small incisions and better cosmetic outcome, minimal soft tissue trauma, and titration of the location and amount of bone shaving according to the location of pressure point. The potential risks of this technique include digital nerve injury, residual first metatarsal head metatarsalgia, transfer metatarsalgia to second metatarsal, flexor hallucis longus tendon rupture or fibrous adhesions, and resultant deformity of the interphalangeal joint of the great toe (Table 3). This procedure is not technically difficult and can be managed by averaged foot and ankle arthroscopists.

## References

- Prissel MA, Brandao R, Dujela MD, Fidler CM, Langan T, Hyer CF. High utility of the 1st metatarsal phalangeal joint fusion. *Clin Podiatr Med Surg* 2022;39:157-165.
- Koutsouradis P, Savvidou OD, Stamatis ED. Arthrodesis of the first metatarsophalangeal joint: The "when and how.". *World J Orthop* 2021;12:485-494.
- Lui TH. Arthroscopic first metatarsophalangeal arthrodesis for repair of fixed hallux varus deformity. *J Foot Ankle Surg* 2015;54:1127-1131.
- Lui TH. Arthroscopic arthrodesis of the first metatarsophalangeal joint in hallux valgus deformity. *Arthrosc Tech* 2017;6:e1481-e1487.
- Li CHC, Lui TH, Pan X. Arthroscopic arthrodesis of the first metatarsophalangeal joint in hallux varus. *Arthrosc Tech* 2021;10:e2443-e2447.
- Hong CC. CORR insights: Validation of the artificial floor technique in first metatarsophalangeal joint arthrodesis. *Clin Orthop Relat Res* 2022;480:2010-2012.
- Kang YS, Bridgen A. First metatarsophalangeal joint arthrodesis/fusion: A systematic review of modern fixation techniques. *J Foot Ankle Res* 2022;15:30.
- Roukis TS. Nonunion after arthrodesis of the first metatarsal-phalangeal joint: A systematic review. *J Foot Ankle Surg* 2011;50:710-713.
- Gaudin G, Coillard JY, Augoyard M, et al. Incidence and outcomes of revision surgery after first metatarsophalangeal joint arthrodesis: Multicenter study of 158 cases. *Orthop Traumatol Surg Res* 2018;104:1221-1226.
- Chan PK, Lui TH. Arthroscopic fibular sesamoidectomy in the management of the sesamoid osteomyelitis. *Knee Surg Sports Traumatol Arthrosc* 2006;14:664-667.
- Canales MB, DeMore M III, Bowen MF, Ehredt DJ Jr, Razzante MC. Fact or fiction? Iatrogenic hallux abducto valgus secondary to tibial sesamoidectomy. *J Foot Ankle Surg* 2015;54:82-88.
- Nakajima K. Arthroscopic sesamoidectomy for hallux sesamoid disorders. *J Foot Ankle Surg* 2022;61:175-180.
- Shimozono Y, Hurley ET, Brown AJ, Kennedy JG. Sesamoidectomy for hallux sesamoid disorders: A systematic review. *J Foot Ankle Surg* 2018;57:1186-1190.
- Perez Carro L, Echevarria Llata JI, Martinez Agueros JA. Arthroscopic medial bipartite sesamoidectomy of the great toe. *Arthroscopy* 1999;15:321-325.
- Strony JT, Rascoe AS, Marcus RE. Validation of the artificial floor technique in first metatarsophalangeal joint arthrodesis. *Clin Orthop Relat Res* 2022;480:2002-2009.
- Lui TH. First metatarsophalangeal joint arthroscopy in patients with hallux valgus. *Arthroscopy* 2008;24:1122-1129.