



Case Report

J Liver Cancer 2023;23(2):389-396

pISSN 2288-8128 • eISSN 2383-5001

<https://doi.org/10.17998/jlc.2023.06.07>

Hepatic basidiobolomycosis masquerading as cholangiocarcinoma: a case report and literature review

Roopali Sehrawat¹, Nalini Bansal¹, Ajitabh Srivastava², Dharmender Malik³, Vivek Vij⁴

¹Department of Pathology, SGT University, Budhera, Gurugram; ²Department of Liver Transplant Surgery, Aakash Healthcare Super Speciality Hospital, Dwarka, New Delhi; ³Department of Nuclear Medicine & PET-CT, Fortis Memorial Research Institute (FMRI), Gurugram; ⁴Department of Liver Transplant Surgery, Fortis Healthcare, Budhera, Gurugram, India

Received Jan. 12, 2023

Revised Feb. 13, 2023

Accepted Jun. 7, 2023

Basidiobolus ranarum is known to cause subcutaneous mycoses; however, rare cases of hepatic and gastrointestinal involvement by basidiobolomycosis have been reported. Hepatic basidiobolomycosis may be confused with a carcinoma on imaging, and histological examination and fungal culture can help distinguish between these two. We report a rare case of basidiobolomycosis in a 16-year-old male with liver and gastrointestinal involvement. (**J Liver Cancer 2023;23:389-396**)

Keywords: Basidiobolus, Gastrointestinal, Hepatic, Fungus, Case reports

INTRODUCTION

Basidiobolomycosis is a rare infection caused by the fungus *Basidiobolus ranarum* (*B. ranarum*) belongs to the class *Zygomycetes* and the family *Entomophthoraceae*. It is commonly found in warm rural regions of Sub-Saharan Africa, South America, and Asia (Saudi Arabia, Kuwait, Iran, India, Indonesia, and Burma). Basidiobolomycosis mainly affects immunocompetent humans of all age groups, and the infection is usually aggressive and sometimes fatal. The infection often presents with non-specific clinical and radiological features; therefore, it should be considered in the differential diagnosis in endemic regions.¹ We report a rare case of basidiobolomycosis in a 16-year-old male with liver and gastrointestinal involvement.

Corresponding author: Nalini Bansal

Department of Pathology, SGT University, Gurgaon-Badli Road Chandu, Budhera, Gurugram 122505, India
Tel. +91-999-037-0677
E-mail: drnalini Bansal@gmail.com

CASE REPORT

A 16-year-old male from Iran presented with multiple episodes of vomiting and low oral intake. The patient had a history of seizures and type II diabetes mellitus. On examination, the patient was afebrile; blood pressure was 120/70 mmHg, heart rate was 130/min, respiratory rate was 20/min, oxygen saturation was 98% at room air, and chest was clear bilaterally.

Abdominal ultrasonography revealed a borderline enlarged liver with a hypoechoic lesion measuring 6.7×6.1 cm in the portal confluence region involving segments 5, 6, and 7. Color Doppler imaging revealed mild color flow within the lesion. Magnetic resonance imaging (MRI) also revealed an enlarged liver (17 cm in size). A lesion with heterogeneous signal intensity showing areas of diffuse restriction measuring 8×7×6.7 cm was seen involving the right lobe of the liver. There was a mass effect on the central intrahepatic biliary tree with consequent non-visualization of the right and left main hepatic ducts, their confluence, and the proximal com-

mon hepatic duct. The proximal parts of the intrahepatic biliary radicles were observed within the lesion. Diffusion-weighted imaging and the corresponding apparent diffusion coefficient (ADC) images showed areas of diffusion restriction with low ADC values in and around the lesion involving the right hepatic lobe. In pre- and post-contrast mDIXON (T1W) studies, heterogeneous enhancement with a few cen-

tral non-enhancing areas was observed within the lesion. These findings were suggestive of hilar cholangiocarcinoma, and surgical resection was considered. Coronal post-contrast mDIXON images showed thickening and enhancement of the cecum and ascending colon and heterogeneously enhancing lesions in the liver (Fig. 1). A positron emission tomography-computed tomography (CT) scan showed an en-

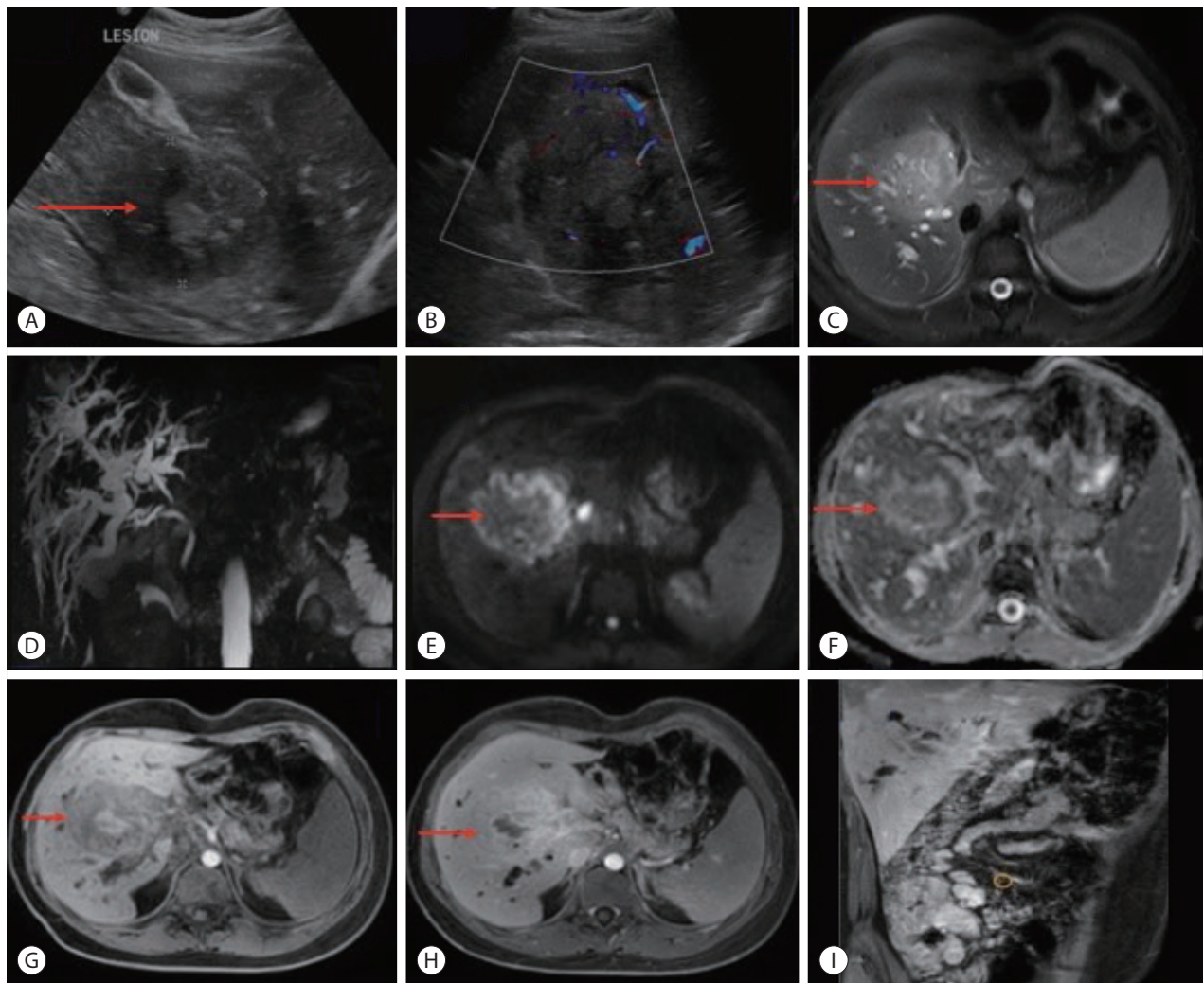


Figure 1. (A) An ultrasonography image shows a large hypoechoic lesion measuring 6.7×6.1 cm in the region of portal confluence involving segments 5, 6, and 7 of the liver (red arrow). (B) Color doppler reveals mild color flow within the lesion. (C) Transverse relaxation time fat-saturation magnetic resonance imaging of the liver demonstrates heterogeneously hyperintense signal intensity lesion (red arrow). (D) Magnetic resonance cholangiopancreatography sequence shows the mass effect with markedly dilated intrahepatic biliary radicles. (E, F) Diffusion-weighted imaging and corresponding ADC images show areas of diffusion restriction with low ADC in and around the lesion involving the right lobe of the liver (red arrows). On (G) pre- and (H) post-contrast mDIXON (T1W) studies, heterogeneous enhancement with few central non-enhancing areas was seen within the lesion (red arrows). These findings were suggestive of hilar cholangiocarcinoma. (I) Coronal post-contrast mDIXON images show thickening with an enhancement of the cecum, ascending colon, and heterogeneously enhancing lesion in the liver. ADC, apparent diffusion coefficient.

larged liver measuring 18 cm in the maximum craniocaudal extent. A large, fluorodeoxyglucose (FDG)-avid hypodense lesion was seen in the right lobe of the liver (segments 5-8), measuring approximately 7.0×8.0×6.4 cm. Ulceration with irregular thickening was observed in the cecum, distal ileum and ascending colon, with a maximum mural thickness of 1.5 cm. A few enlarged FDG-avid paracecal lymph nodes were

also noted, the largest measuring 1.9 cm along the short axis (Fig. 2).

Percutaneous transhepatic biliary drainage and liver biopsy were performed, and the biopsy specimen was sent for histopathological examination and fungal culture. The biopsy specimen was mostly composed of fibrocollagenous tissue with inflammatory infiltrates and granulomatous reactions.

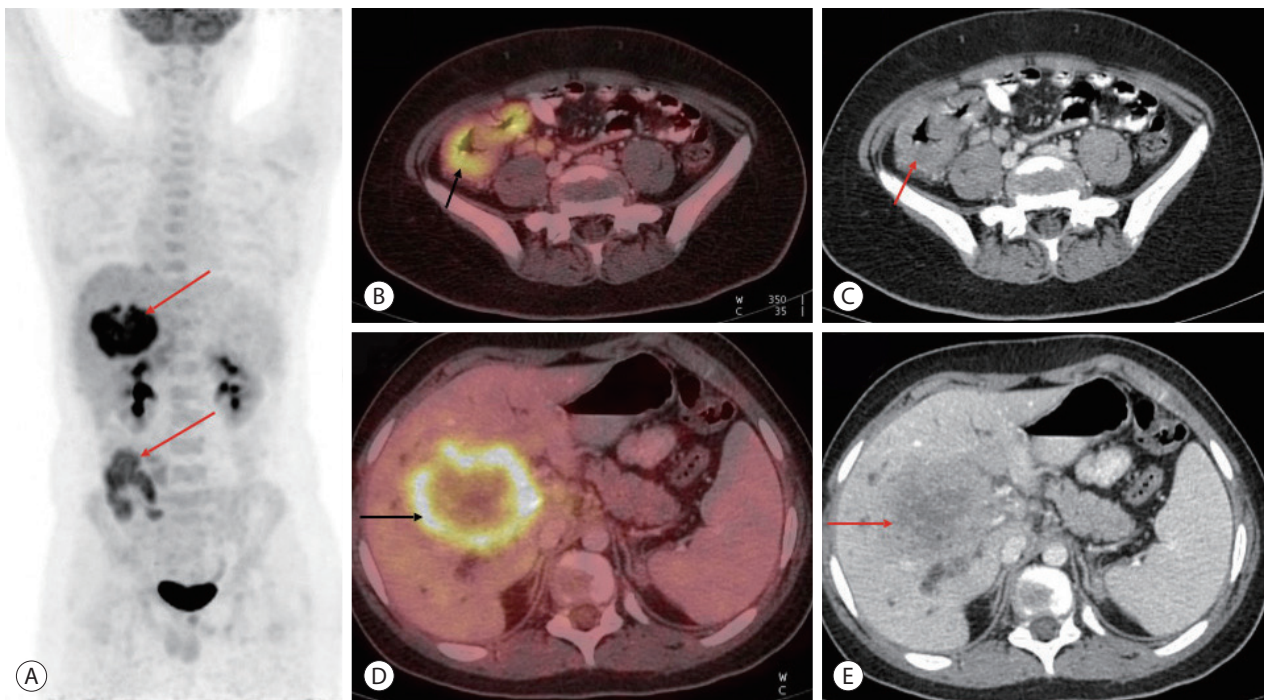


Figure 2. (A-C) Whole-body FDG positron emission tomography-computed tomography scan demonstrates FDG avid mass like ulcerated irregular thickening involving the cecum, distal ileum, and proximal ascending colon (red and black arrows) along with FDG avid paracecal lymph nodes. (D, E) A large, FDG-avid hypodense lesion showing heterogeneous post-contrast enhancement in the right lobe of the liver involving segments 5, 6, and 7 (red and black arrows) measuring approximately 7.0×8.0×6.4 cm in size. FDG, fluorodeoxyglucose.

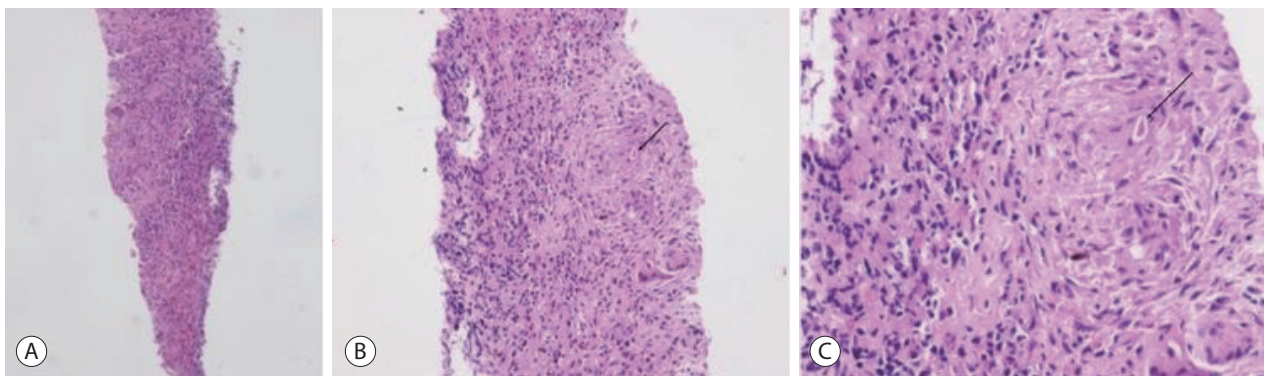


Figure 3. Liver biopsy shows mainly fibrocollagenous tissue with inflammatory infiltrate and granulomatous reaction. Fungal spores are noted within giant cells. (A) H&E (×4), (B) H&E (×10), and (C) H&E (×20). H&E, hematoxylin and eosin.

Fungal spores were observed within some giant cells (Fig. 3).

Colonoscopy revealed a deformed and edematous ascending colon and cecum, with ulcers measuring up to 1 cm in diameter (Fig. 4). Multiple biopsies were obtained from the ulcerated lesions. Histopathological examination revealed an ulcerated surface covered with an acute inflammatory exu-

date containing eosinophils. A Splendore-Hoepli phenomenon was observed around the fungal spores. Periodic acid-Schiff (PAS) and Grocott methenamine silver (GMS) stains highlighted the presence of fungal spores (Fig. 5).

Based on the histology and fungal culture studies, a final diagnosis of basidiobolomycosis was made. Thus, surgical

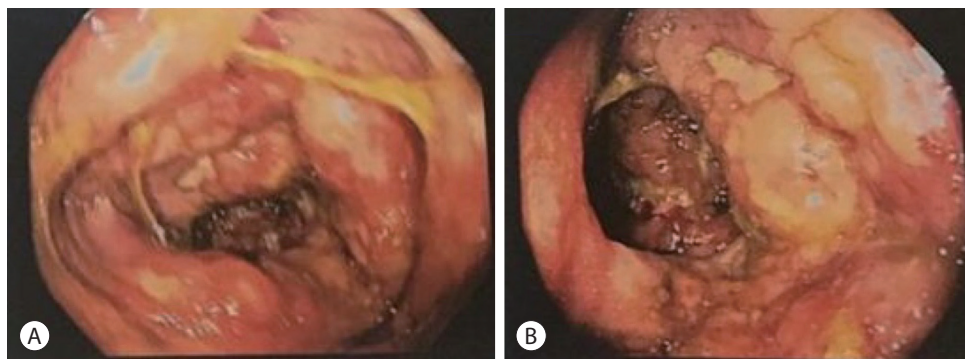


Figure 4. (A, B) Colonoscopy shows deformed, edematous ascending colon and cecum along with deep ulcers in the colon (measuring up to 1 cm in diameter).

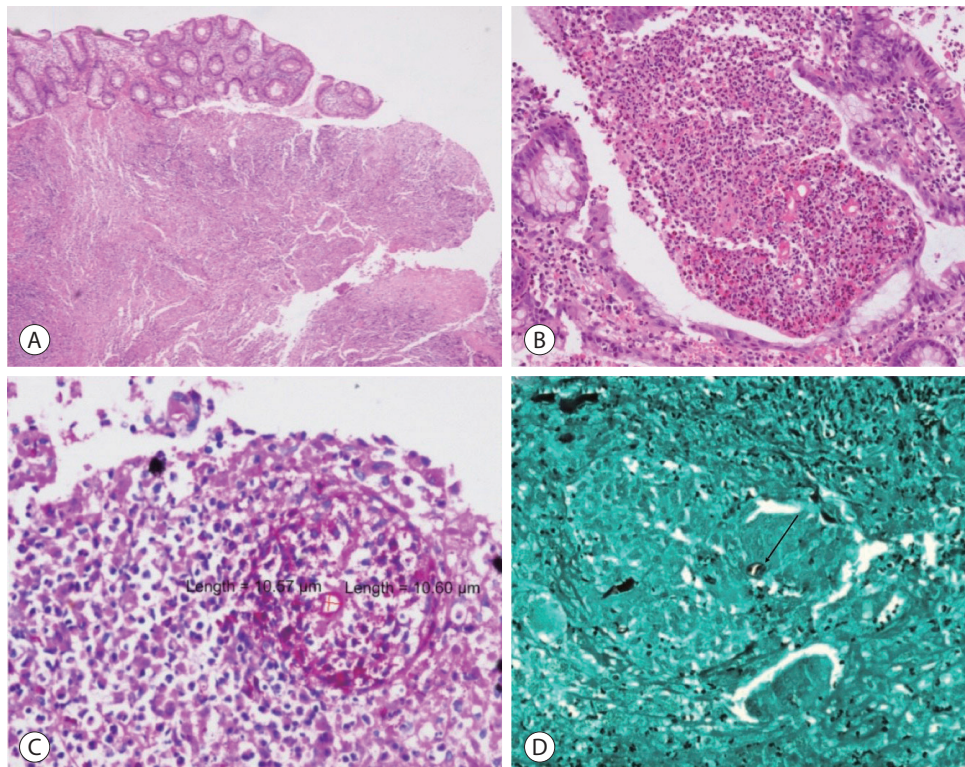


Figure 5. Section from colonic tissue biopsy shows an area of ulceration and a dense infiltrate of eosinophils. Splendore-Hoepli phenomenon noted around fungal spores. (A) H&E (×4), (B) H&E (×10). Periodic acid-Schiff (PAS) and Grocott methenamine silver (GMS) stains show fungal spores (black arrow) with Splendore-Hoepli phenomenon. (C) PAS (×20), (D) GMS (×10). H&E, hematoxylin and eosin.

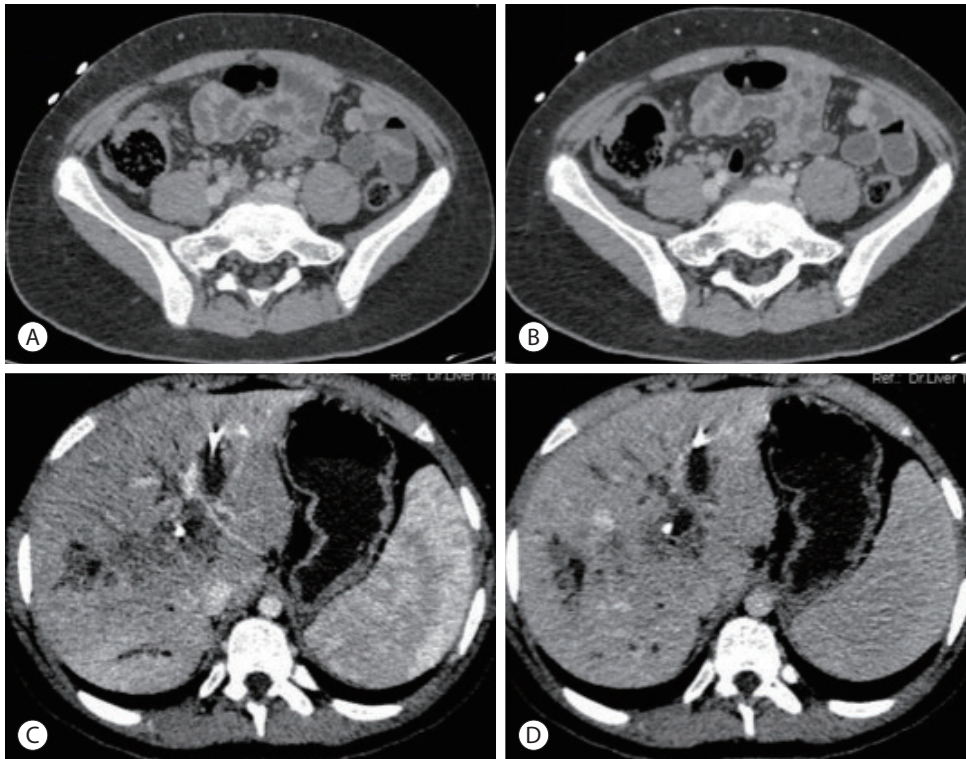


Figure 6. (A, B) The triphasic follow-up contrast-enhanced computed tomography scan demonstrates interval resolution of the irregular, ileocecal thickening and paracecal lymph nodes (porto-venous phase). (C) Arterial, (D) porto-venous phase. There was an interval reduction in the size of the liver lesions.

resection was deferred, and the patient was placed on oral voriconazole 6 mg/kg 12 hourly. The patient is doing currently well at 2 years follow-up visit. A multiphase follow-up contrast-enhanced CT scan demonstrated interval resolution of the irregular ileocecal thickening and paracecal lymph nodes. Moreover, there was an interval reduction in the size of hepatic lesions (Fig. 6).

DISCUSSION

B. ranarum is a saprophytic fungus found in soil, decomposing plant matter, animal waste, and manure. The mode of infection is through insect bites, contamination of wounds or food with soil, or use of contaminated toilet paper. A review suggested that the pathogenesis of basidiobolomycosis is due to the production of lipases and proteases by the fungus.^{1,2} Some possible risk factors include ranitidine, a known risk factor for bacterial gastroenteritis, which decreases acidi-

ty in the stomach, promoting the survival of the organisms. Another possible risk factor is chronic smoking.³ *B. ranarum* is known to cause subcutaneous mycoses; subcutaneous infections have been reported mainly in the pediatric population, characterized by firm, painless nodules in the limbs, trunk, perineum, and buttocks.¹

Only a handful of cases with liver and gastrointestinal involvement have been reported.^{4,5-15} The colon and rectum are the most frequently reported gastrointestinal sites, and most affected people are immunocompetent.¹⁶ Liver involvement occurs as part of a disseminated infection. Clinical features and radiological findings are often non-specific and therefore pose diagnostic challenges.

In a review, the most common abdominal CT scan finding was a colorectal mass in 48% of cases, followed by a liver mass in 30%.⁴ Differential diagnoses of colorectal masses include malignancy or Crohns disease in adults and tuberculosis or amebiasis in children.⁵ Histology and fungal culture help dis-

tinguish between these differentials. *B. ranarum* appears as a faintly stained, broad, sparsely septate pleomorphic fungus on GMS or PAS stains.³ The hyphae range from 5-20 μm in diameter, with a mean of 9 μm .¹ Hematoxylin and eosin-stained sections show the characteristic Splendore-Hoeppli phenomenon along with eosinophilic inflammation and zygospores. Splendore-Hoeppli phenomenon is caused by the deposition of eosinophilic and hyaline materials or inert substances around organisms. This eosinophilic material is an antigen-antibody complex deposited by inflammatory cells. They are commonly observed in fungal, bacterial, and parasitic infections, although they may sometimes be present in non-infective conditions such as allergic conjunctival granulomas and hypereosinophilic syndrome.⁶ Zygospores may appear similar to trophozoites of amebae, as they have prominent nucleoli and abundant foamy cytoplasm. Another close differential diagnosis is mucormycosis; this is associated with abundant neutrophilic infiltration unlike the eosinophilic infiltration of basidiobolomycosis, and also often demonstrates vascular invasion and necrosis. The possibility of eosinophilic gastroenteritis can be ruled out based on the presence of fungal hyphae. On culture, fungal colonies appear pale grey along with radial folds on Sabouraud agar after 2-3 days of incubation at

25-30 $^{\circ}\text{C}$.³

Hepatic involvement most commonly mimics a carcinoma; however, as in our case, histological examination and a fungal culture can easily help distinguish between these two. So far, 19 cases of basidiobolomycoses with hepatic involvement have been reported (Table 1).⁷⁻¹⁷ The patients' ages ranged from 23 months to 65 years, and the most common clinical presentations were abdominal pain, vomiting, weight loss, and, in some cases, an abdominal mass. The most common colonoscopic findings were obstructive masses involving the cecum and the colon. The most common CT/MRI findings were multiple lesions in the liver, along with a thickened and sometimes edematous intestinal wall. In many cases, cecal masses with or without ascending colon or terminal ileum involvement were noted. Frequent histological findings included eosinophilic infiltration, granuloma formation, the presence of broad aseptate/pauciseptate fungal elements, and Splendore-Hoeppli phenomenon. All patients received antifungal therapy, while surgery was performed in 15 patients. Most patients recovered on follow-up (16 cases), while two died of basidiobolomycosis-associated complications.

Basidiobolomycosis is a rare fungal infection which may also present with gastrointestinal and/or hepatic involve-

Table 1. Basidiobolomycosis with hepatic involvement: review of literature

Author	Year of publication	Number of cases	Type of lesion	Reference
Abduh et al.	2022	1	Cecal perforation along with liver involvement	7
Jafarpour et al.	2021	1	GI basidiobolomycosis with liver involvement	8
Omar Takrouni et al.	2019	1	Disseminated GI basidiobolomycosis along with hepatic abscess	5
Sanaei Dashti et al.	2018	1	Disseminated basidiobolomycosis with liver involvement	9
Zekavat et al.	2017	1	Colonic basidiobolomycosis with hepatic involvement	10
Geramizadeh et al.	2015	1	Isolated hepatic basidiobolomycosis	11
Ejtehadi et al.	2014	1	GI basidiobolomycosis along with liver involvement	13
Saeed et al.	2014	1	GI basidiobolomycosis along with liver dissemination	14
Hassan et al.	2013	1	Liver and GI mass	15
Al-Shanafey et al.	2012	9	Four patients had colonic and hepatic involvement, three had isolated hepatic lesions and two had disseminated infection	16
Van den Berk et al.	2006	1	Colon along with hepatic involvement	17

GI, gastrointestinal.

ment. As the clinical and radiological features are often non-specific or suggest the possibility of malignancy, as in this case, its possibility should be considered in the differential diagnosis, especially in endemic regions.

Conflict of Interest

The authors have no conflicts of interest to disclose.

Ethics Statement

The ethics committee of the authors' institution waived the need for ethics approval. Informed consent has been obtained from the patient.

Funding Statement

None.

Data Availability

Data sharing not applicable to this article as no datasets were generated or analyzed for this case report.

ORCID

Roopali Sehrawat <https://orcid.org/0000-0003-4275-9958>
Nalini Bansan <https://orcid.org/0000-0002-7640-7697>
Ajitabh Srivastava <https://orcid.org/0000-0002-8360-5464>
Dharmender Malik <https://orcid.org/0000-0003-3080-2330>
Vivek Vij <https://orcid.org/0000-0001-9582-7964>

Author Contribution

Conceptualization: RS, NB, AS, DM, VV
Data curation: RS, NB, AS, DM, VV
Formal analysis: RS, NB
Investigation: RS, NB, AS, DM, VV
Methodology: RS, NB
Project administration: NB
Resources: RS, NB, AS, DM, VV
Supervision: NB
Validation: NB
Visualization: RS, NB
Writing original draft: RS, NB
Writing review & editing: RS, NB
Approval of final manuscript: all authors

Acknowledgement

None.

References

1. Hussein MRA, Alqahtani AS, Alhagawi Y, Al Saglan NS, Albishi AM, Ahmed FO, et al. Primary basidiobolomycosis of the cecum in immunocompetent patients: two case reports. *Gastroenterology Res* 2021;14:116-124.
2. Gugnani HC. A review of zygomycosis due to *Basidiobolus ranarum*. *Eur J Epidemiol* 1999;15:923-929.
3. Lyon GM, Smilack JD, Komatsu KK, Pasha TM, Leighton JA, Guarnier J, et al. Gastrointestinal basidiobolomycosis in Arizona: clinical and epidemiological characteristics and review of the literature. *Clin Infect Dis* 2001;32:1448-1455.
4. Elzein F, Mursi M, Albarrag AM, Alfiar A, Alzahrani A. Disseminated angioinvasive basidiobolomycosis with a favourable outcome. *Med Mycol Case Rep* 2018;22:30-34.
5. Takrouni AO, Schammut MH, Al-Otaibi M, Al-Mulla M, Privitera A. Disseminated intestinal basidiobolomycosis with mycotic aneurysm mimicking obstructing colon cancer. *BMJ Case Rep* 2019;12:e225054.
6. Gopinath D. Splendore-Hoeppli phenomenon. *J Oral Maxillofac Pathol* 2018;22:161-162.
7. Abduh MS, Aldaqal SM, Almaghrabi J, Aljiffry MM, Elbadrawy HA, Alshahafi MA. A very rare basidiobolomycosis case presented with cecal perforation and concomitant hepatic involvement in an elderly male patient: a case study. *Int J Environ Res Public Health* 2022;19:3412.
8. Jafarpour Z, Pouladfar G, Dehghan A, Anbardar MH, Foroutan HR. Case report: gastrointestinal basidiobolomycosis with multi-organ involvement presented with intussusception. *Am J Trop Med Hyg* 2021;105:1222-1226.
9. Dashti AS, Nasimfar A, Khorami HH, Pouladfar G, Kadivar MR, Geramizadeh B, et al. Gastro-intestinal basidiobolomycosis in a 2-year-old boy: dramatic response to potassium iodide. *Paediatr Int Child Health* 2018;38:150-153.
10. Zekavat OR, Abdolkarimi B, Pouladfar G, Fathpour G, Mokhtari M, Shakibzadeh N. Colonic basidiobolomycosis with liver involvement masquerading as gastrointestinal lymphoma: a case report and literature review. *Rev Soc Bras Med Trop* 2017;50:712-714.
11. Geramizadeh B, Dashti AS, Kadivar MR, Kord S. Isolated hepatic basidiobolomycosis in a 2-year-old girl: the first case report. *Hepat Mon* 2015;15:e30117.
12. Flicek KT, Vikram HR, De Petris GD, Johnson CD. Abdominal imaging findings in gastrointestinal basidiobolomycosis. *Abdom Imaging* 2015;40:246-250.
13. Ejtehad F, Anushiravani A, Bananzadeh A, Geramizadeh B. Gas-

- trointestinal basidiobolomycosis accompanied by liver involvement: a case report. *Iran Red Crescent Med J* 2014;16:e14109.
14. Saeed MA, Al Khuwaitir TS, Attia TH. Gastrointestinal basidiobolomycosis with hepatic dissemination: a case report. *JMM Case Rep* 2014;1:e003269.
 15. Hassan HA, Majid RA, Rashid NG, Nuradeen BE, Abdulkarim QH, Hawramy TA, et al. Eosinophilic granulomatous gastrointestinal and hepatic abscesses attributable to basidiobolomycosis and fascioliasis: a simultaneous emergence in Iraqi Kurdistan. *BMC Infect Dis* 2013;13:91.
 16. Al-Shanafey S, AlRobean F, Bin Hussain I. Surgical management of gastrointestinal basidiobolomycosis in pediatric patients. *J Pediatr Surg* 2012;47:949-951.
 17. van den Berk GE, Noorduyn LA, van Ketel RJ, van Leeuwen J, Bemelman WA, Prins JM. A fatal pseudo-tumour: disseminated basidiobolomycosis. *BMC Infect Dis* 2006;6:140.