

[CASE REPORT]

Segmental Zoster Paresis Accompanied by Horner's Syndrome

Kenta Hanada^{1,2}, Yusuke Osaki², Koji Fujita², Tatsuya Fukumoto², Koji Fukushima²,
Hideki Kito¹ and Yuishin Izumi²

Abstract:

We herein report a 90-year-old immunocompromised woman who developed right upper limb weakness and right ptosis with a miotic pupil 1 week after oral therapy for zoster on the right T2 dermatome. The right pupil was dilated with instillation of 1% apraclonidine, indicating Horner's syndrome. The patient was treated with intravenous acyclovir and methylprednisolone. Focal weakness related to zoster, generally known as segmental zoster paresis, improved over five months, but Horner's syndrome remained. We suggest that aggressive intravenous treatment should be considered for rare cases of zoster that occur with a combination of these two neurological conditions.

Key words: segmental zoster paresis, Horner's syndrome, shingles, weakness, ptosis

(Intern Med 62: 2743-2746, 2023)

(DOI: 10.2169/internalmedicine.0578-22)

Introduction

Reactivation of varicella-zoster virus (VZV) leads to virus replication followed by zoster (also referred to as shingles), which triggers a painful skin rash. Zoster incidence increases with age due to declining cell-mediated immunity (1). This disease has also shown a recent increase in the population due to the growing numbers of organ transplant recipients and patients receiving chemotherapy for cancer and immunosuppressants for autoimmune diseases (2).

Reactivation of VZV also produces several acute, sub-acute, and chronic neurological conditions with or without skin rash. One of the most frequent neurological conditions is postherpetic neuralgia (PHN). Other relatively rare neurological complications have also been reported, including cerebral vasculopathy, encephalitis, cranial neuropathies, myelopathy, and segmental weakness (1). Segmental weakness, referred to as segmental zoster paresis (SZP), sometimes occurs during or after a painful skin rash (3, 4). As the number of patients with zoster increases, these neurological complications may become more common.

Horner's syndrome is a combination of symptoms, includ-

ing miosis, ptosis and facial anhidrosis, attributed to dysfunction of the oculosympathetic pathway (5, 6). Depending on the site of the impaired three-neuron pathways, Horner's syndrome is classified into central, intermediate, and post-ganglionic cases (7). The diagnosis of Horner's syndrome is based on taking a detailed clinical history and on clinical signs, followed by adjunctive pharmacological testing and diagnostic imaging (7). Pharmacological tests have commonly used eyedrops of cocaine and hydroxyamphetamine; however, the availability of these two agents is limited. Apraclonidine, an alpha-2 agonist that is used clinically for reducing ocular pressure, is an alternative and more available diagnostic agent that reverses anisocoria due to denervation hypersensitivity of adrenergic receptors in the iris dilator muscle (8). Horner's syndrome is also a rare complication of zoster (9).

SZP commonly shows a good prognosis for muscle weakness (3), but a few cases with a combination of SZP and Horner's syndrome have been reported in which muscle weakness showed a poor recovery (10-12). We herein report an elderly immunocompromised woman who presented with a rare combination of SZP and Horner's syndrome. Complete recovery of muscle weakness was achieved, despite the

¹Naka Municipal Kaminaka Hospital, Japan and ²Department of Neurology, University of Tokushima Graduate School of Biomedical Sciences, Japan

Received for publication June 28, 2022; Accepted for publication December 27, 2022

Correspondence to Yusuke Osaki, yosaki@tokushima-u.ac.jp

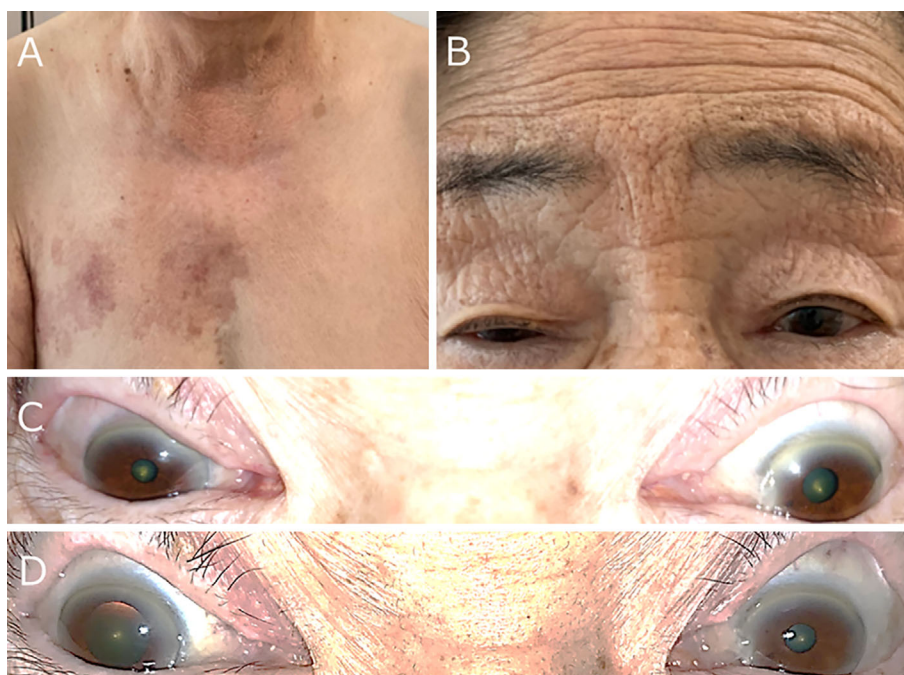


Figure. Dermatological and neurological findings. (A) Healed herpes zoster rash on the right T2 dermatome. (B) Narrowing of the palpebral fissure on the right side. (C) Miosis of the right eye. (D) Reversal of anisocoria after instillation of 1% apraclonidine into both eyes.

combination of the two zoster complex syndromes.

Case Report

A 90-year-old woman visited our clinic with a tender blistering rash on the right T2 dermatome and ipsilateral ptosis. She was diagnosed with zoster and treated with oral valacyclovir. One week later, she could not open the lid of a plastic bottle with her right hand, and one month later, she was admitted to our hospital. She had rheumatoid arthritis and took 7.5 mg/day prednisolone.

On a physical examination, a healed herpes zoster rash was seen on the right T2 dermatome (Figure A). The right eye showed narrowing of the palpebral fissure with a miotic pupil (Figure B, C). Instillation of 1% apraclonidine into both eyes showed reversal of anisocoria and confirmed the diagnosis of Horner's syndrome; the pupil-diameter ratios of right to left before and after instillation were 3:4 and 2:1, respectively (Figure D). Hydroxyamphetamine eyedrops were not used because of the limitations associated with the use of this drug. The patient complained of paresthesia on the skin of the whole hand and forearm and the medial half of the arm on the right. The extensor carpi radialis brevis, abductor pollicis brevis, and first dorsal interossei muscles of the right hand were weak, and the right biceps and triceps tendon reflexes were reduced. There were no other neurological abnormalities, including meningeal irritation signs, cognitive impairment, impaired cranial nerves, long tract signs, or autonomic deficits.

Blood tests showed an elevated serum level of C-reactive protein (3.3 mg/dL), an accelerated erythrocyte sedimenta-

tion rate (35 mm/h), and positive serum immunoglobulin G (IgG) antibodies against VZV. A cerebrospinal fluid (CSF) analysis showed a mildly increased white blood cell count (6 cells/ μ L; monocytes, 100%) and normal sugar and protein levels. Bacterial cultures were negative. VZV DNA was not detected in CSF using a polymerase chain reaction. Anti-VZV IgG in CSF was positive (0.52 by enzyme immunoassay), whereas anti-VZV IgM was negative. There were no abnormal findings in the radicles or spinal cord between the cervical and upper thoracic levels on magnetic resonance imaging (MRI), including T2-weighted imaging and gadolinium-enhanced T1 imaging. Cervicothoracic computed tomography and brain MRI did not reveal a lesion causing Horner's syndrome.

The patient was diagnosed with SZP affecting the C6 to T1 innervating muscles and Horner's syndrome. She was treated with intravenous acyclovir 500 mg every 12 h for 14 days, followed by oral valacyclovir 1 g three times for 1 week. We also considered treatment with a recommended regimen of an initial short course of oral prednisone 1 mg/kg (13). Since the patient became tired and anorexic due to the severe pain, intravenous methylprednisolone 40 mg/day was administered for the first 5 days. At the last visit five months later, her muscle weakness had recovered completely, but Horner's syndrome persisted.

We obtained appropriate written consent for the publication of this article from the patient.

Discussion

We described the case of an elderly woman with SZP

Table. Reported Cases of Segmental Zoster Paresis Complicated by Horner's Syndrome.

Reference number	Age (y)/ Sex	Dermatome	Treatment	Muscle weakness	Horner's syndrome
(10)	79/M	C7-T1	Oral acyclovir	Persisted after 3 years	Persisted after 3 years
	79/F	C8-T1	Oral famciclovir	Persisted after 10 months	Persisted after 10 months
(11)	85/F	T1-T2	Not reported	Persisted after 10 weeks	Persisted after 10 weeks
(12)	63/F	C6-8	Antiviral drugs (described as "at a local clinic" with no further information) and intravenous methylprednisolone	Not reported	Not reported
Present case	90/F	T2	Intravenous acyclovir and methylprednisolone	Improved after 5 months	Persisted after 5 months

M: male, F: female

complicated by Horner's syndrome. The patient presented with a herpes zoster rash in the T1-T2 region of her right chest to arm and ptosis on the right side. She received oral valacyclovir but developed SZP. After intravenous administration of acyclovir and methylprednisolone, her muscle weakness improved over several months.

An epidemiological study found that SZP occurs in 2.5-3.5% of patients with zoster (14). However, we found no data concerning the incidence of Horner's syndrome in patients with zoster. To our knowledge, only four cases with complications of SZP and Horner's syndrome have been reported (Table) (10-12).

SZP is characterized clinically by focal, asymmetric neurogenic weakness affecting the upper limbs or other parts (3, 4). The anatomical regions involved in SZP may be the anterior or posterior spinal roots or horns, or the brachial plexus (1).

The prognosis of SZP is generally thought to be favorable without any treatment. Before acyclovir was approved for medical use in 1981, 2 case series showed a good prognosis: Gupta et al. reported near-complete recovery in 14 of 18 cases, and Thomas and Howard reported complete recovery in 30 of 54 cases (3, 15). In contrast to the excellent prognosis of patients with simple SZP, those complicated with Horner's syndrome may show an unfavorable outcome. In all three traceable cases among the four previous reports, muscle weakness persisted throughout the follow-up period. The reactivated zoster virus may invade more proximally in patients with a combination of Horner's syndrome and SZP than in those with simple SZP. SZP can occur via viral expansion through the brachial plexus from the dorsal root ganglion. In contrast, in Horner's syndrome, the virus probably expands through the spinal cord or anterior roots, rather than the brachial plexus, because sympathetic nerves separate from the anterior roots proximal to the brachial plexus. Such differences in the viral expansion route may cause different prognoses. In the present case, muscle weakness completely recovered, while Horner's syndrome did not. This is probably because the zoster virus disrupted the gray matter involving the second neurons of the oculosympathetic pathway.

None of the four previously reported cases with a combi-

nation of SZP and Horner's syndrome received intravenous acyclovir (Table) (10-12). In contrast, the present case was treated with intravenous acyclovir and showed a favorable course of motor dysfunction. Acyclovir has about 15-30% oral bioavailability, which decreases with higher doses (16). Therefore, patients with zoster myelitis, in which viral replication in the central nervous system may play an important role, need to be treated with intravenous acyclovir (17). The same approach should be applied to SZP with Horner's syndrome, since there is a high possibility of proximal invasion, even if imaging tests fail to detect spinal cord lesions.

In conclusion, SZP with Horner's syndrome is a neurological complication seen in patients with zoster. Such cases have not been well documented, but aggressive intravenous antiviral therapy should be considered in these cases.

The authors state that they have no Conflict of Interest (COI).

References

- Kennedy PGE, Gershon AA. Clinical features of varicella-zoster virus infection. *Viruses* **10**: 609, 2018.
- Yawn BP, Saddier P, Wollan PC, St. Sauver JL, Kurland MJ, Sy LS. A population-based study of the incidence and complication rates of herpes zoster before zoster vaccine introduction. *Mayo Clin Proc* **82**: 1341-1349, 2007.
- Thomas JE, Howard FM. Segmental zoster paresis - a disease profile. *Neurology* **22**: 459-466, 1972.
- Merchut MP, Gruener G. Segmental zoster paresis of limbs. *Electromyogr Clin Neurophysiol* **36**: 369-375, 1996.
- Loewenfeld IE. Mechanisms of reflex dilatation of the pupil; historical review and experimental analysis. *Doc Ophthalmol* **12**: 185-448, 1958.
- Ross IB. The role of Claude Bernard and others in the discovery of Horner's syndrome. *J Am Coll Surg* **199**: 976-980, 2004.
- Davagnanam I, Fraser CL, Miszkiel K, Daniel CS, Plant GT. Adult Horner's syndrome: a combined clinical, pharmacological, and imaging algorithm. *Eye (Basingstoke)* **27**: 291-298, 2013.
- Mughal M, Longmuir R. Current pharmacologic testing for Horner syndrome. *Curr Neurol Neurosci Rep* **9**: 384-389, 2009.
- Henry M, Johnson C, Ghadiali L, Raiji V. Horner's syndrome following varicella vaccination. *Neuro-Ophthalmology* **44**: 267-269, 2020.
- Gabriel CM, Gale AN, Rossor MN. Zoster paresis with Horner's syndrome. *J Neurol* **250**: 1492-1493, 2003.
- Tobin WO, Spencer BR, Demaerschalk BM. Herpes zoster in the

- T1 dermatome presenting with Horner's syndrome, radicular weakness, and postherpetic neuralgia. *Int Med Case Rep J* **1**: 1-2, 2008.
12. Oh SI. Horner's syndrome and segmental sympathetic denervation following herpes zoster brachial plexopathy. *J Clin Neurol (Korea)* **17**: 328-329, 2021.
 13. Kennedy PGE. Issues in the treatment of neurological conditions caused by reactivation of varicella zoster virus (VZV). *Neurotherapeutics* **13**: 509-513, 2016.
 14. Elliott KJ. Other neurological complications of herpes zoster and their management. *Ann Neurol* **35**: S57-S61, 1994.
 15. Gupta SK, Helal BH, Kiely P. The prognosis in zoster paralysis. *J Bone Joint Surg Br* **51**: 593-603, 1969.
 16. Robert Blum M, Liaq SHT, de Miranda P. Overview of acyclovir pharmacokinetic disposition in adults and children. *Am J Med* **73**: 186-192, 1982.
 17. Dworkin RH, Johnson RW, Breuer J, et al. Recommendations for the management of herpes zoster. *Clin Infect Dis* **44**: S1-S26, 2007.

The Internal Medicine is an Open Access journal distributed under the Creative Commons Attribution-NonCommercial-NoDerivatives 4.0 International License. To view the details of this license, please visit (<https://creativecommons.org/licenses/by-nc-nd/4.0/>).