


COVID-19 as the cause of thrombosis: recognising COVID-19 infection in apparently asymptomatic patients

Kyle B Varner,^{1,2} Emily J Cox ³

¹Hospitalist, Providence Holy Family Hospital, Spokane, Washington, USA

²Hospitalist, Providence Sacred Heart Medical Center, Spokane, Washington, USA

³Providence Medical Research Center, Providence Health Care, Spokane, Washington, USA

Correspondence to

Dr Kyle B Varner;
Kyle.Varner@providence.org

Accepted 14 December 2020

SUMMARY

COVID-19 has serious thrombotic complications in critically ill patients; however, thrombus is not a typical presenting symptom. This case report describes a patient with no respiratory symptoms who presented to the emergency department with abdominal pain. The pain was attributed to renal thrombosis, but the patient was found to have no risk factors for thrombotic disease and subsequent hypercoagulable work-up was unremarkable. Pulmonary manifestations of COVID-19 infection were detected incidentally on the abdominal CT scan and confirmed via PCR test. The patient was isolated and went on to develop mild respiratory failure secondary to COVID-19 infection. This case suggests that unexplained thrombus in otherwise asymptomatic patients can be a direct result of COVID-19 infection, and serves as a call to action for emergency department clinicians to treat unexplained thrombotic events as evidence of COVID-19.

BACKGROUND

COVID-19 is best known as a pulmonary disease. In reality, however, COVID-19 is now known to have deleterious effects on multiple organ systems, which render its initial presentation highly variable. Presenting symptoms of COVID-19 reported to date in otherwise ‘asymptomatic’ patients (ie, patients without reported respiratory symptoms) include diarrhoea, vomiting, loss of appetite and skin lesions.^{1,2} Although COVID-19 infection is a hypercoagulable state³ and thrombotic complications occur in about one-third of critically ill patients with COVID-19,⁴ thrombus is not typically a presenting symptom. Here we present a case in which abdominal pain due to a renal thrombosis was the initial presentation of a patient with COVID-19 who initially did not report other symptoms.

CASE PRESENTATION

A 46-year-old man without significant medical history presented to our emergency room (ER) with sudden-onset right low quadrant abdominal pain. He reported that he was in his usual state of health and was awakened from sleep at approximately 03:00 with dull abdominal pain of 3 out of 10. He had an associated episode of diarrhoea. He presented to an urgent care the next morning and was immediately referred to the ER.

INVESTIGATIONS

A contrast-enhanced CT scan of the abdomen and pelvis demonstrated occlusive thrombus involving

the right renal artery branch supplying the anterior right kidney. The CT scan demonstrated an associated large right-sided renal infarct that involved greater than 50% of the right kidney (figure 1). Incidentally noted were peripheral ground-glass opacities in the mid and lower lungs. Follow-up CT of the chest with contrast demonstrated multifocal patchy ground-glass opacities throughout both lungs (figure 2). A full hypercoagulability work-up was drawn and the patient was started on a heparin drip and admitted to the hospital.

DIFFERENTIAL DIAGNOSIS

A focused history elicited possible low-grade fever on the day prior to admission and mild cough symptoms. These important historical features were elicited in our ER only after incidental CT findings prompted additional questioning, and were only reluctantly and equivocally endorsed by the patient, rather than constituting a central part of the patient’s chief complaint. PCR testing for COVID-19 was positive on the evening of admission. The patient denied any known sick contacts.

TREATMENT

During the patient’s stay in the ER he developed mild hypoxic respiratory failure, which progressed through the course of his hospitalisation to a 4L oxygen requirement. He was started on remdesivir and dexamethasone, and his anticoagulation was switched to low molecular weight heparin. The patient gradually improved and was discharged home in stable and satisfactory condition after 6 days of hospitalisation.

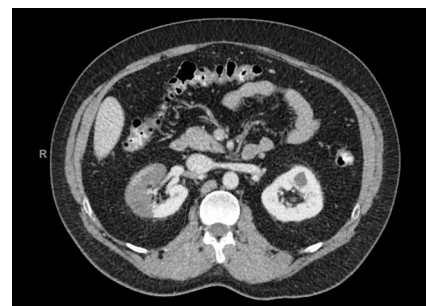
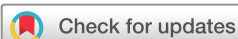

Figure 1 Contrast-enhanced CT scan of the abdomen and pelvis in a patient with COVID-19. An occlusive thrombus involving the right renal artery branch supplying the anterior right kidney (arrow). The thrombus resulted in a large right-sided renal infarct that involved greater than 50% of the right kidney.



© BMJ Publishing Group Limited 2021. No commercial re-use. See rights and permissions. Published by BMJ.

To cite: Varner KB, Cox EJ. *BMJ Case Rep* 2021;**14**:e241027. doi:10.1136/bcr-2020-241027

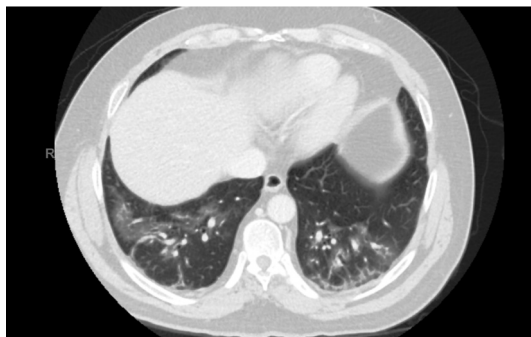


Figure 2 Contrast-enhanced CT of the chest. Multifocal patchy ground-glass opacities throughout both lungs in a patient with COVID-19 who presented with a renal infarction.

OUTCOME AND FOLLOW-UP

The patient was discharged home to recover and complete a 6-month course of apixaban.

DISCUSSION

This case highlights the importance of a high degree of vigilance for thrombotic complications as potential signs of COVID-19 infection. Our patient was not acutely ill or hospitalised and reported no respiratory symptoms of COVID-19 when he developed a potentially life-threatening arterial thrombosis. Had the initial CT scan not serendipitously noted the ground-glass opacities in this patient's lung bases, it is likely that his diagnosis would have been significantly delayed. COVID-19-specific therapy and special pathogen-appropriate isolation would have both been delayed, potentially contributing to staff exposures and a poor patient outcome.

COVID-19 was not initially suspected in this patient for several reasons: the patient's clinical presentation in the ER was not initially consistent with typical presentations for COVID-19, he was not aware of any exposure to individuals infected with COVID-19, and he did not develop respiratory failure until late in his ER stay. Later, a focused history based on the incidental CT findings revealed that the patient may have had a low-grade fever and a mild cough the day prior to admission, although these symptoms were sufficiently mild that they were not initially reported.

To our knowledge, this is the second report of a renal thrombus attributed to COVID-19 infection.⁵ Our case is differentiated from the prior case in that all results from the hypercoagulable work-up were negative and our patient was otherwise healthy prior to this event. These negative results also differentiate this case from others in which thrombotic events are attributable to the development of lupus anticoagulant or other prothrombotic factors secondary to COVID-19 infection.³ In turn, this finding suggests that COVID-19 infection can induce coagulation independent of the prothrombotic intermediaries tested on hypercoagulable work-ups. It is also worth noting that a potential paradigm for the cause of COVID-19-related thrombus has been proposed, which may explain the development of thrombus in critically ill patients.⁶ Once again, however, the case described

Learning points

- ▶ Arterial thrombosis can be an initial presentation of COVID-19.
- ▶ Patients with unremarkable hypercoagulability work-up may nevertheless be at risk for arterial thrombosis during COVID-19 infection.
- ▶ Antithrombotic therapy may be needed for patients with COVID-19 who are not otherwise at risk for arterial thrombosis.

here is clearly different in that the patient seemed to be asymptomatic on initial presentation, only developed mild respiratory failure after presentation and had no typical evidence of a hypercoagulable state. We propose that high-quality clinical trials are urgently needed to assess anticoagulation strategies for both treatment and prevention of these complications in patients with COVID-19 infection, as the problem may extend even to non-hospitalised and non-critically ill patients.

Based on this case, we recommend that ER clinicians and hospitalists exercise vigilance in checking for COVID-19 infection in any patients presenting with unexplained thrombotic events, even if they deny other symptoms or confirmed contacts. Recognition of thrombosis as a potential initial sign of COVID-19 infection is critical for timely isolation and initiation of COVID-19 therapies.

Contributors KBV contributed to data collection, writing and revising the manuscript. EC contributed to writing and revising the manuscript.

Funding The authors have not declared a specific grant for this research from any funding agency in the public, commercial or not-for-profit sectors.

Competing interests None declared.

Patient consent for publication Obtained.

Provenance and peer review Not commissioned; externally peer reviewed.

This article is made freely available for use in accordance with BMJ's website terms and conditions for the duration of the covid-19 pandemic or until otherwise determined by BMJ. You may use, download and print the article for any lawful, non-commercial purpose (including text and data mining) provided that all copyright notices and trade marks are retained.

ORCID iD

Emily J Cox <http://orcid.org/0000-0003-3929-3317>

REFERENCES

- 1 Parasa S, Desai M, Thoguluva Chandrasekar V, *et al*. Prevalence of gastrointestinal symptoms and fecal viral shedding in patients with coronavirus disease 2019: a systematic review and meta-analysis. *JAMA Netw Open* 2020;3:e2011335.
- 2 Wollina U, Karadağ AS, Rowland-Payne C, *et al*. Cutaneous signs in COVID-19 patients: a review. *Dermatol Ther* 2020;33:e13549.
- 3 Bowles L, Platten S, Yartey N, *et al*. Lupus anticoagulant and abnormal coagulation tests in patients with Covid-19. *N Engl J Med* 2020;383:288–90.
- 4 Klok FA, Kruip MJHA, van der Meer NJM, *et al*. Incidence of thrombotic complications in critically ill ICU patients with COVID-19. *Thromb Res* 2020;191:145–7.
- 5 Philipponnet C, Aniot J, Chabrot P, *et al*. Renal artery thrombosis induced by COVID-19. *Clin Kidney J* 2020;13:713.
- 6 Du F, Liu B, Zhang S. COVID-19: the role of excessive cytokine release and potential ACE2 down-regulation in promoting hypercoagulable state associated with severe illness. *J Thromb Thrombolysis* 2020. doi:10.1007/s11239-020-02224-2. [Epub ahead of print: 16 Jul 2020].

Copyright 2020 BMJ Publishing Group. All rights reserved. For permission to reuse any of this content visit <https://www.bmj.com/company/products-services/rights-and-licensing/permissions/>
BMJ Case Report Fellows may re-use this article for personal use and teaching without any further permission.

Become a Fellow of BMJ Case Reports today and you can:

- ▶ Submit as many cases as you like
- ▶ Enjoy fast sympathetic peer review and rapid publication of accepted articles
- ▶ Access all the published articles
- ▶ Re-use any of the published material for personal use and teaching without further permission

Customer Service

If you have any further queries about your subscription, please contact our customer services team on +44 (0) 207111 1105 or via email at support@bmj.com.

Visit casereports.bmj.com for more articles like this and to become a Fellow