

## Case report

## Erythema nodosum as a cutaneous manifestation of COVID-19 infection

Philipp Suter , Blandine Mooser, Hoa Phong Pham Huu Thien

Department of Internal  
Medicine, HFR Fribourg Hospital  
cantonal, Fribourg, Switzerland

**Correspondence to**  
Dr Philipp Suter;  
philipp.suter@gmx.ch

Accepted 28 June 2020

**SUMMARY**

Erythema nodosum (EN) is a common dermatological manifestation with many different aetiologies. Often however, the aetiology remains unidentified. We present here a 42-year-old male patient with an EN that is due to an acute COVID-19 infection. Most of the usual aetiologies were excluded by laboratory testing and imaging studies. This case is, to our knowledge, the first report of this cutaneous manifestation in the context of a COVID-19 infection. The EN was successfully treated with the disappearance of the COVID-19 infection and topical corticosteroids.

**BACKGROUND**

Erythema nodosum (EN), an inflammatory condition of the subcutaneous fat, is the most common type of panniculitis. It is classically characterised by painful violaceous nodules, typically symmetrically on pretibial surfaces. It has acute onset.<sup>1</sup> Systemic symptoms such as fever, arthralgia, headache and generalised weakness may be associated.<sup>1</sup> Exact pathogenesis remains unclear, but most evidence supports the involvement of a type IV delayed hypersensitivity response to various antigens.<sup>2</sup> EN is a dermatological presentation of many diseases including infections, sarcoidosis, neoplastic or inflammatory diseases. Up to 55% of cases may be idiopathic.<sup>3</sup> Men seem to be less affected than women, with a ratio of 1:6, and the disease occurs mostly between the second and fourth decades of life even though all ages may be concerned.<sup>1</sup>

**CASE PRESENTATION**

A 42-year-old Swiss man presented with 15 days of fever, headache, severe fatigue and 7 days of dry cough. He had noted 3 days ago that the eruption of painful tender violaceous lesions on both shins, which motivated an emergency department consultation. The patient worked as a banker and had no known comorbidity, medication or allergy. The review of systems did not uncover relevant elements. The physical examination only revealed cutaneous lesions on both shins (figures 1 and 2).

**INVESTIGATIONS**

The laboratory findings showed elevated inflammatory markers, lymphopenia, inflammatory anaemia and an elevated ferritin associated with abnormal liver function tests. An elevated erythrocyte sedimentation rate was observed. Considering the COVID-19 epidemic and the suggestive

symptoms, a nasopharyngeal swab was performed, and a COVID-19 infection confirmed by reverse transcription (RT)-PCR. An extensive infectious panel that included blood cultures, a viral hepatitis workup and HIV screening was negative. The immunological panel testing for vasculitis and connective tissue diseases was also negative. Antistreptolysin antibodies were undetectable. The immunofixation electrophoresis showed small monoclonal IgA lambda and IgG lambda strips interpreted as non-significant. The Interferone (IFN)-gamma release assay was not interpretable due to the lymphopenia and the fact that there were insufficient lymphocytes to stimulate with the phytohaemagglutinin.

The initial chest radiography was interpreted as normal for the age. The chest CT showed several micronodular and centronodular lesions located predominantly at the superior and medial pulmonary lobes, which were interpreted as ground-glass opacifications (figure 3). Sarcoidosis and tuberculosis were excluded by our pneumologists after consultation and interpretation of imaging.

Despite the introduction of broad-spectrum antibiotics, the patient continued to experience fever spikes (with the highest value at 39°C). Our dermatologist found the pink, blanching, tender subcutaneous nodules on both shins to be most consistent with EN. No skin biopsy was performed due to the high clinical suspicion.

**TREATMENT**

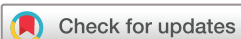As the patient still reported severe lower leg pain during his hospitalisation, betamethasone cream was prescribed, compression stockings of the lower extremities were added and analgesia by paracetamol and tramadol was introduced. Systemic anti-inflammatory drugs and systemic corticoids were contraindicated in the COVID-19 context.

**OUTCOME AND FOLLOW-UP**

Dermatological symptoms disappeared almost completely after 2 weeks of local treatment. Pain medication was weaned. The patient was discharged from the hospital 9 days after admission.

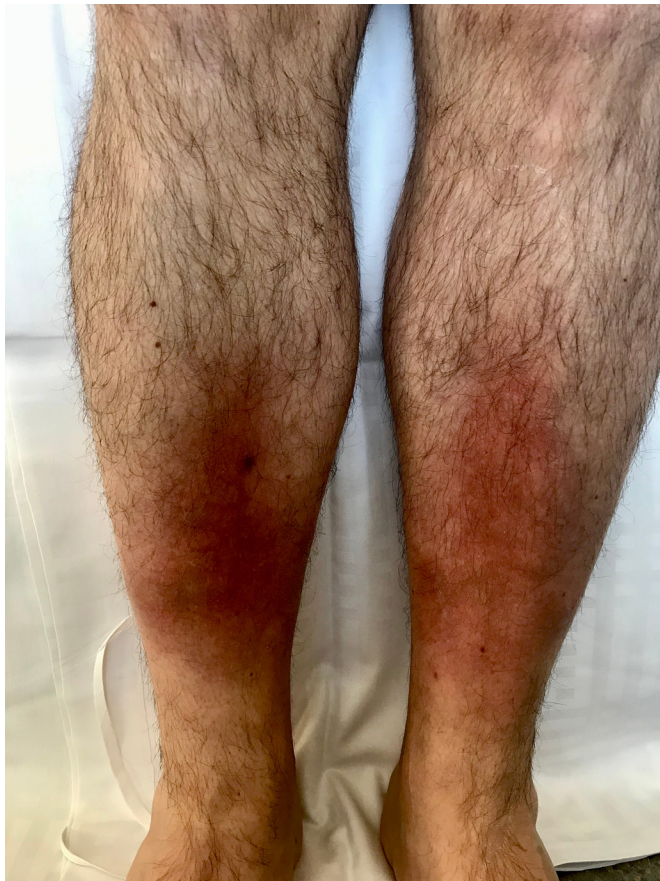**DISCUSSION**

Viral infection is commonly identified as the aetiology of EN and mainly includes infectious mononucleosis, hepatitis B and C, HIV, herpes simplex virus and Epstein-Barr virus, which have been extensively described in the literature.<sup>4</sup> Streptococcal infections and paravaccinia virus are other common aetiologies.<sup>4</sup>

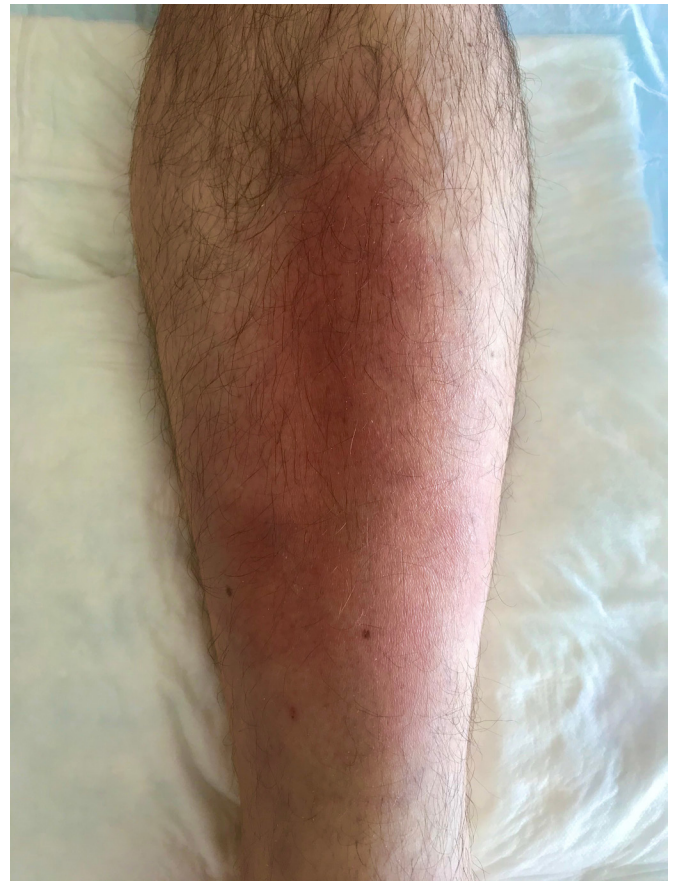

© BMJ Publishing Group Limited 2020. No commercial re-use. See rights and permissions. Published by BMJ.

**To cite:** Suter P, Mooser B, Pham Huu Thien HP. *BMJ Case Rep* 2020;**13**:e236613. doi:10.1136/bcr-2020-236613



**Figure 1** Erythema nodosum on both shins during hospitalisation.



**Figure 2** Erythema nodosum on the left leg at end of hospitalisation.

In the currently available literature, there is little research on skin manifestations associated with COVID-19. Recalcati has postulated a cutaneous involvement similar to that found in common viral infections, in 20.4% of patients among their cohort of 88 patients. The described cutaneous manifestations included erythematous rash, widespread urticaria and chickenpox-like vesicles.<sup>5</sup> Two cases of transient unilateral livedo reticularis were also reported by Manalo *et al* as a manifestation of COVID-19 thought to be due to a microembolic event.<sup>6</sup> Progressing pruritic lesions on both heels that became erythematous plaques were also described in a 28-year-old healthy woman.<sup>7</sup> In another case report, petechiae was described in a Thai patient, which could be wrongly interpreted as dengue.<sup>8</sup>

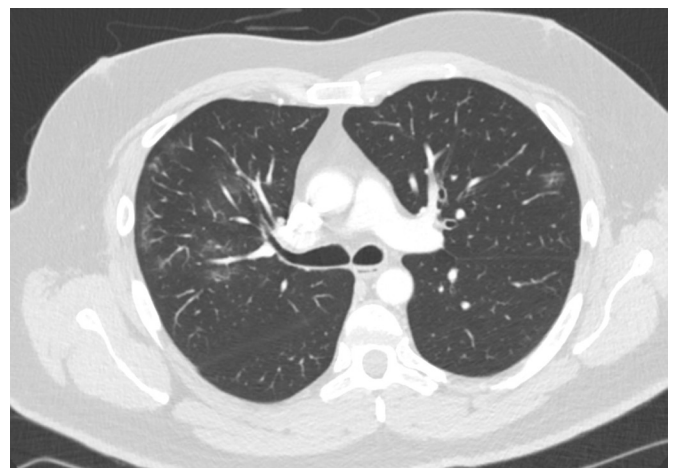
Our patient's clinical presentation was typical of a COVID-19 infection which was confirmed by RT-PCR. Because of the typical dermatological presentation of erythematous plaques on both shins with a nodular aspect at palpation, the frequent aetiologies of EN were tested but finally no trigger was found. Due to the high clinical suspicion, a skin biopsy was unnecessary and the diagnosis of EN in a context of infection with COVID-19 was retained by our specialists. The patient was treated with a topical corticosteroids and compression stockings. A slow improvement of the symptoms was observed.

EN remains a self-limiting condition and usually resolves within a few weeks, although the exact aetiology frequently remains unidentified and untreated. General measures such as resting, raising the legs and compression stockings are usually suggested. In case of discomfort or extensive skin lesions, NSAIDs are the most commonly prescribed.<sup>9</sup> When patients fail to respond to non-steroidal anti-inflammatory drugs (NSAIDs), second-line therapy may be systemic glucocorticoids, provided

there is no contraindication to their use. If EN lesions are limited in number, local corticosteroid therapy is an alternative treatment. In chronic cases, steroid-sparing treatment such as dapson, colchicine or hydroxychloroquine may be alternative agents.<sup>3</sup>

Even without specific treatment for COVID-19, the evolution of EN in this context probably follows a satisfactory clinical course and remains self-limited. However, NSAIDs are not currently recommended for COVID-19 infection.

The distinctive feature of our case was this young patient without medical history presenting a cutaneous inflammatory manifestation associated with fever, cough and shortness of



**Figure 3** Chest CT with typical COVID-19 infiltrations.

breath in the context of a COVID-19 infection. With the ongoing outbreak, it will not be surprising to find erythroderma, EN, erythema multiforme and other rashes associated with COVID-19.<sup>10</sup> The literature is likely to reveal more dermatological manifestations in the future.

### Learning points

- ▶ Erythema nodosum (EN) is a common cutaneous manifestation with until now no known pathogenesis.
- ▶ EN has many different aetiologies and for every diagnosed case, several infectious and non-infectious causes have to be investigated so as not to miss a treatable origin.
- ▶ EN associated with fever, cough and shortness of breath may be attributed to a COVID-19-associated skin rash.

**Contributors** PS was the lead author for this case report, leading the initial patient care and management and contributed to the writing of the manuscript. HPPHT contributed to the writing of the manuscript and conceived the original idea. BM supported the writing, as well as aiding with translation.

**Funding** The authors have not declared a specific grant for this research from any funding agency in the public, commercial or not-for-profit sectors.

**Competing interests** None declared.

**Patient consent for publication** Obtained.

**Provenance and peer review** Not commissioned; externally peer reviewed.

This article is made freely available for use in accordance with BMJ's website terms and conditions for the duration of the covid-19 pandemic or until otherwise determined by BMJ. You may use, download and print the article for any lawful, non-commercial purpose (including text and data mining) provided that all copyright notices and trade marks are retained.

### ORCID iD

Philipp Suter <http://orcid.org/0000-0003-1426-4544>

### REFERENCES

- 1 Requena L, Yus ES. Erythema nodosum. *Dermatol Clin* 2008;26:425–38.
- 2 Schwartz RA, Nervi SJ. Erythema nodosum: a sign of systemic disease. *Am Fam Physician* 2007;75:695–700.
- 3 Blake T, Manahan M, Rodins K. Erythema nodosum - a review of an uncommon panniculitis. *Dermatol Online J* 2014;20:22376.
- 4 Cribier B, Caille A, Heid E, et al. Erythema nodosum and associated diseases. A study of 129 cases. *Int J Dermatol* 1998;37:667–72.
- 5 Recalcati S. Cutaneous manifestations in COVID-19: a first perspective. *J Eur Acad Dermatol Venereol* 2020;34:e212-e213.
- 6 Manalo IF, Smith MK, Cheeley J, et al. A dermatologic manifestation of COVID-19: transient Livedo reticularis. *J Am Acad Dermatol* 2020:30558–2.
- 7 Estébanez A, Pérez-Santiago L, Silva E, et al. Cutaneous manifestations in COVID-19: a new contribution. *J Eur Acad Dermatol Venereol* 2020;34:e250–1.
- 8 Joob B, Wiwanitkit V. COVID-19 can present with a rash and be mistaken for dengue. *J Am Acad Dermatol* 2020;82:e177.
- 9 Ubogy Z, Persellin RH. Suppression of erythema nodosum by indomethacin. *Acta Derm Venereol* 1982;62:265.
- 10 Türsen Ümit, Türsen B, Lotti T. Coronavirus-days in dermatology. *Dermatol Ther* 2020:e13438.

Copyright 2020 BMJ Publishing Group. All rights reserved. For permission to reuse any of this content visit <https://www.bmj.com/company/products-services/rights-and-licensing/permissions/>  
BMJ Case Report Fellows may re-use this article for personal use and teaching without any further permission.

Become a Fellow of BMJ Case Reports today and you can:

- ▶ Submit as many cases as you like
- ▶ Enjoy fast sympathetic peer review and rapid publication of accepted articles
- ▶ Access all the published articles
- ▶ Re-use any of the published material for personal use and teaching without further permission

### Customer Service

If you have any further queries about your subscription, please contact our customer services team on +44 (0) 207111 1105 or via email at [support@bmj.com](mailto:support@bmj.com).

Visit [casereports.bmj.com](http://casereports.bmj.com) for more articles like this and to become a Fellow