



Electroconvulsive therapy and seizure: a double-edged sword?

Hye-Rim Shin¹, Minah Kim², Kyung-Il Park^{3,4}

¹Department of Neurology, Dankook University Hospital, Cheonan, Korea

²Department of Neuropsychiatry, Seoul National University Hospital, Seoul, Korea

³Department of Neurology, Seoul National University Hospital, Seoul National University College of Medicine, Seoul, Korea

⁴Department of Neurology, Seoul National University Hospital Healthcare System Gangnam Center, Seoul, Korea

Electroconvulsive therapy (ECT) is a widely used therapeutic option of drug-refractory psychiatric disorders. ECT treats psychiatric symptoms by inducing brief controlled seizures through electrical stimulation, but ECT does not generally cause prolonged seizures or epilepsy. However, several studies have reported cases of prolonged seizures after ECT. This review aimed to determine the mechanism of epileptogenesis with neurobiological changes after ECT. Contrary to epileptogenesis by ECT, several cases have reported that ECT was successfully applied for treatment of refractory status epilepticus. In addition, ECT might be applied to hyperkinetic movement and psychiatric symptoms of encephalitis. We also investigated the anticonvulsant mechanism of ECT and how it controls encephalitis symptoms.

Keywords: Epilepsy, Seizures, Electroconvulsive therapy, Status epilepticus, Encephalitis

Introduction

Electroconvulsive therapy (ECT) is widely used for treatment of drug-refractory psychiatric disorders, including major depressive disorder (MDD), bipolar disorder, and schizophrenia [1-3]. ECT was first conducted in 1938 by Italian neuropsychiatrists Ugo Cerletti and Lucio Bini to treat a schizophrenia patient [4]. ECT induces generalized tonic-clonic seizure by electrical stimulation [1].

Although seizures are induced whenever ECT is performed, most previous studies suggested that ECT does not cause prolonged epileptic seizures [5-7]. However, there are several reports of status epilepticus (SE) and/or persistent epilepsy after ECT [8-11].

In contrast, several previous studies showed that ECT can be applied safely even in patients with epilepsy [12-14]. Psychiatric disorders including MDD are a common comorbidity in epilepsy patients, and drug-refractory psychiatric symptoms

may also occur in patients with epilepsy [15-17]. ECT can also be employed as a treatment for refractory epilepsy and SE [18-20]. In addition, it has also been reported that ECT is safe and effective in treating abnormal movement disorders in encephalitis patients [21,22].

In this review, we aimed to determine whether ECT can lead to epilepsy development and investigate which factors are involved in inducing epileptogenesis. Also conversely, we review the literature that demonstrated ECT can be used for the treatment of refractory seizure and encephalitis.

Methods and neurobiological changes after electroconvulsive therapy

ECT is conducted through the following process (Figure 1) [1,23]: (1) Attach electrodes for electroencephalography (EEG) and electrocardiography. (2) Install a stimulator unilaterally or on both temporal sides. (3) Administer muscarinic anti-

Received: March 13, 2023 Revised: June 15, 2023 Accepted: June 16, 2023

Correspondence: Kyung-Il Park

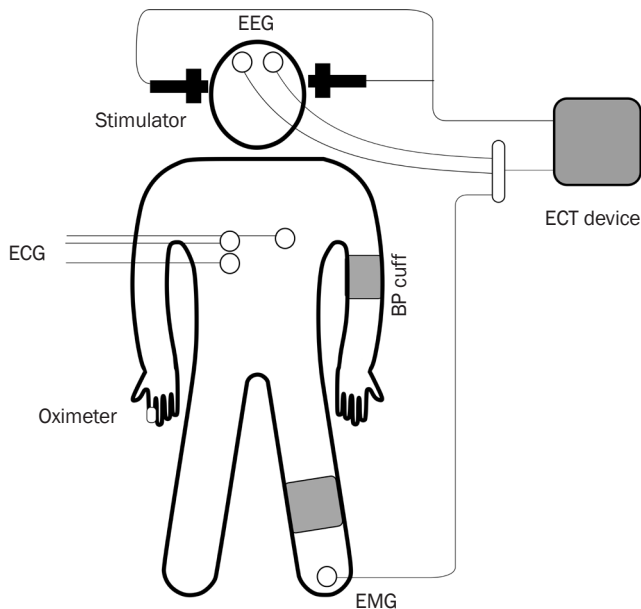
Department of Neurology, Seoul National University Healthcare System Gangnam Center, 152 Teheran-ro, Gangnam-gu, Seoul 06236, Korea

E-mail: ideopki@gmail.com

ORCID: <https://orcid.org/0000-0001-8064-6749>

Copyright © 2023 by The Korean Encephalitis and Neuroinflammation Society

This is an open access article distributed under the terms of the Creative Commons Attribution Non-Commercial License (<http://creativecommons.org/licenses/by-nc/4.0/>) which permits unrestricted non-commercial use, distribution, and reproduction in any medium, provided the original work is properly cited.

Figure 1 General protocol for electroconvulsive therapy (ECT)

(1) Attach electrodes for electroencephalography (EEG) and electrocardiography (ECG). (2) Install a stimulator unilaterally or on both temporal sides. (3) Administer muscarinic anticholinergics (glycopyrrolate). (4) Perform general anesthesia and administer oxygen. (5) Induce sedation with propofol, etomidate, or remifentanyl. (6) Increase the pressure of the blood pressure (BP) cuff placed on the ankle or wrist above the systolic BP. (7) Administer a muscle relaxant (succinylcholine). (8) Apply electrical stimulation. (9) Observe the seizure. (10) Wake patient and monitor recovery.
EMG, electromyography.

cholinergics (glycopyrrolate) to suppress secretions, and prevent cardiac arrhythmia. (4) Provide general anesthesia and oxygen supply. (5) Induce sedation with propofol, etomidate, or remifentanyl. (6) After the patient is sedated, increase the pressure of the blood pressure cuff placed on the ankle or wrist above the systolic blood pressure to observe seizures in foot or hand. (7) Administer a muscle relaxant (succinylcholine). (8) Apply electrical stimulation after muscle relaxation. (9) Observe the seizure through EEG and clinical convulsions. (10) Wake patient and observe recovery.

The therapeutic effect of ECT has been attributed to multifaceted mechanisms including neurotransmitters, neuroendocrine changes, structural changes, and neuroinflammation, but remains largely unclear [24-28]. Seizure induction is critical for the therapeutic effect of ECT [24,25]. During electric stimulation in ECT, cortical neurons are directly stimulated and excitatory neuronal activities are spread throughout the

brain. A brief seizure, mostly 30 seconds to 1 minute, is induced and it affects various neurotransmitters, intracellular signaling, and neuronal circuits [24,26,27]. Several studies suggested more extensive seizure spread after ECT is related to successful treatment of psychiatric symptoms [24,27].

One of the possible therapeutic mechanisms of ECT is related to neurotransmitters. Since repetitive excitatory glutamergic signals spread during convulsions, repetitive ECT induces inhibitory signals mainly by gamma-aminobutyric acid (GABA) [24,25,29]. These inhibitory signals seem to be related to therapeutic effects on regional hyperactivity related to manic symptoms, acute psychosis, or catatonia [24-26,29]. This therapeutic mechanism including GABA may be explained that ECT has a low risk of causing long-term seizures and can even be used to treat refractory seizures [5-7].

Another theory on ECT's therapeutic mechanism is the neuroendocrine hypothesis [24,25,28]. ECT induces release of adrenocorticotrophic hormones including cortisol and prolactin, with a return to baseline level in several hours [25,28]. As dopaminergic neurotransmitters strongly inhibit prolactin, several studies have suggested these hormonal changes may act as a dopaminergic antagonist and exert antipsychotic properties [28]. Patients with MDD have hypothalamic-pituitary-adrenal dysfunction and a high cortisol level that is related to psychiatric symptoms [24,25,28]. Following ECT sessions, cortisol decreases to a normal level in MDD patients [25,28]. The mechanism of hormonal changes is unclear, but it may be related to repeated stress [25,28].

Also, there is increasing evidence of neuroinflammation playing an important role in the therapeutic effects of ECT [25,30]. Several studies showed that neuroinflammation may contribute to development of psychiatric disorders, including psychiatric symptoms in epilepsy patients [31,32]. ECT transiently increases inflammatory mediators, including interleukin-6, tumor necrosis factor- α , and cortisol [25,30]. However, repetitive ECT leads to downregulation of inflammatory reactions in the long term, which can contribute to the therapeutic effect of ECT [25,30]. Also, inflammatory mediators induce depression by degrading tryptophan, which is a precursor of serotonin, via the tryptophan-kynurenine pathway [31,33]. ECT influences the tryptophan-kynurenine pathway toward neuroprotective shifting and antidepressant properties [33].

Repeated ECT also causes structural alterations in the brain [24-26]. ECT brings about neuroplastic changes, including synapses, neurons, and glial cells [24,25]. In patients with

MDD, previous studies with serial brain magnetic resonance images demonstrated an increment in hippocampal volume following ECT [34,35]. Also, several studies suggested amygdala can be enlarged after ECT, which is related to clinical therapeutic effects [35,36]. However, the relationship between structural changes and therapeutic effects is conflicting, and the mechanism of treatment is unknown [25].

Development of epilepsy after electroconvulsive therapy

ECT treats psychiatric symptoms by inducing seizures but does not induce prolonged seizures or epilepsy [5-7,37]. A large 5-year-long study of psychiatric patients who received ECT showed no cases of spontaneous seizure after ECT [5]. ECT can be safely used in patients with epilepsy, and seizure frequency did not change after ECT [12,14]. Several studies of patients with epilepsy have also been conducted on whether antiseizure medication (ASM) should be temporarily discontinued or reduced when performing ECT [12,38]. In most cases, brief seizures, which are required for the therapeutic effect of ECT, were induced successfully without adjustment of ASM, and psychiatric symptoms were treated effectively [38].

Spontaneous seizure after ECT is defined as a tardive seizure and may present with bilateral tonic-clonic seizures, focal motor seizures, or nonconvulsive symptoms [37,39]. The prevalence of tardive seizure is approximately 1% to 2% of patients who received ECT [7,39], and multiple seizures during a single session of ECT, a history of seizure, medications that can lower seizure threshold, and electrolyte imbalance are potential risk factors [37,40].

Several studies have reported cases of newly developed epilepsy after ECT [8,9], and a study by Bryson et al. [9] showed cases of temporal lobe epilepsy after ECT. In this study, the mechanism of epileptogenesis after ECT was explained as 'kindling' [9,41]. In animal studies, prolonged seizure after repetitive electrical stimulation was reported as the electrical kindling model [41]. During ECT, limbic structures including amygdala are stimulated, and these structures are susceptible to epileptogenesis [9,35]. This repetitive stimulation is thought to bring out epileptiform discharges and focal seizures [9].

Rarely, SE after ECT cases have been reported, including non-convulsive SE (NCSE) [10,11]. In the case of NCSE, detection is challenging because epileptic-like EEG rhythm can occur between ECT sessions, and clinical symptoms including confusion and catatonia can mimic seizures [10,42]. Most of the SE cases did not progress to chronic epilepsy after treatment

of SE [10,11]. Although the exact mechanism of SE after ECT remains unclear, it may be different from the kindling mechanism mentioned above.

Electroconvulsive therapy in refractory seizures

Several reports presented cases of application of ECT to the treatment of refractory SE and drug-refractory seizure [18-20]. In a systematic review paper presented by Zeiler et al. [20] in 2016, cases of ECT applied to refractory SE were reviewed. Nineteen patients in 14 original articles were reviewed, and 11 (57.9%) showed seizure reduction or cessation [20]. However, the number of ECT sessions and electric stimulation parameters were too heterogeneous to suggest a standardized treatment protocol for SE, and the duration of the seizure control effect achieved from ECT was also variable [20].

A review published by Ray [43] in 2017 suggested an ECT protocol for SE with a higher charge (up to 1,000-1,500 mC) and frequency than psychiatric disorders, bitemporal stimulation, and at least 6 sessions. During ECT, anesthetic agents, which can inhibit ECT-induced seizures, should be stopped, and ASMs should be carefully adjusted to control seizures without inhibiting ECT-induced seizures [43]. However, the neurological outcomes of SE patients who underwent ECT were poor [20], and further systematic studies should be conducted to establish the therapeutic effect of ECT in SE.

One of the mechanisms of the anticonvulsant effect achieved by ECT is explained by GABA [24,25]. ECT induces brief, controlled seizures with transiently increased glutamate levels [25,44]. After brief hyper-excitatory signals during an ECT-induced seizure, presynaptic release and transmission of GABA are increased and cortical inhibition occurs [25,44]. In addition to GABA, inhibitory neuropeptides are enhanced including neuropeptide-Y, somatostatin, and endothelin, leading to burst suppression [20,36]. In animal studies, long-term neuroplasticity and anti-kindling action after ECT also have anticonvulsant effects [24,25,43].

Electroconvulsive therapy in encephalitis

ECT can be applied to the treatment of encephalitis, and in particular, to treat catatonia symptoms according to encephalitis [21,22]. Among them, the application of ECT in anti-N-methyl-D-aspartate receptor encephalitis (NMDAR encephalitis) is most commonly reported [22,45]. NMDAR encephalitis is the most common type of autoimmune encephalitis caused by immunoglobulin G antibodies against the NR1 subunit of NMDAR and is also present in dyskinesia patients [45,46]. Severe dyskinesia can cause self-injuries and falls, and

sometimes rhabdomyolysis contributes to morbidity and mortality [46,47].

Tanguturi et al. [45] reviewed cases of catatonia in NMDAR encephalitis patients treated with ECT. Eight case studies were reviewed, all of which included immunotherapy and/or tumor removal, and treatment trial with benzodiazepines, ASMs, and antipsychotics was not effective [45]. ECT was initiated after one or more adjuvant treatments for catatonia failed, and showed therapeutic efficacy [45]. There were no adverse events related to ECT despite multiple risk factors, indicating ECT could be safely applied, even in severe cases of encephalitis.

The mechanism of ECT's therapeutic effect in NMDAR encephalitis is not well understood, but several theories have been suggested. One of the theories is that NMDAR is upregulated by tissue plasminogen activator (tPA) after ECT [45,48]. ECT promotes synthesis and release of tPA, and tPA mediates the excitatory signal by calcium influx via NMDAR. As the level of tPA is increased, NMDAR is upregulated and activated following ECT [48,49]. In NMDAR encephalitis, the activity of NMDAR is inhibited due to receptor-specific antibodies, causing psychiatric symptoms and hyperkinetic movements [46,50]. Beyond control of hyperkinetic motor symptoms, NMDAR upregulation consequent to ECT might also have a therapeutic effect on the disease course.

Several animal studies showed that ECT promoted the synthesis of neurotrophic factors, including brain-derived neurotrophic factor [24,25,51]. By increasing neurotrophic factors, ECT influences microglial cells and the immune system, leading to neurogenesis and gliogenesis [20,51]. However, as most of the hypotheses are based on animal studies, further clinical studies on NMDAR encephalitis are needed to understand the exact mechanisms.

Conclusions

ECT is widely used to treat psychiatric symptoms by applying brief electrical stimulation to the brain and inducing controlled seizures. The therapeutic mechanisms of ECT are complicated, including changing neuronal plasticity and limbic structure by increasing inhibitory GABA signals via repetitive seizures, neuroendocrine changes, and neuroinflammation. Although there have been several reports of epilepsy development after ECT, the general prevalence is relatively low. The anticonvulsant effect related to inhibitory neuropeptides including GABA and long-term neuroplasticity is thought to

be greater than seizure provocation effect based on the reviews to date. Furthermore, ECT can be applied to control symptoms of encephalitis, especially dyskinesia symptoms of NMDAR encephalitis. Additional clinical research on the relationship of ECT with seizures and epilepsy is needed.

Conflicts of Interest

Kyung-Il Park has been the editor-in-chief of encephalitis, and he was not involved in the review process of this article. No other potential conflict of interest relevant to this article was reported.

Author Contributions

Conceptualization: Shin HR; Data curation & visualization: Shin HR, Kim M; Supervision: Kim M, Park KI; Writing-original draft: Shin HR, Park KI; Writing-review & editing: all authors

References

1. American Psychiatric Association. The practice of electroconvulsive therapy: recommendations for treatment, training, and privileging (a task force report of the American Psychiatric Association). American Psychiatric Pub; 2008.
2. Bahji A, Hawken ER, Sepehry AA, Cabrera CA, Vazquez G. ECT beyond unipolar major depression: systematic review and meta-analysis of electroconvulsive therapy in bipolar depression. *Acta Psychiatr Scand* 2019;139:214–226.
3. Petrides G, Malur C, Braga RJ, et al. Electroconvulsive therapy augmentation in clozapine-resistant schizophrenia: a prospective, randomized study. *Am J Psychiatry* 2015;172:52–58.
4. Patriarca C, Clerici CA, Zannella S, Fraticelli C, Ugo Cerletti, Pathologica and electroconvulsive therapy. *Pathologica* 2021;113:481–487.
5. Ray AK. Does electroconvulsive therapy cause epilepsy? *J ECT* 2013;29:201–205.
6. Devinsky O, Duchowny MS. Seizures after convulsive therapy: a retrospective case survey. *Neurology* 1983;33:921–925.
7. Blackwood DH, Cull RE, Freeman CP, Evans JI, Mawdsley C. A study of the incidence of epilepsy following ECT. *J Neurol Neurosurg Psychiatry* 1980;43:1098–1102.
8. Rasmussen KG, Lunde ME. Patients who develop epilepsy during extended treatment with electroconvulsive therapy. *Seizure* 2007;16:266–270.
9. Bryson A, Gardner H, Wilson I, Rolfe T, Archer J. Temporal lobe epilepsy following maintenance electroconvulsive therapy: electrical

- kindling in the human brain? *Epilepsia* 2016;57:e216–e220.
10. Aftab A, VanDercar A, Alkhachroum A, LaGrotta C, Gao K. Nonconvulsive status epilepticus after electroconvulsive therapy: a review of literature. *Psychosomatics* 2018;59:36–46.
 11. Chathanchirayil SJ, Bhat R. Post-electroconvulsive therapy status epilepticus and tardive seizure in a patient with rapid cycling bipolar disorder, epilepsy, and intellectual disability. *J ECT* 2012;28:183–184.
 12. Lunde ME, Lee EK, Rasmussen KG. Electroconvulsive therapy in patients with epilepsy. *Epilepsy Behav* 2006;9:355–359.
 13. Micallef-Trigona B, Spiteri J. Maintenance electroconvulsive therapy in a patient with treatment-resistant paranoid schizophrenia and comorbid epilepsy. *Case Rep Psychiatry* 2012;2012:374752.
 14. Marchetti RL, Fiore LA, Peluso MA, Rigonatti SP. Safety and efficacy of ECT in mental disorders associated with epilepsy: report of three cases. *J ECT* 2003;19:173–176.
 15. Rai D, Kerr MP, McManus S, Jordanova V, Lewis G, Brugha TS. Epilepsy and psychiatric comorbidity: a nationally representative population-based study. *Epilepsia* 2012;53:1095–1103.
 16. Scott AJ, Sharpe L, Hunt C, Gandy M. Anxiety and depressive disorders in people with epilepsy: a meta-analysis. *Epilepsia* 2017;58:973–982.
 17. Clancy MJ, Clarke MC, Connor DJ, Cannon M, Cotter DR. The prevalence of psychosis in epilepsy: a systematic review and meta-analysis. *BMC Psychiatry* 2014;14:75.
 18. Tan HJ, Tee TY, Husin M, Khoo CS, Woon LS. A case series of super-refractory status epilepticus successfully treated with electroconvulsive therapy. *Epileptic Disord* 2020;22:828–833.
 19. Shah N, Pande N, Bhat T, Murke M, Andrade C. Maintenance ECT as a therapeutic approach to medication-refractory epilepsy in an adult with mental retardation: case report and review of literature. *J ECT* 2012;28:136–140.
 20. Zeiler FA, Matuszczak M, Teitelbaum J, Gillman LM, Kazina CJ. Electroconvulsive therapy for refractory status epilepticus: a systematic review. *Seizure* 2016;35:23–32.
 21. Shukla L, Narayanaswamy JC, Gopinath S, Math SB. Electroconvulsive therapy for the treatment of organic catatonia due to viral encephalitis. *J ECT* 2012;28:e27–e28.
 22. Sunwoo JS, Jung DC, Choi JY, et al. Successful treatment of refractory dyskinesia secondary to anti-N-methyl-D-aspartate receptor encephalitis with electroconvulsive therapy. *J ECT* 2016;32:e13–e14.
 23. Flink M. *Electroconvulsive therapy: a guide for professionals and their patients*. Oxford University Press; 2009.
 24. Michael N. Hypothesized mechanisms and sites of action of electroconvulsive therapy. In: Swartz C, editor. *Electroconvulsive and neuromodulation therapies*. Cambridge University Press; 2009. p. 75–93.
 25. Singh A, Kar SK. How electroconvulsive therapy works?: understanding the neurobiological mechanisms. *Clin Psychopharmacol Neurosci* 2017;15:210–221.
 26. Swartz CM. A mechanism of seizure induction by electricity and its clinical implications. *J ECT* 2014;30:94–97.
 27. Bolwig TG. How does electroconvulsive therapy work?: theories on its mechanism. *Can J Psychiatry* 2011;56:13–18.
 28. Haskett RF. Electroconvulsive therapy's mechanism of action: neuroendocrine hypotheses. *J ECT* 2014;30:107–110.
 29. Perera TD, Luber B, Nobler MS, Prudic J, Anderson C, Sackeim HA. Seizure expression during electroconvulsive therapy: relationships with clinical outcome and cognitive side effects. *Neuropsychopharmacology* 2004;29:813–825.
 30. Yrondi A, Sporer M, Péran P, Schmitt L, Arbus C, Sauvaget A. Electroconvulsive therapy, depression, the immune system and inflammation: a systematic review. *Brain Stimul* 2018;11:29–51.
 31. Miller AH, Maletic V, Raison CL. Inflammation and its discontents: the role of cytokines in the pathophysiology of major depression. *Biol Psychiatry* 2009;65:732–741.
 32. Shin HR, Chu K, Lee WJ, et al. Neuropsychiatric symptoms and seizure related with serum cytokine in epilepsy patients. *Sci Rep* 2022;12:7138.
 33. Guloksuz S, Arts B, Walter S, et al. The impact of electroconvulsive therapy on the tryptophan-kynurenine metabolic pathway. *Brain Behav Immun* 2015;48:48–52.
 34. Moon SY, Kim M, Lho SK, Oh S, Kim SH, Kwon JS. Systematic review of the neural effect of electroconvulsive therapy in patients with schizophrenia: hippocampus and insula as the key regions of modulation. *Psychiatry Investig* 2021;18:486–499.
 35. Joshi SH, Espinoza RT, Pirmia T, et al. Structural plasticity of the hippocampus and amygdala induced by electroconvulsive therapy in major depression. *Biol Psychiatry* 2016;79:282–292.
 36. Ten Doesschate F, van Eijndhoven P, Tendolkar I, van Wingen GA, van Waarde JA. Pre-treatment amygdala volume predicts electroconvulsive therapy response. *Front Psychiatry* 2014;5:169.
 37. Warren N, Eyre-Watt B, Pearson E, et al. Tardive seizures after electroconvulsive therapy. *J ECT* 2022;38:95–102.
 38. Cinderella MA, Nichols NA, Munjal S, Yan J, Kimball JN, Gligorovic P. Antiepileptics in electroconvulsive therapy: a mechanism-based review of recent literature. *J ECT* 2022;38:133–137.
 39. Whittaker R, Scott A, Gardner M. The prevalence of prolonged cerebral seizures at the first treatment in a course of electroconvulsive therapy. *J ECT* 2007;23:11–13.
 40. Cristancho MA, Alici Y, Augoustides JG, O'Reardon JP. Uncommon but serious complications associated with electroconvulsive therapy: recognition and management for the clinician. *Curr Psychiatry Rep* 2008;10:474–480.
 41. Bertram E. The relevance of kindling for human epilepsy. *Epilepsia* 2007;48 Suppl 2:65–74.

42. Fink M. Interseizure EEG slowing after ECT is not NCSE. *Pharmacopsychiatry* 2006;39:119.
43. Ray AK. Treatment of refractory status epilepticus with electroconvulsive therapy: need for future clinical studies. *Int J Epilepsy* 2017; 4:98–103.
44. Sanacora G, Mason GE, Rothman DL, et al. Increased cortical GABA concentrations in depressed patients receiving ECT. *Am J Psychiatry* 2003;160:577–579.
45. Tanguturi YC, Cundiff AW, Fuchs C. Anti-N-methyl d-Aspartate receptor encephalitis and electroconvulsive therapy: literature review and future directions. *Child Adolesc Psychiatr Clin N Am* 2019;28:79–89.
46. Varley JA, Webb AJ, Balint B, et al. The Movement disorder associated with NMDAR antibody-encephalitis is complex and characteristic: an expert video-rating study. *J Neurol Neurosurg Psychiatry* 2019;90:724–726.
47. Lim JA, Lee ST, Kim TJ, et al. Frequent rhabdomyolysis in anti-NMDA receptor encephalitis. *J Neuroimmunol* 2016;298:178–180.
48. Hoirisch-Clapauch S, Mezzasalma MA, Nardi AE. Pivotal role of tissue plasminogen activator in the mechanism of action of electroconvulsive therapy. *J Psychopharmacol* 2014;28:99–105.
49. Hardingham GE, Bading H. The Yin and Yang of NMDA receptor signalling. *Trends Neurosci* 2003;26:81–89.
50. Masdeu JC, Dalmau J, Berman KE. NMDA receptor internalization by autoantibodies: a reversible mechanism underlying psychosis? *Trends Neurosci* 2016;39:300–310.
51. Segawa M, Morinobu S, Matsumoto T, Fuchikami M, Yamawaki S. Electroconvulsive seizure, but not imipramine, rapidly up-regulates pro-BDNF and t-PA, leading to mature BDNF production, in the rat hippocampus. *Int J Neuropsychopharmacol* 2013;16:339–350.