



# Challenges of non-mass enhancement breast lesions mimicking malignancy encountered on breast magnetic resonance imaging

Eun Jung Choi<sup>^</sup>

Department of Radiology and Research Institute of Clinical Medicine of Jeonbuk National University, Biomedical Research Institute of Jeonbuk National University Hospital, Jeonbuk National University Medical School, Jeonju, Republic of Korea

*Correspondence to:* Eun Jung Choi, MD, PhD. Department of Radiology and Research Institute of Clinical Medicine of Jeonbuk National University, Biomedical Research Institute of Jeonbuk National University Hospital, Jeonbuk National University Medical School, 20 Geonji-ro, Deokjin-gu, Jeonju, Jeollabuk-Do 54907, Republic of Korea. Email: cejcej80@hanmail.net.

*Comment on:* Liu G, Li Y, Chen SL, *et al.* Non-mass enhancement breast lesions: MRI findings and associations with malignancy. *Ann Transl Med* 2022;10:357.

Submitted Jul 25, 2023. Accepted for publication Sep 14, 2023. Published online Oct 07, 2023.

doi: 10.21037/atm-23-1787

View this article at: <https://dx.doi.org/10.21037/atm-23-1787>

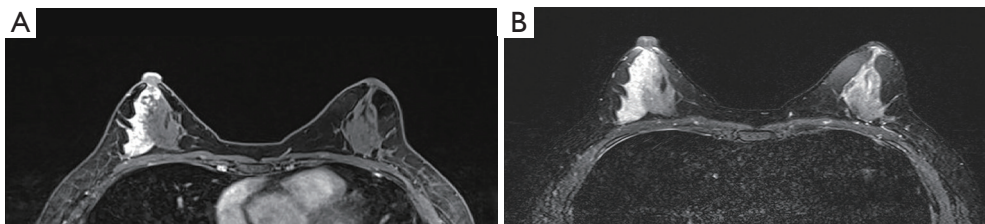
We recently read a published paper titled “Non-mass enhancement breast lesions: MRI findings and associations with malignancy” by Liu *et al.* (1), which revealed that the findings of breast magnetic resonance imaging (MRI), such as segmental distribution, clustered-ring enhancement, wash-out dynamic curve, and a lower apparent diffusion coefficient (ADC) value are associated with malignancy. We appreciate the insight provided by the findings of Liu *et al.* Based on their results, we discuss additional information regarding MRI features associated with the differentiation between benign and malignant non-mass enhancement (NME) breast lesions, further supplemented by an interesting case report. Therefore, we investigated the challenges of NME breast lesions mimicking malignancy encountered on dynamic contrast-enhanced magnetic resonance imaging (DCE-MRI).

A 43-year-old female patient with a history of breast cancer of the left breast, which had been diagnosed three years previously, presented to our hospital for follow-up. Mammography and ultrasonography (US) revealed normal findings. The post-contrast T1-weighted image (T1WI) obtained from DCE-MRI, revealed a new segmental NME with homogenous internal enhancement in the right outer quadrant of the breast (*Figure 1A*), compared to an image obtained from the previous follow-up. The dynamic curve exhibited a rapid washout pattern. On T2-weighted

imaging (T2WI) with fat saturation, the lesion showed a higher signal intensity than that of the normal parenchyma (*Figure 1B*). On targeted US examination, the lesion was not clearly distinguished from normal fibroglandular tissues, and color Doppler imaging did not reveal an increased vascularity. US-guided biopsy was performed, and the pathological analysis revealed a fibrocystic change (FCC). Owing to these investigations, imaging pathology was considered discordant; subsequently, an excisional biopsy was recommended for adequate targeting and sampling. The patient underwent a wide local excision, and the size of the specimens measured 4.5 cm × 3.0 cm. A pathological analysis of these specimens revealed FCC. All procedures performed in case were in accordance with the ethical standards of the institutional and/or national research committee(s) and with the Helsinki Declaration (as revised in 2013). Written informed consent was obtained from the patient for the publication of this article and accompanying images. A copy of the written consent is available for review by the editorial office of this journal.

This study revealed that certain MRI features; particularly, segmental distribution and washout dynamic curves were associated with malignancy. Furthermore, this case showed similar MRI features to those suggesting malignant NME in this study, highlighting that these features are not exclusive to malignant breast lesions.

<sup>^</sup> ORCID: 0000-0002-2339-4327.



**Figure 1** A challenging case of NME breast lesions mimicking malignancy on breast MRI. (A) The post-contrast T1WI obtained from DCE-MRI, revealed a new segmental NME with homogenous internal enhancement in the right outer quadrant of the breast. (B) On T2WI with fat saturation, the lesion showed a higher signal intensity than that of the normal parenchyma. NME, non-mass enhancement; MRI, magnetic resonance imaging; T1WI, T1-weighted image; DCE-MRI, dynamic contrast-enhanced magnetic resonance imaging; T2WI, T2-weighted imaging.

Breast MRI provides a high sensitivity and a modest positive predictive value (PPV) for the diagnosis of breast malignancy. Several benign breast lesions mimic malignancies (2). Suspicious features on imaging may be a part of the imaging spectrum of several benign breast lesions, making them indistinguishable from breast malignancies (2). Therefore, extensive knowledge of the MRI features of benign breast lesions that mimic malignancy is beneficial in decreasing the false-positive rate on breast MRI. Additionally, it is important to be knowledgeable of the MRI features of FCC, because it is the most common benign breast condition among benign breast lesions. Broad histological variations characterize FCC of the breast, encompassing stromal fibrosis, cysts, adenosis, apocrine metaplasia, and epithelial proliferation to various degrees (3). This histological diversity may account for the wide spectrum of MRI features of FCC (4). Previous studies have reported a wide range (34–95.1%) of PPV for segmental distribution, and identified that the dynamic curves were less effective, a contrast to those of this study (5–7).

Regarding the internal enhancement pattern, this case of FCC revealed homogeneous internal enhancement. In this present study, we found that clustered rings can increase the suspicion of malignancy; however, homogeneous internal enhancement is not associated with malignancy, thus representing a distinctive feature. Diffusion-weighted imaging (DWI) was not performed in this case. Nevertheless, along with the finding of an increased signal intensity on T2WI; combining DWI, T2WI, and ADC values can assist radiologists in differentiating between benign and malignant NME lesions. This is consistent with previous studies (8,9).

In conclusion, we acknowledge the various MRI features associated with malignant NME lesions, as reported

by Liu *et al.* However, when evaluating potential NME breast lesions, this interesting case report highlighted the importance of considering a combination of MRI features associated with malignant NME breast lesions, rather than relying on a single MRI feature. Further MRI studies could provide valuable assistance to radiologists for differentiating between invasive carcinoma and ductal carcinoma *in situ*.

### Acknowledgments

**Funding:** This work was supported by a National Research Foundation of Korea (NRF) grant funded by the Korean Government (No. 2021R1G1A1006474).

### Footnote

**Provenance and Peer Review:** This article was a standard submission to the journal. The article did not undergo external peer review.

**Conflicts of Interest:** The author has completed the ICMJE uniform disclosure form (available at <https://atm.amegroups.com/article/view/10.21037/atm-23-1787/coif>). The author reports a National Research Foundation of Korea (NRF) grant funded by the Korean Government (No. 2021R1G1A1006474). The author has no other conflicts of interest to declare.

**Ethical Statement:** The author is accountable for all aspects of the work in ensuring that questions related to the accuracy or integrity of any part of the work are appropriately investigated and resolved. All procedures performed in this case were in accordance with the ethical standards of the institutional and/or national research

committee(s) and with the Helsinki Declaration (as revised in 2013). Written informed consent was obtained from the patient for the publication of this article and accompanying images. A copy of the written consent is available for review by the editorial office of this journal.

*Open Access Statement:* This is an Open Access article distributed in accordance with the Creative Commons Attribution-NonCommercial-NoDerivs 4.0 International License (CC BY-NC-ND 4.0), which permits the non-commercial replication and distribution of the article with the strict proviso that no changes or edits are made and the original work is properly cited (including links to both the formal publication through the relevant DOI and the license). See: <https://creativecommons.org/licenses/by-nc-nd/4.0/>.

## References

1. Liu G, Li Y, Chen SL, et al. Non-mass enhancement breast lesions: MRI findings and associations with malignancy. *Ann Transl Med* 2022;10:357.
2. Gutierrez RL, DeMartini WB, Eby PR, et al. BI-RADS lesion characteristics predict likelihood of malignancy in breast MRI for masses but not for nonmasslike enhancement. *AJR Am J Roentgenol* 2009;193:994-1000.
3. Malherbe K, Khan M, Fatima S. Fibrocystic Breast Disease. In: StatPearls. Treasure Island (FL): StatPearls Publishing; August 8, 2023.
4. Choe AI, Kasales C, Mack J, et al. Fibrocystic Changes of the Breast: Radiologic–Pathologic Correlation of MRI. *Journal of Breast Imaging* 2022;4:48-55.
5. Morakkabati-Spitz N, Leutner C, Schild H, et al. Diagnostic usefulness of segmental and linear enhancement in dynamic breast MRI. *Eur Radiol* 2005;15:2010-7.
6. Cho YH, Cho KR, Park EK, et al. Significance of Additional Non-Mass Enhancement in Patients with Breast Cancer on Preoperative 3T Dynamic Contrast Enhanced MRI of the Breast. *Iran J Radiol* 2016;13:e30909.
7. Goto M, Ito H, Akazawa K, et al. Diagnosis of breast tumors by contrast-enhanced MR imaging: comparison between the diagnostic performance of dynamic enhancement patterns and morphologic features. *J Magn Reson Imaging* 2007;25:104-12.
8. Kim KW, Kuzmiak CM, Kim YJ, et al. Diagnostic Usefulness of Combination of Diffusion-weighted Imaging and T2WI, Including Apparent Diffusion Coefficient in Breast Lesions: Assessment of Histologic Grade. *Acad Radiol* 2018;25:643-52.
9. Wu LM, Chen J, Hu J, et al. Diffusion-weighted magnetic resonance imaging combined with T2-weighted images in the detection of small breast cancer: a single-center multi-observer study. *Acta Radiol* 2014;55:24-31.

**Cite this article as:** Choi EJ. Challenges of non-mass enhancement breast lesions mimicking malignancy encountered on breast magnetic resonance imaging. *Ann Transl Med* 2023;11(11):400. doi: 10.21037/atm-23-1787