

whereas on the right side all components beyond W2 were delayed and reduced in amplitude, suggesting an impairment of afferent conduction at some site between the trigeminal root and the trigeminal nuclei.<sup>4</sup> Increasing carbamazepine dosage to 400 mg three times daily caused the pain to disappear. Two years later his symptoms worsened. Neurological examination and TEPs were unchanged. Magnetic resonance angiography showed multiple ischaemic lesions in the cerebral hemispheres with widespread cortical atrophy. An ischaemic lesion was found in the right lateral part of the pons, in the trigeminal root entry zone (figure). Multiple sclerosis and Lyme disease were ruled out by the clinical history and by appropriate investigations. Radiofrequency selective thermal rhizotomy was followed by a slight, further decrease of tactile and pain sensation in the right trigeminal territory (second branch) and by disappearance of the pain.

In this patient the typical pain of trigeminal neuralgia was associated with an ischaemic lesion strictly localised to the ipsilateral trigeminal root entry zone. This association may have been, in theory, coincidental, but it seems unlikely. In fact, alterations in TEP showed a functional damage of the afferent pathway at the same site where altered morphology was detected by MRI. Furthermore, the ischaemic lesion was exactly at the trigeminal root entry zone, an area where most lesions causing secondary trigeminal neuralgia are located.<sup>1</sup> Neuralgic pain waxed and waned for many years: this is expected, as trigeminal neuralgia is known to show remissions and recurrences secondary to permanent trigeminal lesions.<sup>1</sup> We recommend that brainstem ischaemia is included in the differential diagnosis of trigeminal neuralgia, especially when the neurological examination discloses alterations in trigeminal nerve function. Measurement of TEP is useful in the search for such alterations. In our patient the pain was successfully treated with carbamazepine for several years, and was eventually relieved by radiofrequency selective thermal rhizotomy, a procedure that may not necessarily be confined to the treatment of "essential" trigeminal neuralgia.

MAURIZIO BALESTRINO  
MASSIMO LEANDRI

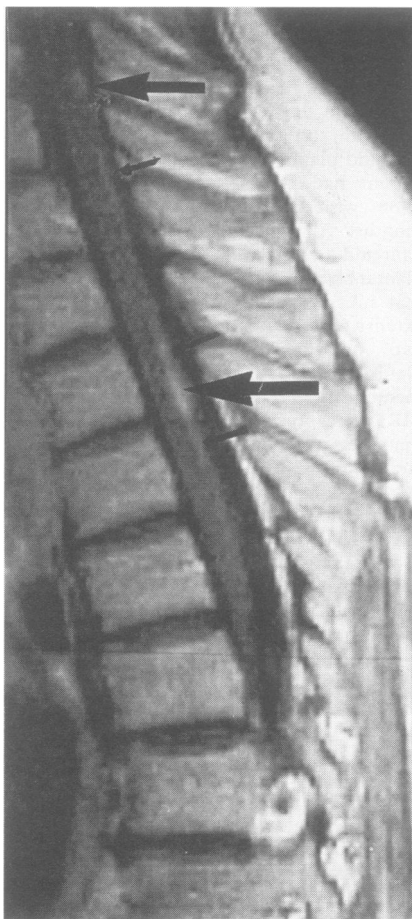
Department of Neurological Sciences, University of  
Genova, Italy

Correspondence to: Dr M Balestrino,  
Dipartimento di Scienze Neurologiche, Via De  
Toni 5, 16132 Genova, Italy.

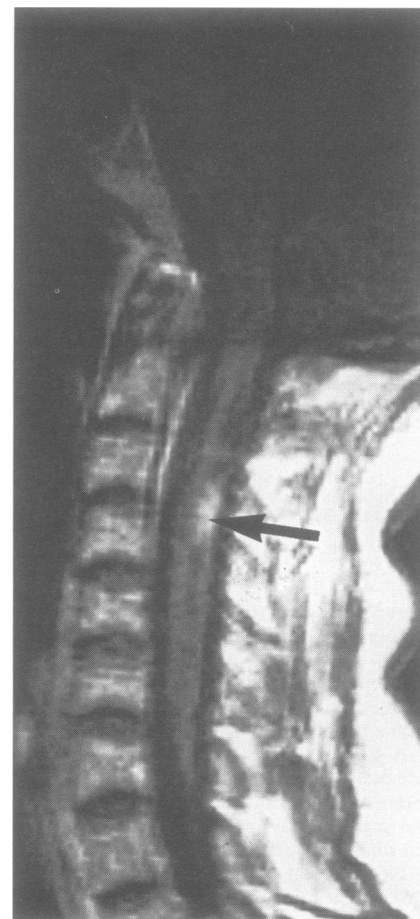- Selby G. Diseases of the fifth cranial nerve. In: Dick PJ, Thomas PK, Lambert EH, Bunge E, eds. *Peripheral neuropathy*. 2nd ed. Vol II. Philadelphia: WB Saunders, 1984:1224-65.
- Fruhstorfer H, Lindblom U, Schmidt WG: Method for quantitative estimation of thermal thresholds in patients. *J Neurol Neurosurg Psychiatry* 1976;39:1071-5.
- Leandri M, Parodi CI, Favale E. Normative data on scalp responses evoked by infraorbital nerve stimulation. *Electroencephalogr Clin Neurophysiol* 1988;71:415-21.
- Leandri M, Campbell JA. Origin of early waves evoked by infraorbital nerve stimulation in man. *Electroencephalogr Clin Neurophysiol* 1986;65:13-9.

#### MRI demonstration of reversible impairment of the blood-CNS barrier function in subacute combined degeneration of the spinal cord

We report clinical, laboratory, and imaging findings in a case of subacute combined degeneration of the spinal cord. The 50 year



(A) Sagittal T1 weighted image after administration of 15 ml contrast agent. Apart from larger lesions at the thoracic and lower cervical level (large arrows), many smaller pearl-like contrast enhancing spots can be seen (small arrows).



(B) Sagittal T1 weighted image after administration of 15 ml of contrast agent. A nodular contrast enhancing lesion is present in the posterior cervical cord (arrow).

old woman presented with tickling sensations running down her back when bending the head. Five months before she had first noticed numbness of her feet which slowly ascended to the level of her nipples. During the past six months she had lost 7 kg in weight.

Forward flexion of her neck induced Lhermitte's phenomenon. The tendon reflexes of her legs and plantar responses were absent. Complete loss of light touches, vibration, and position sense was found below D5. Pain and thermal perception were not diminished. Her gait was unsteady due to a sensory ataxia.

Her mean red cell volume was 110 fl and serum vitamin B12 concentration was 44 pmol/l. Haemoglobin, packed cell volume, and folate were normal. The two stage "Schilling test" showed intestinal malabsorption of vitamin B12, not due to lack of intrinsic factor. Gastric endoscopy was non-specific. analysis of CSF was normal.

Somatosensory evoked potentials from tibial and sural nerves showed abnormalities in latency indicative of a lesion in the posterior columns of the spinal cord; the somatosensory evoked potentials from both median nerves were normal. Nerve conduction studies of the sural nerves disclosed a reduced nerve conduction velocity indicative of a demyelinating neuropathy.

Two weeks after treatment with 1000 µg vitamin B12 daily, there was an almost complete restitution of sensory functions.

T2 weighted MRI images of the thoracic spinal cord showed an ill defined hyperintense lesion in the posterior parts of the spinal cord. T1 weighted images after administration of gadolinium DTPA showed multiple slightly expansive, contrast enhancing lesions in the posterior column of the cervical and thoracic spinal cord (fig A, B). After 18 days of treatment the lesions had disappeared.

In summary, our patient had the classic clinical signs of spinal cord degeneration including Lhermitte's phenomenon, sensory impairment, dysaesthesia, and sensory ataxia of the lower limbs. In all cases reported so far, MRI studies were performed in spinal cord degeneration to exclude a spinal cord compression.<sup>1-5</sup> The lesions detected as hyperintensities in T2 weighted images were always located in the posterior columns of the spinal cord. The thoracic region was affected in all patients. Signal abnormalities in the cervical region were seen in two cases.<sup>4,5</sup>

We found a very pronounced, multifocal contrast enhancement of the cervical and thoracic sections of the spinal cord indicating blood-CNS barrier disruption. The lesions were multifocal and located close to the spinal cord surface. A slight degree of expansion was noted. Thus a granulomatous inflammation, multiple sclerosis lesions, or tumour metastases had to be considered. The clue to spinal cord degeneration in this case was the location of the lesions exclu-

sively in the dorsal columns of the spinal cord.

W KÜKER  
V HESSELMANN  
A THRON  
Department of Neuroradiology  
A DE SIMONE  
Department of Neurology,  
University Hospital of the Technical University,  
D. 52057,  
Germany

Correspondence to: Dr W Küker

- Berger JR, Quenzer R. Reversible myelopathy with pernicious anemia: clinical/MRI correlation. *Neurology* 1991;41:947-8.
- Murata S, Naritomi H, Sawada T. MRI in subacute combined degeneration. *Neuroradiology* 1994;36:408-9.
- Wolansky LJ, Goldstein G, Gozo A, Lee HJ, Sills I, Chatkupt S. Subacute combined degeneration of the spinal cord: MRI detection of preferential involvement of the posterior columns in a child. *Pediatr Radiol* 1995; 25:140-1.
- Timms SR, Cure J, Kurent JE. Subacute combined degeneration of the spinal cord: MR findings. *AJNR Am J Neuroradiol* 1993;14: 1124-7.
- Tracey JP, Schiffman FJ. Magnetic resonance imaging in cobalamin deficiency. *Lancet* 1992;339:1172-3.

**Electrophysiological monitoring in neurological respiratory insufficiency**

In patients with neurological respiratory insufficiency it may be difficult to determine whether there is a neuromuscular problem, impaired central drive, or both. Phrenic nerve conduction studies and needle EMG of the diaphragm are well established methods in the diagnosis and prognosis of neuromuscular causes of diaphragmatic weakness.<sup>1</sup> Transcortical and cervical magnetic stimulation with recording from the diaphragm and somatosensory evoked potentials of the phrenic nerve can assess the motor and sensory pathways of the central respiratory drive.<sup>2,3</sup> We report the value of peripheral and central respiratory electrophysiological studies in a patient with acute high cervical spinal cord infarction who developed secondary critical illness polyneuropathy.

This 76 year old previously healthy man had an acute onset of sharp, knife-like chest pain, and could not move his limbs a short time later. The pain lasted about an hour. On admission to hospital, three hours after onset of symptoms, his mental status and cranial nerves were intact. He was flaccidly quadriplegic with no voluntary movement except of elevation of both shoulders. Initially, he had diaphragmatic breathing clinically. Plantar responses were extensor. Pinprick, temperature, and light touch sensation were lost below C4 bilaterally. Vibratory sensation was lost in the limbs, but position sense was incompletely affected: passive movements were perceived in the toes on the left side, and at the knee on the right side. Within a few hours breathing became rapid and shallow. He was intubated and placed on a ventilator. The patient transiently worsened for about a week: he lost his ability to shrug his shoulders and the sensory level rose to below C3 bilaterally.

Spinal cord MRI showed abnormally increased signal anteriorly within the spinal cord signal from C4-T1 vertebral levels, and oedema ascending to C2. Examination of CSF was unremarkable. Serial electrophysiological studies for monitoring diaphragmatic muscle function were done (table). Phrenic nerve conduction studies were performed with electrical stimulations at the

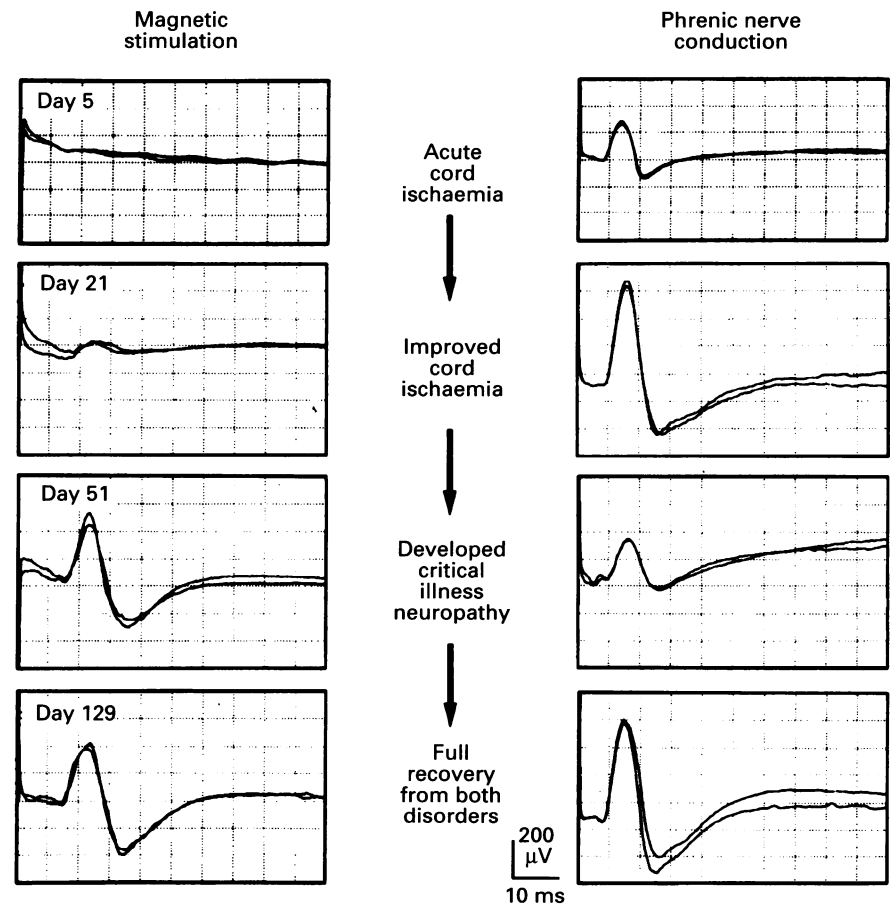
Results of right phrenic nerve conduction (n = 25) and transcortical magnetic stimulation with recording of the right diaphragm (n = 35) in healthy subjects, and in the patient with cervical infarction and critical illness neuropathy

Measurement	Healthy subjects Mean (SD)	Patient
Phrenic nerve conduction:		
Latency (ms)	6.5 (0.8)	8.3 (5) 8.0 (21) 9.6 (51) 8.0 (129)
Amplitude (µV)	669 (159)	330 (5) 760 (21) 290 (51) 720 (129)
Cortical magnetic stimulation:		
Latency (ms)	13.5 (1.4)	No response (5) 18.2 (21) 16.1 (51) 15.8 (129)
Amplitude (µV)	263 (144)	No response (5) 110 (21) 460 (51) 400 (129)

For the patient, the day of examination after onset of illness is given in parentheses.

distal neck just posterior to the sternomastoid muscle.<sup>4</sup> Transcortical magnetic stimulations were performed at the beginning of inspiration with a 90 mm circular coil positioned over Cz (determined by the 10-20 EEG system).<sup>2</sup> No diaphragmatic compound muscle action potentials (CMAPs) were recorded after transcortical magnetic stimulation, and phrenic nerve conduction studies showed borderline onset latency and diaphragmatic CMAP amplitude at day 5 (figure). Transcortical magnetic stimulation

on day 21 showed a delayed but recordable diaphragmatic CMAP, and normal phrenic nerve conduction. At this time he developed a septic syndrome due to pneumonia. The patient could not be weaned from the ventilator within the following weeks, and the necessity of a phrenic nerve pacemaker was raised. Subsequently, the sensory level descended distal to C6, and some movement was noted in the proximal left upper limb muscles (MRC 3). Electrophysiological follow up study on day 51 showed complete



Values of latencies and amplitudes of the right diaphragmatic compound muscle action potential. Cortical magnetic stimulations were performed with a 90 mm circular coil positioned flat over the vertex (Cz). The phrenic nerve was stimulated electrically at the posterior border of the sternomastoid muscle in the supraclavicular fossa. The diaphragmatic compound muscle action potential was recorded bilaterally with surface electrodes from the xiphoid (active electrode) and the costal margin (reference electrode) for both magnetic and phrenic nerve stimulation. The table shows that there was no significant right-left differences.