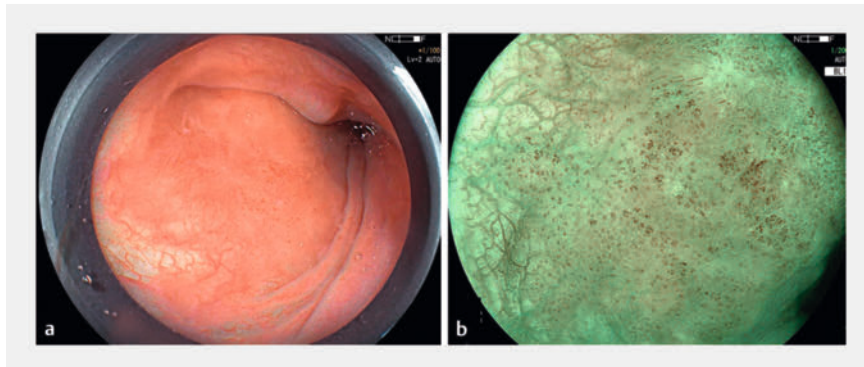



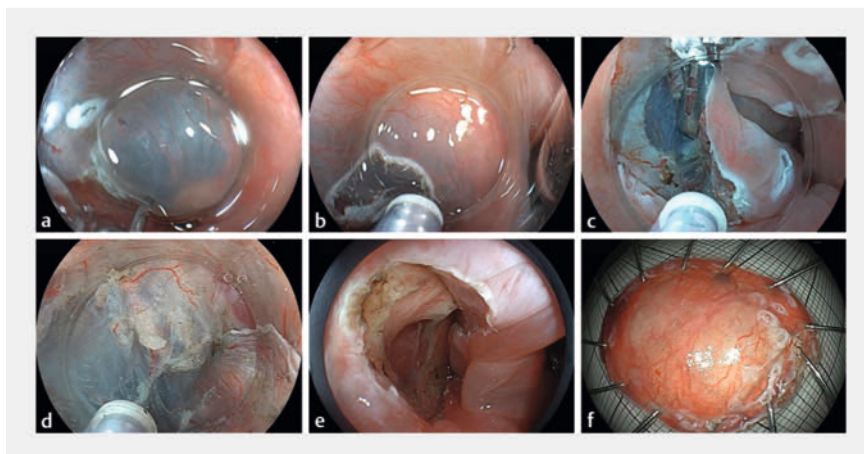
Underwater endoscopic submucosal dissection with dental floss traction for the treatment of early pharyngeal cancer



► **Fig. 1** Appearance of the lesion preoperatively showing: **a** on white-light imaging, a reddish coloration of the mucosa; **b** on blue-laser imaging (BLI), a tea-colored appearance, classifying it as type B1, consistent with an early pharyngeal tumor.



► **Video 1** Underwater endoscopic submucosal dissection with dental floss traction is performed for a pharyngeal superficial squamous cell carcinoma.



► **Fig. 2** Images during underwater endoscopic submucosal dissection to treat an early pharyngeal cancer showing: **a** submucosal injection being performed; **b** a mucosal incision being made; **c** the application of dental floss traction; **d** underwater submucosal dissection being performed; **e** the postoperative appearance; **f** the macroscopic appearance of the resected tumor.

A 72-year-old man underwent a gastroscopy that revealed a 13×11-mm lesion within the left pyriform sinus (0-IIb). The lesion displayed a reddish hue under white light, with well-defined borders (► **Fig. 1 a**). Its tea-colored appearance under blue-laser imaging (BLI) classified it as type B1, indicative of an early pharyngeal tumor (► **Fig. 1 b**).

Following this discovery, the patient underwent endoscopic submucosal dissec-

tion (ESD) under general anesthesia with endotracheal intubation (► **Video 1**). Magnifying endoscopy enabled precise delineation of the lesion's extent. Although routine procedures involving submucosal injection (► **Fig. 2 a**) and circumferential incision (► **Fig. 2 b**) were performed, challenges subsequently emerged in identifying the appropriate dissection layer owing to the confined pharyngeal space and limited submuco-

sal thickness. To address this issue, a dental floss traction technique was employed (► **Fig. 2 c**), coupled with the water immersion method (► **Fig. 2 d**), enhancing the clarity in the submucosal dissection plane. The procedure was completed successfully, without encountering intraoperative bleeding or perforation (► **Fig. 2 e, f**). Subsequent pathological examination confirmed the presence of a squamous cell carcinoma, with negative resection margins. A follow-up endoscopy, 1 month post-ESD, confirmed complete healing of the surgical wound.

ESD has emerged as an effective and safe therapeutic modality for early pharyngeal cancer, preserving patients' quality of life and physiological function [1, 2]. However, the technical complexity of the procedure is compounded by factors such as the narrow pharyngeal cavity, tracheal intubation, and the potential influence of the hyoid bone, further augmenting the challenges associated with pharyngeal endoscopy [3].

The application of dental floss traction during ESD, along with the water immersion technique, which capitalizes on the inherent buoyancy of water, provides enhanced traction and improved visual acuity [4]. This heightened visual en-

hancement not only diminishes the need for injections, but also exploits water's refractive amplification, thereby facilitating enhanced differentiation between the various tissue layers. Recent years have seen widespread adoption of this approach for challenging cases involving esophageal, duodenal, and colonic pathologies. To our knowledge, this case represents the first report of an early pharyngeal carcinoma treated with underwater ESD, substantiating the efficacy and safety of implementing underwater ESD in the pharyngeal region.

Endoscopy_UCTN_Code_TTT_1AO_2AC

Conflict of Interest

The authors declare that they have no conflict of interest.

The authors

Silin Huang^{1‡}, Li Tan^{2‡}, Suhuan Liao¹, Haining Cai², Guang Yang¹, Jianzhen Ren¹, Kajie He³

- 1 Department of Gastroenterology, South China Hospital, Medical School, Shenzhen University, Shenzhen, China
- 2 Department of Gastroenterology, Beihai People's Hospital, Beihai, China
- 3 Department of Gastroenterology, Beihai People's Hospital, Beihai, China

Corresponding author

Kajie He

Department of Gastroenterology, Beihai People's Hospital, Heping Road 83, Beihai, China
158914748@qq.com

References

- [1] Kamal F, Khan MA, Lee-Smith W et al. Outcomes of endoscopic submucosal dissection for treatment of superficial pharyngeal cancers: systematic review and meta-analysis. *Dig Dis Sci* 2022; 67: 3518–3528. doi:10.1007/s10620-021-07225-6
- [2] Okada K, Tsuchida T, Ishiyama A et al. Endoscopic mucosal resection and endoscopic submucosal dissection for en bloc resection of superficial pharyngeal carcinomas. *Endoscopy* 2012; 44: 556–556. doi:10.1055/s-0032-1309720
- [3] Muramoto T, Ohata K, Sakai E et al. Endoscopic submucosal dissection using an ultrathin endoscope for superficial pharyngeal cancer: a prospective feasibility study (with video). *Endosc Int Open* 2023; 11: E3–E10
- [4] Nagata M. Device-assisted traction methods in colorectal endoscopic submucosal dissection and options for difficult cases. *World J Gastrointest Endosc* 2023; 15: 265–272. doi:10.4253/wjge.v15.i4.265

Bibliography

Endoscopy 2023; 55: E1184–E1185

DOI 10.1055/a-2197-9514

ISSN 0013-726X

© 2023. The Author(s).

This is an open access article published by Thieme under the terms of the Creative Commons Attribution License, permitting unrestricted use, distribution, and reproduction so long as the original work is properly cited.

(<https://creativecommons.org/licenses/by/4.0/>)

Georg Thieme Verlag KG, Rüdigerstraße 14,
70469 Stuttgart, Germany



ENDOSCOPY E-VIDEOS

<https://eref.thieme.de/e-videos>



E-Videos is an open access online section of the journal *Endoscopy*, reporting on interesting cases

and new techniques in gastroenterological endoscopy. All papers include a high-quality video and are published with a Creative Commons CC-BY license. Endoscopy E-Videos qualify for HINARI discounts and waivers and eligibility is automatically checked during the submission process. We grant 100% waivers to articles whose corresponding authors are based in Group A countries and 50% waivers to those who are based in Group B countries as classified by Research4Life (see: <https://www.research4life.org/access/eligibility/>).

This section has its own submission website at

<https://mc.manuscriptcentral.com/e-videos>

[‡] Silin Huang and Li Tan contributed equally to this article.