

# Pearls & Oy-sters: Familial Verbal Auditory Agnosia Due to *C9orf72* Repeat Expansion

Yoon Seob Kim, MD, Young-Eun Kim, MD, PhD, Yun-Hoon Choung, DDS, MD, PhD, Hwajung Kim, MA, Hee Jin Kim, MD, PhD, Na-Yeon Jung, MD, PhD, Sun Min Lee, MD, PhD, Eun-Joo Kim, MD, PhD, and So Young Moon, MD, PhD

## Correspondence

Dr. Moon  
symoon.bv@gmail.com

*Neurology*® 2023;101:e2046-e2050. doi:10.1212/WNL.0000000000207832

## Abstract

Chromosome 9 open reading frame 72 (*C9orf72*) gene pathogenic variants have been typically associated with frontotemporal dementia (FTD) and amyotrophic lateral sclerosis (ALS), but recent studies suggest their involvement in other disorders. This report describes a family with an autosomal dominant pattern of inheritance of progressive verbal auditory agnosia due to GGGGCC repeat expansion in *C9orf72*. A 60-year-old right-handed male truck driver presented with slowly progressive poor speech perception for 8 years, which became most troublesome when receiving verbal orders over the phone. He had difficulty recognizing single-syllable spoken words beyond his hearing loss but had no problem understanding complex written language. He had a heterozygous pathogenic variant carrying 160 hexanucleotide repeats in the *C9orf72* gene. His family history included his deceased mother with similar symptoms that had progressed over 30 years, as well as his older brother and youngest sister who experienced speech perception difficulty beginning in their early fifties. His asymptomatic younger brother had a heterozygous 2 repeat in the *C9orf72* gene, while his symptomatic youngest sister had a heterozygous 159 repeat. The patient and his sister exhibited more pronounced cortical thinning in the frontotemporoparietal areas. The discrepancy observed between the distribution of atrophy and the presentation of symptoms in patients with *C9orf72* pathogenic repeat expansion may be attributable to the slow progression of their clinical course over time. The variable symptom presentation of *C9orf72* pathogenic repeat expansion highlights the importance of considering this pathogenic variant as a potential cause of autosomal dominant degenerative brain diseases beyond FTD and ALS.

## Pearls

- Verbal auditory agnosia, a type of agnosia specific to speech sounds, is typically apperceptive and caused by bilateral lesions in the superior temporal cortex.
- Consider apperceptive verbal auditory agnosia when patients show difficulty recognizing single-syllable words beyond their degree of hearing loss (HL).
- Autosomal dominant progressive verbal auditory agnosia can be caused by a GGGGCC repeat expansion in chromosome 9 open reading frame 72 (*C9orf72*).

## Oy-sters

- It is important to consider factors other than hearing as the cause of poor speech perception which may require a more comprehensive evaluation.
- *C9orf72* pathogenic repeat expansion should be considered in autosomal dominant degenerative brain diseases, other than frontotemporal dementia (FTD) and amyotrophic lateral sclerosis (ALS), because of its variable symptom presentation.

From the Departments of Neurology (Y.S.K., H.K., S.M.L., S.Y.M.) and Otolaryngology (Y.-H.C.), Ajou University School of Medicine, Suwon; Department of Laboratory Medicine (Y.-E.K.), Hanyang University College of Medicine, Seoul; Department of Neurology (H.J.K.), Samsung Medical Center, Sungkyunkwan University School of Medicine, Seoul; Department of Neurology (N.-Y.J.), Pusan National University Yangsan Hospital, Research Institute for Convergence of Biomedical Science and Technology; and Department of Neurology (E.-J.K.), Pusan National University Hospital, Pusan National University School of Medicine and Medical Research Institute, Busan, South Korea.

Go to [Neurology.org/N](https://www.neurology.org/N) for full disclosures. Funding information and disclosures deemed relevant by the authors, if any, are provided at the end of the article.

## Case Report

A 60-year-old right-handed male truck driver presented with 8 years of slowly progressive poor speech perception which became most troublesome when receiving verbal orders over the phone. He also reported slightly reduced ability to cope with problems while driving, and his family noted declining performance in home repairs and a less stubborn demeanor. Despite only receiving a middle school education as a result of his family's economic circumstances, there were no early developmental concerns for behavioral or cognitive problems or learning disabilities in the patient. His medical history was significant for hypertension and diabetes mellitus, but he denied any ear-related illness. The patient's mother exhibited a gradual and progressive decline in speech perception over a span of 30 years. Despite this, she maintained independence in performing daily activities until her demise at the age of 85 years from pneumonia. In addition, his older brother and younger sister also experienced speech perception difficulty since their early fifties. The patient was very cooperative; he showed no problems in following instructions during neurologic examination and was fluent without dysarthria. His naming, reading, and writing were normal. Motor function and sensory function, as well as reflexes, were intact.

The patient's pure tone audiometry (PTA) showed moderate high-frequency sensorineural HL. Right ear bone and air conduction thresholds were 55 dB HL, and left ear air and bone conduction thresholds were 50 dB HL and 45 dB HL, respectively. Tympanometry was normal, but no response was detected in distortion product otoacoustic emissions. The HL was attributed to occupational noise trauma affecting the outer hair cells of the cochlea. Speech audiometry (SA) revealed speech recognition thresholds of 40 dB HL (right ear) and 35 dB HL (left ear) for 2-syllable words. However, single-syllable word recognition was severely impaired, scoring below 50% in both ears. Auditory brainstem response at 60 dB HL was normal. The patient displayed normal perception of man-made, natural, and music sounds.<sup>1,2</sup> Although hearing aids improved thresholds to 30 dB HL, single-syllable word recognition remained poor. The patient discontinued their use, suggesting difficulties in discrimination beyond the degree of HL.

He scored 28 of 30 on the Mini-Mental State Examination. However, a comprehensive neuropsychological test battery revealed significant deficits in verbal comprehension, specifically in discerning subtle syllable differences. Therefore, all instructions were given both verbally and in writing to accommodate his difficulties in verbal comprehension. On the Boston Naming Test, the patient scored 51 of 60 (61.40th percentile), reflecting normal word retrieval ability considering age and education. While the patient's visual memory recall was preserved, he exhibited deficiencies in verbal memory, placing him at the 1.85th percentile for delayed recall in the verbal learning test. In addition, the patient showed impairments in phonemic word fluency (6.05th percentile) and color reading on the Korean-Color Word Stroop test (0.34th percentile),

indicating difficulties inhibiting cognitive interference. His global Clinical Dementia Rating (CDR) was 0.5, signifying mild cognitive impairment, with a CDR-Sum of Boxes score of 1.5. Notably, the NeuroPsychiatric Inventory reported no neuropsychiatric symptoms based on informant interviews conducted over the past month.

Two sequential brain MRI scans were taken, the first one 2 years before the patient's visit (Figure 1, A and B) and the second one during his visit to the clinic (Figure 1, C and D). Visual inspection revealed slight progression of frontotemporal atrophy between the 2 scans. Additional tests, including an amyloid PET scan and CSF analysis, revealed no evidence of amyloid deposition or Alzheimer disease pathology. Given the patient's family history and clinical course, genetic evaluation was recommended. Testing of the *C9orf72* gene and whole-exome sequencing identified a heterozygous pathogenic repeat expansion of 160 (normal, <25) in the *C9orf72* gene, likely explaining the patient's symptoms. No other pathogenic variants related to HL or neurodegenerative disorders were detected.

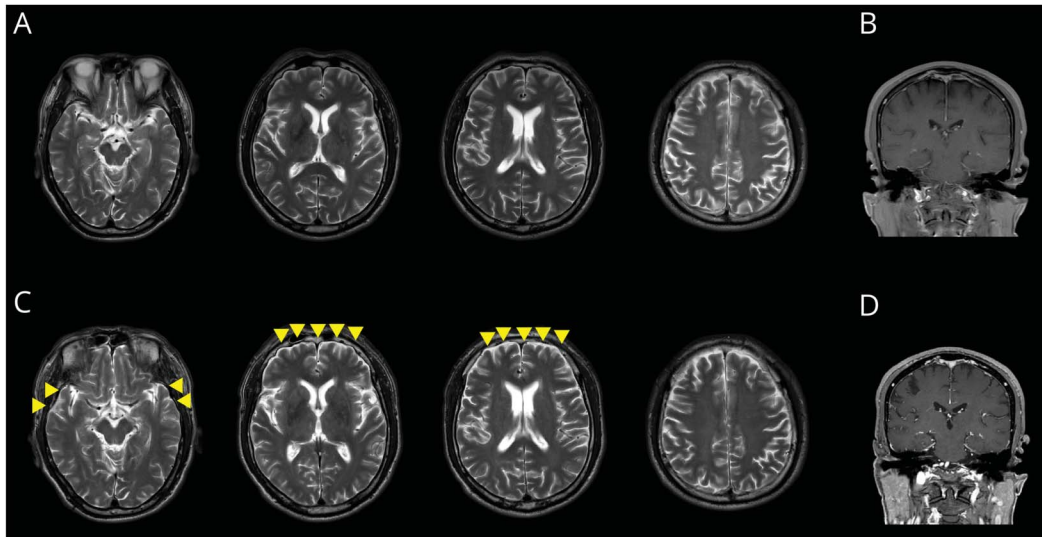
After receiving the patient's *C9orf72* genetic test results, his asymptomatic 58-year-old younger brother and 52-year-old symptomatic younger sister were also evaluated. However, the evaluation of his older brother could not be conducted because of the loss of contact with his siblings. The younger brother had severe conduction HL in his right ear and moderately severe high-frequency sensorineural HL in his left ear, but his word recognition score on his left ear was 80%. He had a heterozygous 2 GGGGCC repeat in the *C9orf72* gene. The younger sister had normal PTA and SA, but she had a heterozygous 159 GGGGCC repeat. Cortical thickness analysis showed the patient had cortical thinning in the frontotemporoparietal areas compared with a standard population (Figure 2A). The patient had greater cortical thinning than the younger sister (Figure 2B), particularly in the superior temporal gyrus, while the younger brother (Figure 2C) showed relatively preserved thickness.

## Discussion

The patient and his family members exhibited progressive verbal auditory agnosia in which they had difficulty recognizing single-syllable words beyond his HL but had no problem understanding complex written language likely due to inherited *C9orf72* gene pathogenic variant. This is the same GGGGCC repeat expansion that is the most common genetic cause of FTD and ALS. The siblings' symptoms and cortical thickness corresponded with the presence of the *C9orf72* pathogenic variant rather than their HL.

While *C9orf72* gene pathogenic variants are commonly associated with FTD and ALS,<sup>3,4</sup> recent research has suggested that they may also be linked to a wider range of disorders, including psychiatric and movement disorders.<sup>5-7</sup> In the case of our patient, the presence of the *C9orf72* pathogenic variant

**Figure 1** Two Sequential Brain MRI Scans With an Interval of 2 Years



Axial T2-weighted (A) and coronal T1-weighted (B) MRI scans from 2 years before presentation showing no indication of space-occupying lesions within the auditory processing system, encompassing the auditory nerve, brainstem, or auditory cortex. Axial T2-weighted (C) and coronal T1-weighted (D) MRI from his visit to the clinic showing marginal advancement of frontal atrophy between the 2 scans (yellow arrowheads).

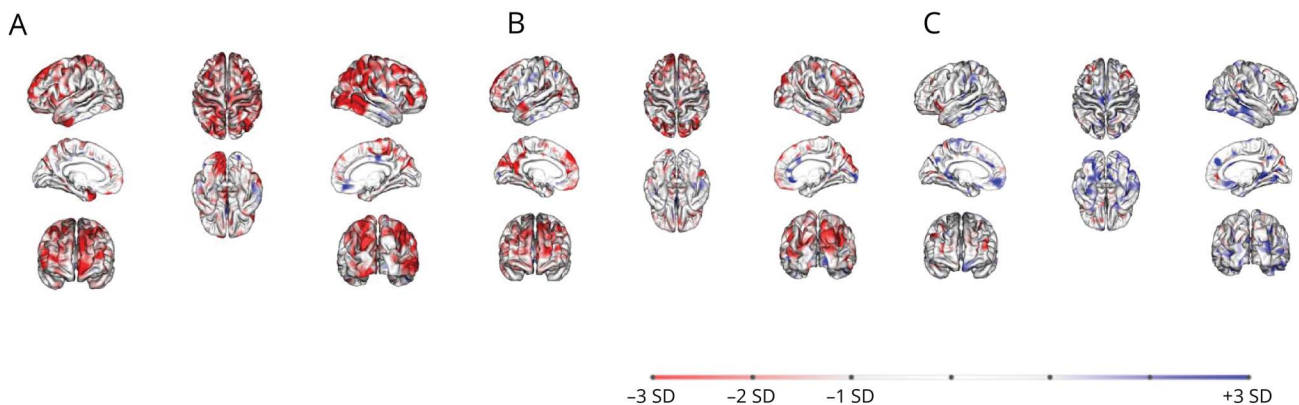
may have contributed to poor performance on frontal/executive tests and reports of changes in his daily executive function and personality by his family,<sup>8</sup> but he did not meet the diagnostic criteria for the behavioral variant of FTD.<sup>9</sup> Despite having had progressive verbal auditory agnosia for 30 years, our patient's mother did not have any symptoms of FTD-ALS spectrum, suggesting that many benign cases of *C9orf72*-related disorders may be missed because of very slow progression.<sup>10-12</sup> Further research is needed to better understand the full range of

symptoms and disorders associated with *C9orf72* gene pathogenic variants.

Auditory agnosia refers to impaired auditory perception and recognition that cannot be attributed to hearing or cognitive deficits.<sup>13,14</sup> It can manifest as a general deficit affecting all aspects of auditory perception or as a relatively specific impairment in recognizing and understanding a particular type of sound, such as speech, music, or environmental sounds. In

**Figure 2** Cortical Thickness Analyses Comparing the Patient and His Siblings With a Standard Population

Age/sex	60/male	52/female	58/male
<i>C9orf72</i> GGGGCC repeats	160	159	2



The patient (A) and his younger sister (B) exhibited greater cortical thinning in the frontotemporoparietal areas compared with the standard population, although less remarkable in his younger sister (B). Specifically, her superior temporal gyrus was affected with an age-adjusted z-score of  $-0.89$  on the right and  $-0.81$  on the left. In comparison, the patient had z-scores of  $-1.45$  on the right and  $-1.32$  on the left. Their younger brother (C) had z-scores of  $-0.02$  on the right and  $-0.12$  on the left, indicating relatively preserved cortical thickness in this region. The standard population consisted of 77 individuals (34 [44%] female patients; mean age  $\pm$  SD  $62.6 \pm 15.5$ , range 21–92).

the case of speech-specific impairment, it is referred to as verbal auditory agnosia. Verbal auditory agnosia can be further categorized as either aperceptive or associative. In aperceptive verbal auditory agnosia, there are difficulties with speech sound perception, while in the associative form, basic perceptual processing is intact, but there is an inability to link perceived patterns to their corresponding auditory objects or meanings. For instance, individuals with aperceptive verbal auditory agnosia may struggle to discriminate between similar speech sounds such as “bat” and “pat” and experience challenges in comprehending verbal instructions. Consequently, our patient experienced difficulty understanding verbal instructions over the phone, especially when encountering unfamiliar combinations of single-syllable words that lacked meaning. However, his speech perception improved during face-to-face conversations, indicating reliance on visual cues such as lip reading, gestures, and contextual information alongside auditory input. Our patient’s motivation to seek medical attention may have been driven by work-related challenges. By contrast, his sister and mother may have developed compensatory strategies and did not feel the necessity for medical intervention.

Aperceptive verbal auditory agnosia is caused by bilateral lesions in the superior temporal cortex.<sup>13,14</sup> A recent case of 2–3 years of progressive verbal auditory agnosia due to AD revealed focal atrophy and tau accumulation in the primary auditory cortex,<sup>15</sup> while our patient showed more widespread atrophy including the superior temporal gyrus. This discrepancy between our patient’s symptom and atrophy pattern may be due to very slow progression of his clinical course over 8 years and his occupation-related complaints. More research is needed to understand the relationship between clinical presentation and pathology in slowly progressive TAR DNA-binding protein 43 pathology.

The case highlights the importance of considering aperceptive verbal auditory agnosia as a possible diagnosis in patients who have difficulty recognizing single-syllable words beyond their degree of HL. It also highlights the need to consider *C9orf72* pathogenic repeat expansion as a possible cause of autosomal dominant degenerative brain diseases, given its variable symptom presentation.

## Study Funding

This research was supported by the “National Institute of Health” Research Project (Project No. 2021-ER1004-01).

## Disclosure

The authors report no relevant disclosures. Go to [Neurology.org/N](https://www.neurology.org/N) for full disclosures.

## Publication History

Received by *Neurology* May 15, 2023. Accepted in final form July 19, 2023. Submitted and externally peer reviewed. The handling editor was Resident & Fellow Section Deputy Editor Ariel Lyons-Warren, MD, PhD.

## Appendix Authors

Name	Location	Contribution
<b>Yoon Seob Kim, MD</b>	Department of Neurology, Ajou University School of Medicine, Suwon, South Korea	Drafting/revision of the manuscript for content, including medical writing for content
<b>Young-Eun Kim, MD, PhD</b>	Department of Laboratory Medicine, Hanyang University College of Medicine, Seoul, South Korea	Major role in the acquisition of data; analysis or interpretation of data
<b>Yun-Hoon Chung, DDS, MD, PhD</b>	Department of Otolaryngology, Ajou University School of Medicine, Suwon, South Korea	Major role in the acquisition of data; analysis or interpretation of data
<b>Hwajung Kim, MA</b>	Department of Neurology, Ajou University School of Medicine, Suwon, South Korea	Major role in the acquisition of data; analysis or interpretation of data
<b>Hee Jin Kim, MD, PhD</b>	Department of Neurology, Samsung Medical Center, Sungkyunkwan University School of Medicine, Seoul, South Korea	Major role in the acquisition of data; analysis or interpretation of data
<b>Na-Yeon Jung, MD, PhD</b>	Department of Neurology, Pusan National University Yangsan Hospital, Research Institute for Convergence of Biomedical Science and Technology, South Korea	Drafting/revision of the manuscript for content, including medical writing for content; major role in the acquisition of data; analysis or interpretation of data
<b>Sun Min Lee, MD, PhD</b>	Department of Neurology, Ajou University School of Medicine, Suwon, South Korea	Drafting/revision of the manuscript for content, including medical writing for content; major role in the acquisition of data; analysis or interpretation of data
<b>Eun-Joo Kim, MD, PhD</b>	Department of Neurology, Pusan National University Hospital, Pusan National University School of Medicine and Medical Research Institute, Busan, South Korea	Drafting/revision of the manuscript for content, including medical writing for content; major role in the acquisition of data; analysis or interpretation of data
<b>So Young Moon, MD, PhD</b>	Department of Neurology, Ajou University School of Medicine, Suwon, South Korea	Drafting/revision of the manuscript for content, including medical writing for content; major role in the acquisition of data; study concept or design; analysis or interpretation of data

## References

- Klarendić M, Gorišek VR, Granda G, Avsenik J, Zgonc V, Kojović M. Auditory agnosia with anosognosia. *Cortex*. 2021;137:255-270. doi:10.1016/j.cortex.2020.12.025
- Uttner I, Mottaghy FM, Schreiber H, et al. Primary progressive aphasia accompanied by environmental sound agnosia: a neuropsychological, MRI, and PET study. *Psychiatry Res*. 2006;146(2):191-197. doi:10.1016/j.psychres.2005.12.003
- DeJesus-Hernandez M, Mackenzie IR, Boeve BF, et al. Expanded GGGGCC hexanucleotide repeat in noncoding region of C9ORF72 causes chromosome 9p-linked FTD and ALS. *Neuron*. 2011;72(2):245-256. doi:10.1016/j.neuron.2011.09.011
- Renton AE, Majounie E, Waite A, et al. A hexanucleotide repeat expansion in C9ORF72 is the cause of chromosome 9p21-linked ALS-FTD. *Neuron*. 2011;72(2):257-268. doi:10.1016/j.neuron.2011.09.010
- Estevez-Fraga C, Magrinelli F, Moss DH, et al. Expanding the spectrum of movement disorders associated with *C9orf72* hexanucleotide expansions. *Neurol Genet*. 2021;7(2):e575. doi:10.1212/NXG.000000000000057

6. Ducharme S, Dols A, Laforce R, et al. Recommendations to distinguish behavioural variant frontotemporal dementia from psychiatric disorders. *Brain*. 2020;143(6):1632-1650. doi:10.1093/brain/awaa018
7. Snowden JS. Changing perspectives on frontotemporal dementia: a review. *J Neuropsychol*. 2022;17(2):211-234. doi:10.1111/jnp.12297
8. Boeve BF, Boylan KB, Graff-Radford NR, et al. Characterization of frontotemporal dementia and/or amyotrophic lateral sclerosis associated with the GGGGCC repeat expansion in C9ORF72. *Brain*. 2012;135(3):765-783. doi:10.1093/brain/aws004
9. Rascovsky K, Hodges JR, Knopman D, et al. Sensitivity of revised diagnostic criteria for the behavioural variant of frontotemporal dementia. *Brain*. 2011;134(9):2456-2477. doi:10.1093/brain/awr179
10. Hokelekli FO, Whitwell JL, Machulda MM, et al. Underlying pathology identified after 20 years of disease course in two cases of slowly progressive frontotemporal dementia syndromes. *Neurocase*. 2021;27(2): 212-222. doi:10.1080/13554794.2021.1918723
11. Llamas-Velasco S, Garcia-Redondo A, Herrero-San Martin A, et al. Slowly progressive behavioral frontotemporal dementia with C9orf72 mutation. Case report and review of the literature. *Neurocase*. 2018;24(1):68-71. doi:10.1080/13554794.2018.1428353
12. Murphy NA, Arthur KC, Tienari PJ, et al. Age-related penetrance of the C9orf72 repeat expansion. *Sci Rep*. 2017;7:2116. doi:10.1038/s41598-017-02364-1
13. Slevc LR, Shell AR. Auditory agnosia. *Handb Clin Neurol*. 2015;129:573-587. doi:10.1016/B978-0-444-62630-1.00032-9
14. Miceli G, Caccia A. Cortical disorders of speech processing: pure word deafness and auditory agnosia. *Handb Clin Neurol*. 2022;187:69-87. doi:10.1016/B978-0-12-823493-8.00005-5
15. Buciu M, Josephs KA, Jones DT, Whitwell JL, Graff-Radford J. Progressive auditory verbal agnosia secondary to alzheimer disease. *Neurology*. 2021;97(19):908-909. doi:10.1212/WNL.0000000000012783