

# Successful Treatment of Granulomatous Rosacea by JAK Inhibitor Abrocitinib: A Case Report

Mingyang Ren <sup>1</sup>, Xianhong Yang<sup>2</sup>, Yan Teng <sup>2</sup>, Wei Lu<sup>2</sup>, Yang Ding <sup>2</sup>, Xiaohua Tao <sup>2</sup>

<sup>1</sup>Department of Graduate School, Bengbu Medical College, Bengbu, People's Republic of China; <sup>2</sup>Center for Plastic & Reconstructive Surgery, Department of Dermatology, Zhejiang Provincial People's Hospital (Affiliated People's Hospital, Hangzhou Medical College), Hangzhou, People's Republic of China

Correspondence: Xiaohua Tao, Email txhtxh@sina.com

**Abstract:** Granulomatous rosacea (GR) is a rare inflammatory skin disease characterized by persistent, hard, yellow, brown, red, or flesh-colored papules, plaques, or nodules on the face. Limited data are available on patients treated for GR, with only case reports and case series published. Herein, we describe the case of a 53-year-old woman who presented to the hospital with persistent red to brown and pink patches on both cheeks accompanied by a burning sensation for one month. Histopathological examination of a cutaneous biopsy revealed granulomatous inflammation in focal areas. Both acid-fast and Periodic acid-Schiff staining were negative. The patient was diagnosed with GR based on her clinical presentation and laboratory test results. She was treated with abrocitinib, a JAK-1 inhibitor, for 20 weeks. This resulted in substantial improvement in her rash and the associated burning sensation. Subsequent follow-up visits indicated no adverse effects or relapses. Additionally, a literature review was conducted to compare with the current case, which concluded that abrocitinib is a viable treatment option for GR, exhibiting a relatively high safety profile with minimal side effects.

**Keywords:** JAK inhibitor, granulomatous rosacea, abrocitinib, efficacy

## Background

Rosacea is a chronic inflammatory skin disease characterized by facial erythema, papules, pustules, capillary dilation, and flushing. Commonly observed in middle-aged and elderly individuals, this centrofacial skin disease has an annual incidence of 165/100 000 individuals.<sup>1</sup> Individuals with a fair skin type are predisposed to rosacea.<sup>1</sup> Granulomatous rosacea (GR), a rare subtype of rosacea, accounts for approximately 1–2% of rosacea cases.<sup>2</sup> It presents as persistent, firm, yellow, brown, red, or flesh-colored papules, plaques, or nodules. Severe cases may lead to scarring and might not be limited to the central facial area; they can also appear on the sides of the face and around the mouth. GR exhibits distinct histopathological features, such as non-caseating epithelioid granulomas with a central cavity surrounded by neutrophils, tissue cells, and lymphocytes.<sup>3</sup>

The diagnosis of this disease requires the exclusion of other granulomatous diseases and rosacea-like rashes, such as sarcoidosis, cutaneous tuberculosis, systemic lupus erythematosus, and disseminated facial milia. Owing to these complexities, GR is often clinically misdiagnosed or underdiagnosed. GR is rare in clinical practice, and there is no consensus on its treatment, rendering its treatment difficult. Current efficacy data are limited to case reports, and existing treatments include topical medications, oral antibiotics, oral vitamin A derivatives, and lasers. However, these can be resistant, costly, and teratogenic. Oral JAK inhibitors are emerging as novel treatment options for rosacea, but their efficacy for GR has not been established.

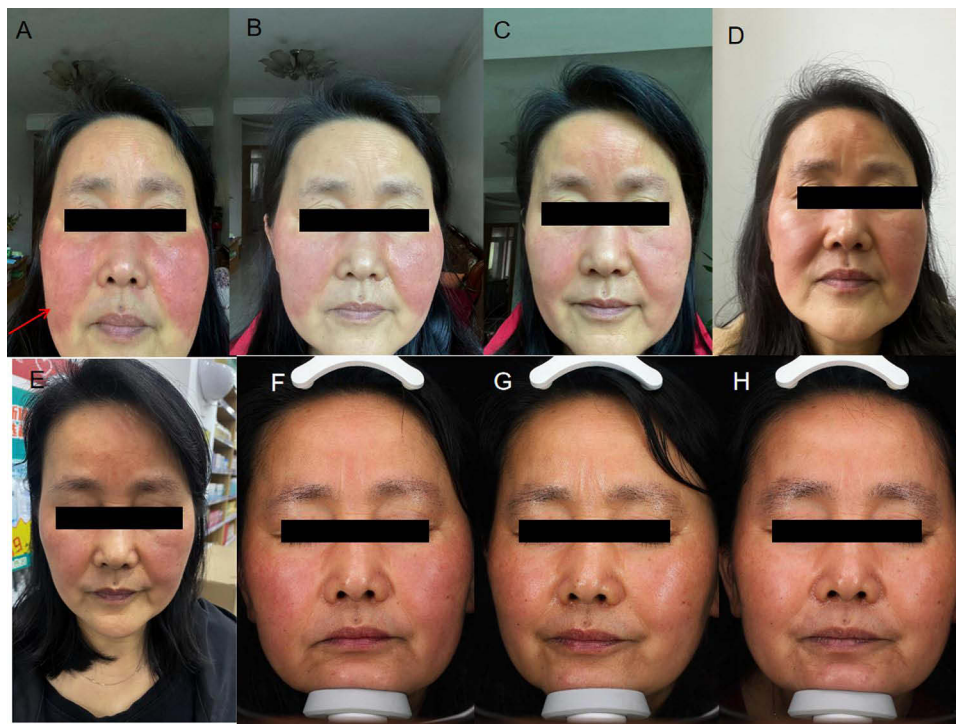Herein, we present a case of a 53-year-old woman with GR who was successfully treated with abrocitinib and also offer a review of the relevant literature.

## Case Report

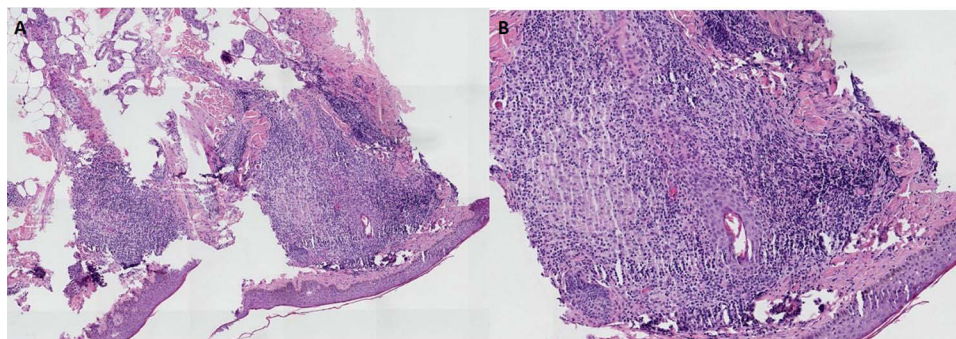
A 53-year-old woman was admitted to Zhejiang Provincial People's Hospital owing to extensive erythema on her cheeks that had persisted for over a month. The condition was accompanied by burning and swollen infiltration and became

apparent after sun exposure. However, the patient did not report any other symptoms such as fatigue, joint pain, or mouth ulcers. She reported that the erythema had significantly disrupted her quality of life, affecting her ability to socialize, work, and sleep. Her past medical, personal, and family histories were unremarkable. Physical examination revealed bilateral, symmetrical erythema on the cheeks with well-defined borders, mild swelling and infiltration, and slight capillary dilatation (Figure 1A). Laboratory investigations showed weak positivity for antinuclear antibodies, with a negative antinuclear antibody titer (<1:32). The patient tested negative for hepatitis B, hepatitis C, HIV, and syphilis. Routine blood tests, tumor markers, tests for liver and kidney function, and the T-spot, were all normal.

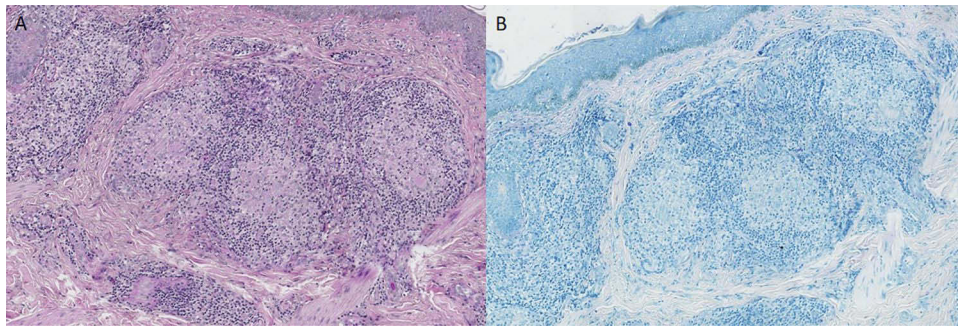
A skin biopsy was performed on the lesions. Histological examination revealed focal epidermal hyperkeratosis, irregular hyperplasia of the stratum spinosum, and diffuse mixed inflammatory cell infiltration throughout the dermis, mainly comprising lymphocytes, histiocytes, and neutrophils. Small neutrophilic abscesses and epithelioid granuloma formation were also observed (Figure 2). Specialized staining tests, including acid-fast and Periodic acid-Schiff staining, showed negative results (Figure 3). Based on these findings, a diagnosis of GR was established, and the patient was



**Figure 1** Clinical photographs show the progression of the patient's condition. (A) Before and; (B) 2; (C) 4; (D) 6; (E) 8; and (F) 12 weeks into abrocitinib 100 mg daily treatment; (G) 16 weeks into abrocitinib 100 mg every other day and; (H) 20 weeks into abrocitinib 100 mg twice weekly treatment. The location of the biopsy (red arrow).



**Figure 2** Histopathological examination of granulomatous rosacea. (A and B) The epidermis appears largely normal, and a large number of granulomas composed of epithelial cells, lymphocytes, and multinucleated giant cells can be observed around the hair follicles in the dermis, with no signs of caseous necrosis.



**Figure 3** Acid-fast staining and PAS staining in granulomatous rosacea. (A) Acid-fast staining did not detect any acid-fast bacilli; (B) PAS staining showed negative results.

prescribed oral abrocitinib at a dose of 100 mg daily. Within a week of starting the medication, the patient's burning sensations markedly subsided. After 20 weeks of treatment and subsequent follow-ups, she experienced significant improvements in erythema, swelling, and capillary dilatation (Figures 1B–H and 4). Subsequently, the abrocitinib dosage was tapered to once weekly. Over the next six weeks of monitoring, no recurrence of symptoms or significant adverse effects were observed.

## Discussion

GR is a rare, chronic inflammatory skin disease first described by Lewandowsky in 1917.<sup>4</sup> It is a specific subtype of rosacea, characterized by persistent red to brown or pink patches; or yellow-brown, red, or flesh-colored papules or nodules on the cheeks; periorbital area; or around the mouth. Histologically, GR is characterized by the presence of non-caseating granulomas, a key feature that distinguishes it from lupus miliaris disseminatus faciei (LMDF).<sup>5</sup> It is important to note that although LMDF shares histological similarities with GR, it should not be classified as a subtype of rosacea.<sup>5</sup>

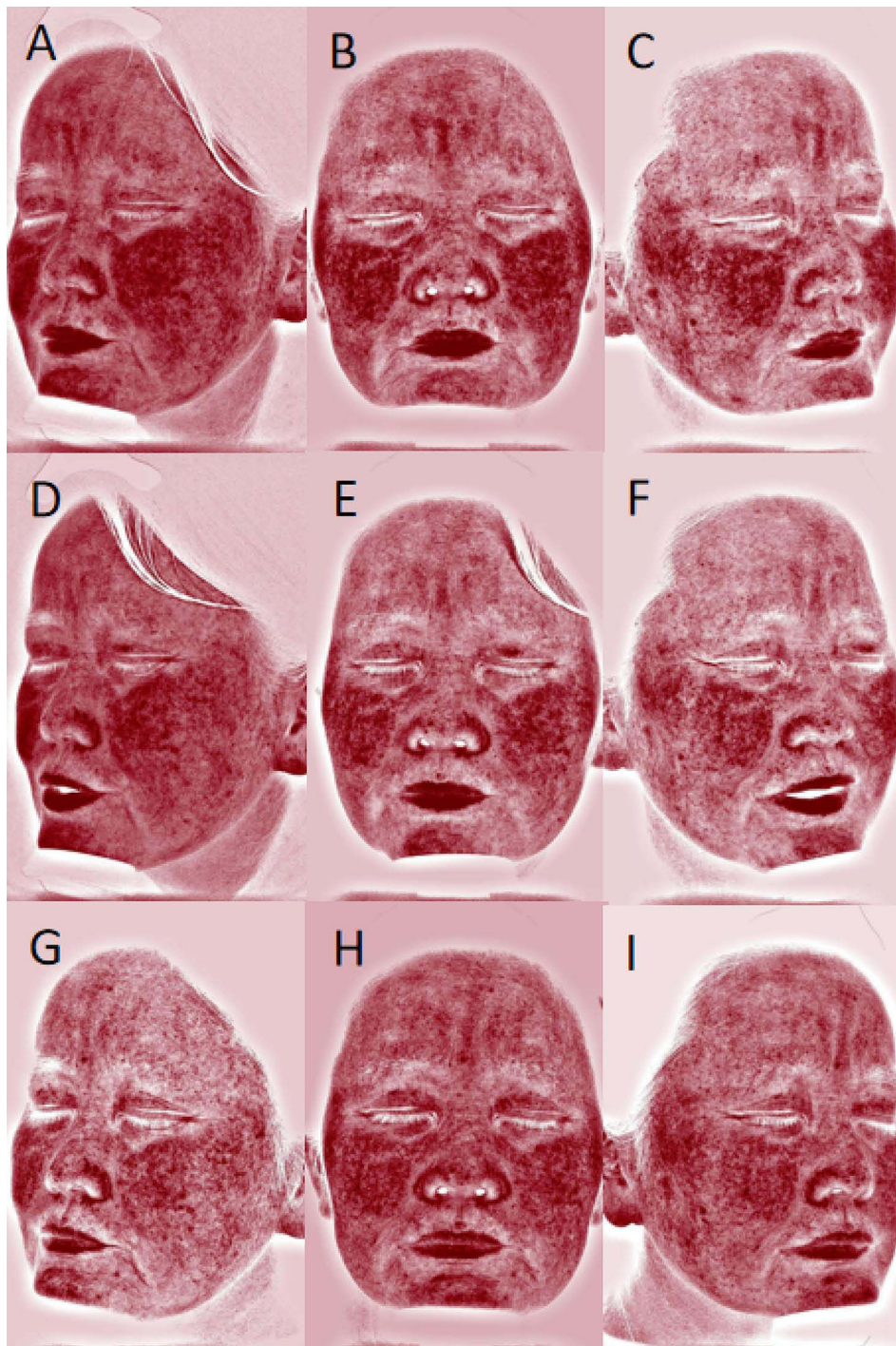There is currently no consensus on the treatment of GR, and the available efficacy data are limited to case reports. The treatment methods for GR are similar to those for papulopustular rosacea. These methods involve the topical application of metronidazole, ivermectin, and azelaic acid to inhibit inflammation and kill *Demodex folliculorum* mites.<sup>6</sup> Systemic treatments such as antibiotics, isotretinoin, and hydroxychloroquine can also be employed to regulate the immune response and improve skin condition.<sup>6</sup> Lane et al conducted a study wherein they used intense pulsed light to selectively heat the skin; eliminate vascular dilation; and reduce the erythema, papules, and pustules caused by GR.<sup>7</sup>

Although treatments for GR are currently available, they pose challenges owing to adverse effects, high recurrence rates, and uncertain treatment outcomes. For example, long-term use of antibiotics can lead to drug resistance and gastrointestinal distress. Oral hydroxychloroquine may lead to fundopathy, whereas JAK inhibitors may have a better safety and tolerability profile compared to conventional treatment options. Recent case reports also support JAK inhibitors as a new therapeutic option. Oral tofacitinib has been proposed as a promising treatment option for patients with rosacea and rosacea-like dermatitis who have significant inflammatory erythema and pustules on the face and for whom conventional treatments have not been effective.<sup>8,9</sup> However, no case reports have specifically explored its effects on GR. Tofacitinib, a JAK-1/3 inhibitor, tends to have more adverse effects compared to abrocitinib, a highly selective JAK-1 inhibitor. The rapid onset of action, safety, and tolerability of abrocitinib may increase patient adherence to the treatment regimen. Therefore, we chose to treat our patients with abrocitinib.

The current case is noteworthy and interesting for several reasons. First, GR manifesting as large infiltrative plaques on the cheeks is relatively rare. Second, this case underscores the efficacy and safety of abrocitinib, a highly selective JAK-1 inhibitor, in treating GR. Moreover, abrocitinib offers a novel alternative for the treatment of GR, especially for patients who fail to respond to traditional treatments or who cannot tolerate them. This has important clinical implications.

The JAK/STAT signaling pathway is activated by cytokines and regulates important biological processes such as cell proliferation, differentiation, apoptosis, and immune response.<sup>10</sup> JAK inhibitors exert anti-inflammatory and





**Figure 4** Images during clinical treatment with abrocitinib (VISIA). (A–C) Abrocitinib 100 mg daily treatment week 12; (D–F) Abrocitinib 100 mg every other day treatment week 16; (G–I) Abrocitinib 100 mg twice weekly treatment week 20.

immunomodulatory effects by inhibiting JAK phosphorylation to reduce downstream inflammatory cytokine synthesis, inhibit T-cell proliferation, and ultimately block the synthesis and secretion of various inflammatory cytokines.<sup>11</sup>

Currently, JAK inhibitors are frequently used to treat inflammation-related disorders.<sup>12</sup> Abrocitinib, a highly selective JAK-1 inhibitor that is orally administered, was approved by the Food and Drug Administration in 2022 for the treatment of moderate to severe atopic dermatitis.<sup>13</sup> Studies have demonstrated that activation of the JAK/STAT signaling pathway

worsens inflammation in rosacea.<sup>14</sup> Inhibition of the JAK/STAT signaling pathway can indirectly suppress the expression of pro-inflammatory factors associated with rosacea, such as tumor necrosis factor- $\alpha$  (TNF- $\alpha$ ), IL-6, IL-8, and monocyte chemoattractant protein-1 (MCP-1).<sup>14</sup> Therefore, suppression of the JAK/STAT signaling pathway might be a crucial approach in treating rosacea. The JAK/STAT pathway is known to intersect with the signaling mechanisms of Toll-like receptor 2 (TLR2) and the reactive oxygen species (ROS)-induced oxidative stress system.<sup>15,16</sup> Activation of both TLR2 and the ROS-induced oxidative stress system can provoke inflammatory and vasodilatory responses, leading to symptoms indicative of rosacea.<sup>17,18</sup> Thus, JAK inhibitors offer new avenues for treating GR.

This study has several limitations that should be considered. Firstly, as this report is based on a single case, the results are not generalizable to all patients with GR. Secondly, the pathogenesis of GR remains unclear, and there is no unified protocol regarding the mechanism of JAK inhibitor treatment or standardized drug use. In addition, while abrocitinib was effective in this case, its efficacy cannot be guaranteed for all patients. Moreover, assessing the long-term efficacy and safety of abrocitinib requires long-term follow-up studies.

## Conclusion

GR is a rare subtype of rosacea that can be easily misdiagnosed or overlooked in clinical settings. Therefore, clinicians should consider this subtype when treating patients with butterfly-shaped redness on the face and histopathological evidence indicating non-caseating granulomatous inflammation, as proper identification is crucial for accurate diagnosis and treatment. In the current case, abrocitinib rapidly and effectively relieved symptoms, including the burning sensation and skin lesions, as well as improved the patient's quality of life. However, larger-scale observational studies are recommended to fully understand the potential benefits of abrocitinib in real-world clinical practice.

## Ethics Statement

The patient provided written informed consent for publication of this report and accompanying images. The Hospital Ethics Committees of the Affiliated People's Hospital of Hangzhou Medical College approved publishing the case details.

## Acknowledgments

We would like to express our gratitude to the patient for providing permission to publish their information. We thank Bullet Edits Limited for the linguistic editing and proofreading of the manuscript.

## Funding

This study was funded by the Young Talents Project of Zhejiang Medicine and Health Science and Technology Project (Grant number: 2022KY049).

## Disclosure

The authors have no conflicts of interest to declare.

## References

1. Uliandri J, Wang X, Liu Z, et al. Global rosacea treatment guidelines and expert consensus points: the differences. *J Cosmet Dermatol*. 2019;18(4):960–965.
2. Van Zuuren EJ, Arents BWM, van der Linden MMD, et al. Rosacea: new concepts in classification and treatment. *Am J Clin Dermatol*. 2021;22(4):457–465. doi:10.1007/s40257-021-00595-7
3. Jang YJ, Hong EH, Park EJ, et al. Immunohistochemical analysis of differences of toll-like receptor 2, mast cells, and neurofilaments between granulomatous rosacea and non-granulomatous rosacea. *Indian J Dermatol*. 2021;66(4):343–346. doi:10.4103/ijd.IJD\_18\_20
4. Mullanax MG, Kierland RR. Granulomatous rosacea. *Arch Dermatol*. 1970;101(2):206–211. doi:10.1001/archderm.1970.04000020076011
5. Slater N, Rapini RP. Lupus miliaris disseminatus faciei. In: *StatPearls [Internet]*. Treasure Island (FL): StatPearls Publishing; 2023.
6. Lee GL, Zirwas MJ. Granulomatous rosacea and periorificial dermatitis: controversies and review of management and treatment. *Dermatol Clin*. 2015;33(3):447–455. doi:10.1016/j.det.2015.03.009
7. Lane JE, Khachemoune A. Use of intense pulsed light to treat refractory granulomatous rosacea. *Dermatol Surg*. 2010;36(4):571–573. doi:10.1111/j.1524-4725.2010.01503.x

8. Sun YH, Man XY, Xuan XY, et al. Tofacitinib for the treatment of erythematotelangiectatic and papulopustular rosacea: a retrospective case series. *Dermatol Ther.* 2022;35(11):e15848. doi:10.1111/dth.15848
9. Li T, Wang H, Wang C, et al. Tofacitinib for the treatment of steroid-induced rosacea. *Clin Cosmet Investig Dermatol.* 2022;15:2519–2521. doi:10.2147/CCID.S392280
10. Hu X, Li J, Fu M, et al. The JAK/STAT signaling pathway: from bench to clinic. *Signal Transduct Target Ther.* 2021;6(1):402. doi:10.1038/s41392-021-00791-1
11. Xin P, Xu X, Deng C, et al. The role of JAK/STAT signaling pathway and its inhibitors in diseases. *Int Immunopharmacol.* 2020;80:106210. doi:10.1016/j.intimp.2020.106210
12. McLornan DP, Pope JE, Gotlib J, et al. Current and future status of JAK inhibitors. *Lancet.* 2021;398(10302):803–816. doi:10.1016/S0140-6736(21)00438-4
13. Deeks ED, Duggan S. Abrocitinib: first approval. *Drugs.* 2021;81(18):2149–2157. doi:10.1007/s40265-021-01638-3
14. Li T, Zeng Q, Chen X, et al. The therapeutic effect of artesunate on rosacea through the inhibition of the JAK/STAT signaling pathway. *Mol Med Rep.* 2018;17(6):8385–8390. doi:10.3892/mmr.2018.8887
15. Kumari A, Srivastava A, Jagdale P, et al. Lambda-cyhalothrin enhances inflammation in nigrostriatal region in rats: regulatory role of NF- $\kappa$ B and JAK-STAT signaling. *Neurotoxicology.* 2023;96:101–117. doi:10.1016/j.neuro.2023.04.003
16. Zhou J, Li T, Chen H, et al. ADAMTS10 inhibits aggressiveness via JAK/STAT/c-MYC pathway and reprograms macrophage to create an anti-malignant microenvironment in gastric cancer. *Gastric Cancer.* 2022;25(6):1002–1016. doi:10.1007/s10120-022-01319-4
17. Zhang Y, Li Y, Zhou L, et al. Nav1.8 in keratinocytes contributes to ROS-mediated inflammation in inflammatory skin diseases. *Redox Biol.* 2022;55:102427. doi:10.1016/j.redox.2022.102427
18. Shen S, Yan G, Cao Y, et al. Dietary supplementation of n-3 PUFAs ameliorates LL37-induced rosacea-like skin inflammation via inhibition of TLR2/MyD88/NF- $\kappa$ B pathway. *Biomed Pharmacother.* 2023;157:114091. doi:10.1016/j.biopha.2022.114091

Clinical, Cosmetic and Investigational Dermatology

Dovepress

**Publish your work in this journal**

Clinical, Cosmetic and Investigational Dermatology is an international, peer-reviewed, open access, online journal that focuses on the latest clinical and experimental research in all aspects of skin disease and cosmetic interventions. This journal is indexed on CAS. The manuscript management system is completely online and includes a very quick and fair peer-review system, which is all easy to use. Visit <http://www.dovepress.com/testimonials.php> to read real quotes from published authors.

Submit your manuscript here: <https://www.dovepress.com/clinical-cosmetic-and-investigational-dermatology-journal>