



Length of the healthy and pathological small intestine in patients with Crohn's disease: calculations using computed tomography and magnetic resonance enterography

Laura Maria Minordi

Luigi Larosa

Maria Gabriella Brizi

Alessandro Armuzzi

Riccardo Manfredi

ABSTRACT

Many patients with Crohn's disease (CD) require surgical intervention during their lifetime. A correct preoperative assessment of the intestinal length is necessary to predict and quickly treat postoperative nutritional disorders. The aim of this paper is to explain the method used in our hospital to measure intestinal length in patients with CD and its usefulness for making the correct therapeutic decision. Vessel analysis software is used to measure small bowel length through computed tomography enterography (CTE) or magnetic resonance enterography (MRE). The method permits two-dimensional and three-dimensional curved multiplanar reconstructions and allows each loop to be stretched using a point-by-point identification of the intestinal lumen. Subsequently, the software allows the creation of a virtual image, on which the intestinal length is measured linearly. This methodology was tested on three patients; patients 1 and 3 were examined using CTE, and patient 2 was examined using MRE. The outcomes were discussed at a multidisciplinary team meeting (MDT). As a result, surgical ileocolic resection was recommended for patient 1 and medical therapy for patients 2 and 3. Intestinal length measurements have proved vital during MDTs for making appropriate therapeutic decisions.

KEYWORDS

Bowel, Crohn's disease, CT, inflammatory bowel disease, MR enterography

Many patients with ileocolic Crohn's disease (CD) require one or more surgical interventions during their lifetime. In these patients, the indication for surgery is based on various criteria, such as the presence of stricturing or perforating disease, risk for postoperative recurrence, grade of inflammatory activity, and length of the intestinal loops involved. If the bowel resection is too extensive and residual small intestine is less than 75 cm, the patient may suffer from short bowel syndrome.¹

The exact length of the small intestine remains controversial in the literature, and its measurement depends on the techniques used. In addition, some studies have reported that the length of the small bowel appears to be variable, depending on the age, sex, weight, and height of the patient.^{2,3} A study by Regan et al.⁴ found that stenosis in patients with CD can occur because of the increased contractile activity of fibroblasts at the level of the extracellular matrix, appreciable both in healthy areas and in macroscopically inflamed regions. For this reason, patients with CD have a shorter bowel than that of the normal population.^{2,3}

In this paper, we describe a method for measuring intestinal loops through computed tomography enterography (CTE) or magnetic resonance enterography (MRE) using vessel analysis software. The method enables two-dimensional (2D) and three-dimensional (3D) curved multiplanar reconstructions (MPRs) and allows each loop to be stretched. Subsequently, the software creates a virtual image through which intestinal length can be measured linearly. This method has been used successfully in the evaluation of patients with acute diverticulitis,

From the UOC Radiologia Addomino-Pelvica, Dipartimento di Diagnostica per immagini, Radioterapia Oncologica ed Ematologia (L.M.M. ✉lauramaria.minordi@policlinicogemelli.it, L.L., M.G.B., R.M.), Fondazione Policlinico Universitario Agostino Gemelli, IRCCS, Roma, Italia; Università Cattolica del sacro Cuore, Roma, Italia (M.G.B., R.M.); Unit of Gastroenterology (A.A.), Fondazione Policlinico Universitario Agostino Gemelli IRCCS, Roma, Italia.

Received 13 September 2021; revision requested 31 October 2021; last revision received 10 December 2021; accepted 27 December 2021.



Epub: 05.01.2023

Publication date: 31.01.2023

DOI: 10.5152/dir.2022.21968

You may cite this article as: Minordi LM, Larosa L, Brizi MG, Armuzzi A, Manfredi R. Length of the healthy and pathological small intestine in patients with Crohn's disease: calculations using computed tomography and magnetic resonance enterography. *Diagn Interv Radiol.* 2023;29(1):24-28.

revealing a correlation between the lengths of colon involved, considered as a percentage of the entire colon, and the need for a patient to be hospitalized.⁵ The same method can be used to measure the intestinal length in patients with CD in many clinical situations, particularly when it is necessary to plan a surgical intervention in patients who have already undergone intestinal resection to avoid short bowel syndrome.¹

Technique

In our hospital, MRE and CTE are performed after the oral administration of a polyethylene glycol solution (PEG). We administer 1.5–2.0 L of PEG in doses of 100 mL starting 35 min before the MR and CT examinations.

When a patient has a known diagnosis of CD, we perform CTE only after the injection of an iodinated contrast medium. The CT technical parameters are presented in Table 1.

In MRE, the sequences are performed before and after the intravenous administration of a paramagnetic contrast medium: a single-shot T2-weighted and balanced steady-state-free precession sequence, T2-weighted fat-suppressed sequence, multiphase 3D T1-weighted fat-suppressed postcontrast image sequence, and diffusion-weighted imaging (values usually 0–800 or 0–600 s/mm²) sequence. The MR parameters are set out in Table 2.

The imaging criteria for CD diagnosis are summarized in Table 3.

The CT and MR examinations are revised using postprocessing technologies such as MPR, and a specific postprocessing 2D and 3D software (Vue PACS Carestream) is applied to these images. We select the series of images for the reconstruction using the “view as” button and then select “vessel analysis”. In this way, we obtain 3D and 2D reconstructions in axial, coronal, and sagittal planes. Using the manual protocol, we create a virtual image that makes the intestine tubular through the point-by-point identification of the intestinal lumen distended through PEG. On the image thus obtained, we can perform the necessary measurements to evaluate the patient using a linear measurement.

The time needed to perform the measurements is variable. Based on our calculations, between 20 and 30 min is required for each measurement, to which the time necessary to view the images and draft the report must be added.

Indications for surgical resection or the modification/confirmation of medical therapy are discussed in a multidisciplinary team meeting (MDT), held in our department once a week, in which radiologists, gastroenterologists, surgeons, and pathologists participate.

Case 1

Patient 1 is a 74-year-old man with known CD treated through medical therapy. He was hospitalized for persistent abdominal pain and serotonin fever (>38°C), but his symptoms did not respond to medical therapy. His bowel movements were regular, and there was only one incident of vomiting. At admission, his blood tests were normal except for C-reactive protein (CRP) values (19.8 mg/L; normal values <5.0). The patient underwent CTE (Figure 1), and the results were discussed

in the MDT. The MDT decision was to perform intestinal resection, with the intestine measured during ileocolonic resection using a radiological measurement.

Case 2

Patient 2 is a 43-year-old woman with known stenosing CD treated through medical therapy. She was hospitalized for worsening abdominal pain with constipation. Blood tests: normocytic anemia (hemoglobin: 10.4 g/dL; normal values 12.0–15.0), erythrocyte sedimentation rate (ESR): 43 mm (normal values 0–20), CRP: 6 mg/L (normal values <5.0). During hospitalization, the treatments were effective, and her condition continued to improve.

Subsequently, MRE was performed (Figure 2), and the results were discussed in the MDT. The MDT decision was to continue medical therapy.

Case 3

Patient 3 is a 36-year-old man with known CD treated through medical therapy. He was experiencing severe pain following diarrhea (about 2–4 discharges per day). He had also experienced weight loss of approximately 5–6 kg in the previous 2 months.

In the endoscopic examination, the ileocecal valve appeared substenotic and was covered by edematous and bleeding mucosa, and a single ulcer was detected. The mucosa of the ileum also appeared edematous and sensitive to bleeding with ulcers.

Blood tests on admission to the hospital were normal except for CRP (20.3 mg/L; normal values <5.0) and ESR (30 mm; normal values 0–20).

Main points

- Many patients with ileocolic Crohn's disease require one or more surgical interventions during their lifetime. In these patients, the indication for surgery is based on various criteria, such as the presence of stricturing or perforating disease, risk of postoperative recurrence, grade of inflammatory activity, and length of the intestinal loops involved.
- If the bowel resection is too extensive and residual small intestine is less than 75 cm, the patient may suffer from short bowel syndrome.
- The preoperative assessment of intestinal length is useful for predicting and quickly treating postoperative nutritional disorders.
- We recommend that vessel analysis software be employed for measuring the small bowel loops using computed tomography and magnetic resonance enterography.

Table 1. Computed tomography parameters

Type of CT scanner	64-row spiral CT
Slice thickness	1.5 mm
Interval	1.25 mm
Automated tube current modulation	(200–700 mA)
Pitch	0.969 mm/rot
Rotation time	0.9 s
Modality of intravenous injection of iodinated contrast medium	100–130 mL of iodinated contrast agent is administered in two separate and consecutive boluses: the first bolus at a rate of 1.5 mL/s (1/3 of the total amount of iodinated contrast agent given to the patient), the second bolus at a rate of 3 mL/s (the remaining 2/3 of the total amount of iodinated contrast agent given to the patient). The images are acquired 75 s after intravenous injection. This modality of administration allows an arterial and portal study of the abdomen in a single scan.

CT, computed tomography; mm, millimeters; mA, milliamperere; s, second.

Table 2. Magnetic resonance parameters					
Sequence details	T1 Gradient echo	T2 Gradient echo	T2 Spin echo	T2 fat-saturated Spin echo	DWI
Pulse sequence	FSPGR	FIESTA	SSFSE	SSFSE	EPI
Patient position	Supine				
Anatomical coverage	From the top of the liver dome to pubic symphysis				
RF coil	Phased array (multi-channel RF coil)	Phased array (multi-channel RF coil)	Phased array (multi-channel RF coil)	Phased array (multi-channel RF coil)	Phased array (multi-channel RF coil)
Breath-hold during MR examination/respiratory gating	Yes (single or multiple)	Yes (single or multiple)	Yes (single or multiple)	Yes (single or multiple)	Respiratory triggering
Plane	Axial/coronal	Axial/coronal	Axial/coronal	Axial/coronal	Axial/coronal
TR, ms	Short/minimum	Short/minimum	Long (optimal)	Long (optimal)	Long (optimal)
TE, ms	Minimum	Minimum	60–100 (optimal)	100	60
Flip angle (degrees)	>70 (or optimal)	>45 (or optimal)	180 (or optimal)	180 (or optimal)	<90 (or optimal)
NEX	>1 (or optimal)	>1 (or optimal)	>1 (or optimal)	>1 (or optimal)	>1 (or optimal)
Slice thickness, mm	4 (3D acquisition) 6–7 (2D acquisition)	6–7	6–7	5	6
Slice gap, mm	0.5–1	0.5–1	0.5–1	1	1
Matrix	256 256 or site optimal	256 256 or site optimal	256 256 or site optimal	320 224 or site optimal	320 224 or site optimal
Slice acquisition order	Interleaved/sequential	Interleaved/sequential	Interleaved/sequential	Interleaved/sequential	Interleaved/sequential
FOV (cm)	22–48 (or optimal to cover all anatomy)	22–48 (or optimal to cover all anatomy)	22–48 (or optimal to cover all anatomy)	22–48 (or optimal to cover all anatomy)	22–48 (or optimal to cover all anatomy)
b value	-	-	-	-	600–800

MR, magnetic resonance; DWI, diffusion-weighted imaging; RF, radiofrequency; TR, repetition time; TE, echo time; NEX, number of excitations; mm, millimeters; cm, centimeters; FOV, field of view; FSPGR, fast-spoiled gradient echo; FIESTA, fast imaging employing steady-state acquisition; SSFSE, single-shot fast-spin echo; EPI, echo-planar imaging.

Table 3. Imaging criteria for the diagnosis of Crohn's disease	
Mural thickening	Wall thickness more than 3 mm
Bowel wall edema	In CT scans: hypodensity of submucosal layer In MR imaging: wall hyperintense signal compared with skeletal muscle on T2-weighted sequences
Mucosal ulcers	Deep depressions in the mucosal surface
Bowel wall enhancement	Stratified in active inflammatory subtype: intense enhancement of the mucosa and serosa and hypodensity (CT) or low signal intensity (MR) of submucosa Homogeneous in fibro-stenotic subtype
Engorgement of vasa recta	Hyperemia of the near mesentery
Perienteric stranding	Loss of the normal sharp interface between the bowel wall and mesentery
Fibrofatty proliferation	Excess of mesenteric fat
Stenosis (fibrostenotic subtype)	Upstream dilatation with loop caliber greater than 3 cm
Fistula (fistulizing/perforating subtype)	Communication with a near structure (e.g., enteroenteric, enterocolic, enterocutaneous, enterovesicular fistulas)
Abscess	Capsulated fluid collection near pathological loop; it could contain air
Lymph node enlargement	Short diameter greater than 1 cm

CT, computed tomography; MR, magnetic resonance.

The patient underwent CTE to determine the appropriate treatment (Figure 3), and the results were discussed in the MDT. The MDT decision was to not perform surgical therapy because of the high risk of short bowel syndrome and to continue medical therapy.

Discussion

Previously, the measurement of the length of the small intestine was performed using a barium X-ray.³ Currently, the calculation of the length of the intestine is conducted through MRE or CTE, using vascular imaging software,⁶ 2D MPR,⁷ or an automatic calculation method.⁸

In our hospital, two gastrointestinal radiologists use the method described here to measure intestinal length (both small bowel and colon) in all patients with CD, especially in patients with extensive alteration of the small bowel who must undergo surgery. Coronal and sagittal MPR using CTE or coronal and axial images from MRE do not allow the small bowel to be visualized in its longitu-

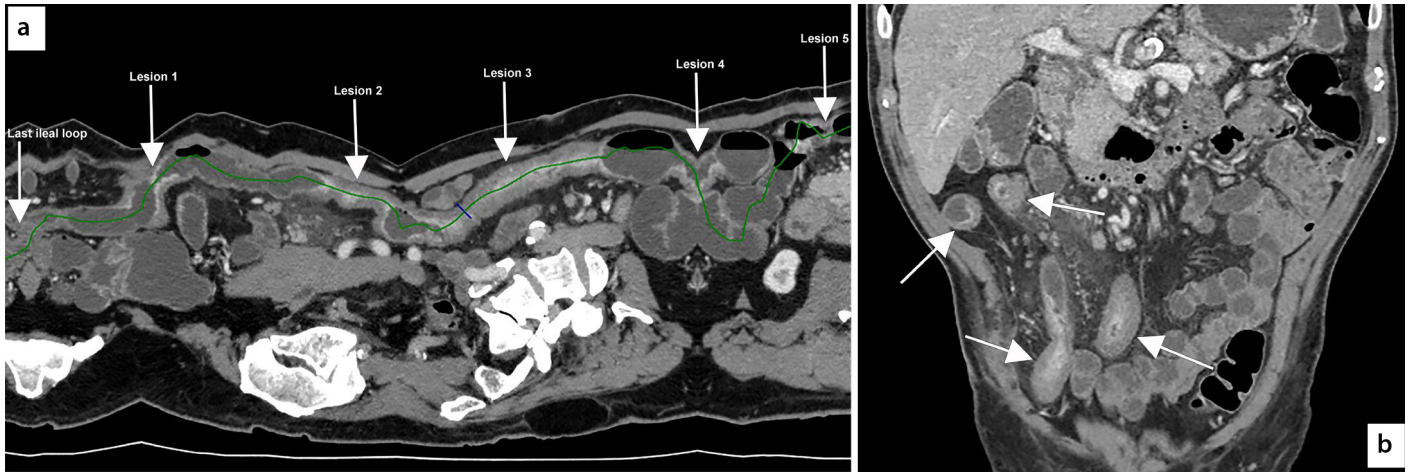


Figure 1. Computed tomography enterography (a) reveals extensive small bowel alteration affecting the last 80 cm of the ileum, characterized by the presence of multiple thick-walled and reduced-caliber tracts alternating with normal or increased caliber tracts, which are also represented in the reconstructions obtained through vessel analysis. In this reconstruction, it is possible to accurately assess the overall extent of the disease and each lesion. Last ileal loop: length of 45 mm, lesion 1: 32 mm, lesion 2: 54 mm, lesion 3: 130 mm, lesion 4: 32 mm, lesion 5: 40 mm. Lesions 2 and 3 exhibit increased density of the perivisceral adipose tissue. Between lesions 3 and 4 and between lesions 4 and 5, the loops are dilated (maximum caliber: 35 mm). Multiplanar coronal reconstruction (b) does not allow the small bowel to be visualized in its longitudinal extension because of the long section of intestine affected by the pathology.

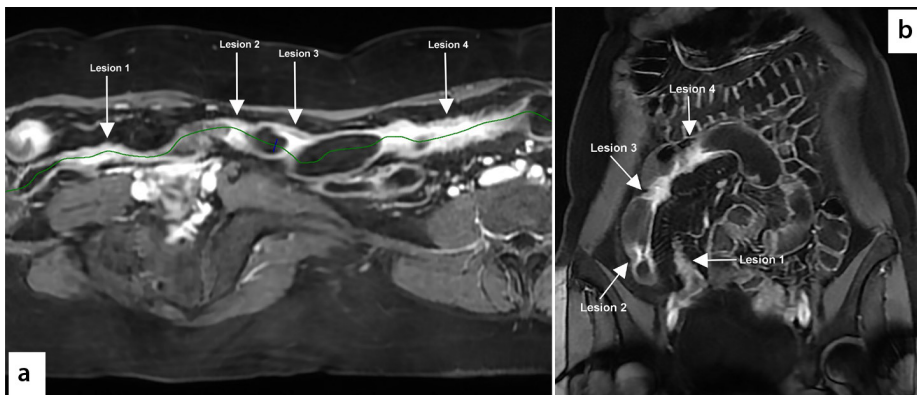


Figure 2. Magnetic resonance enterography (a) reveals small bowel alteration affecting the last 40 cm of the ileum, characterized by the presence of four thick-walled and reduced-caliber tracts, which are represented in the reconstructions obtained through vessel analysis. In this reconstruction, it is possible to accurately assess the overall extent of the disease and each lesion. Lesion 1: length of 70 mm, lesion 2: 10 mm, lesion 3: 14 mm, lesion 4: 100 mm. Coronal T1 image performed after the intravenous injection of gadolinium contrast medium (b) does not allow the small bowel to be visualized in its longitudinal extension because of the long section of intestine affected by the pathology; however, it was possible to measure the length of each pathological loop in the various planes.

nal extension if a long section of intestine is affected by the pathology. In this paper, we have described a method to measure intestinal length and presented three patients with CD.

Patient 1 had a diseased intestine less than a meter long and no response to medical therapy; he therefore underwent ileal resection surgery. After ileocolonic resection, the intestine measurement was consistent with the radiological measurement, and no

complications in the postsurgical course were identified. Patient 2 exhibited signs of disease activity, and the CT showed small bowel alteration affecting the last 40 cm of the ileum. He responded to medical therapy, and therefore, in the MDT, it was decided to continue with this course of treatment. Patient 3 had extensive bowel involvement with the consequent high risk of short bowel syndrome; it was therefore decided to continue medical therapy.

The technique described in this paper is used to calculate the length of both the small intestine and colon. The measurement was performed on the colon for diverticular disease.⁵ In CD, it has greater practical utility for measuring the healthy or pathological small intestine to avoid performing an extensive resection that would lead to short bowel syndrome. Breathing artifacts do not hinder the measurement either in CT or MR.

If patients have fistulas, they are a candidate for bowel resection surgery, and the radiological support consists of measuring the length of the pathological small bowel loops, residual normal bowel, and distance of the fistula from the ileocecal valve or from the Treitz. In the case of stenosis, using this method enables the length of the stenosis to be measured. In addition, for stenosis or skip lesions, their distance from the ileocecal valve can be calculated, providing information that could be useful in cases of stricturoplastic therapy or the endoscopic dilation of the stenosis.

In conclusion, the vessel analysis method is easy to perform to measure the extent of the disease, and it is usually available in radiological departments. The measurements performed by us have always proved useful during MTDs for both clinicians and surgeons to make the correct therapeutic (medical or surgical) decision.

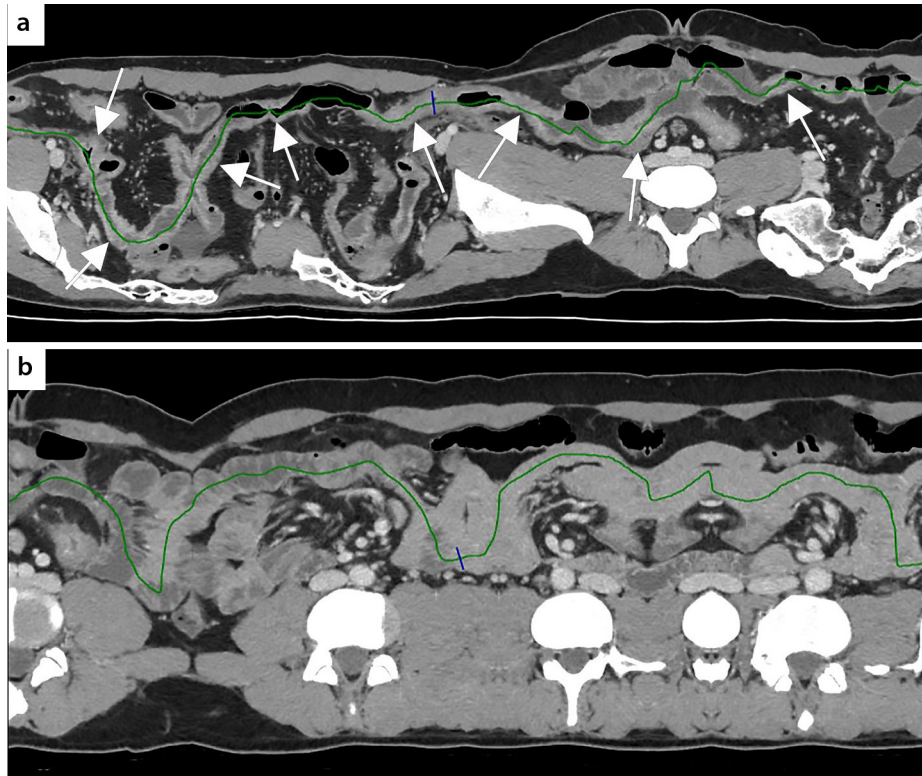


Figure 3. Computed tomography enterography reconstruction (a) reveals extensive alteration of the small loops, both the distal jejunum and ileum, including the last ileal loop and ileocecal valve, for at least 140 cm. The ileocecal valve is poorly identifiable. Immediately upstream, further ileal loops are observed with thickened walls (maximum thickness 10 mm) with an extension of approximately 30 cm and a lumen of reduced caliber (3 mm). The ileum upstream and distal jejunum have at least eight pathological tracts with thickened walls (maximum thickness 7 mm), with a longitudinal extension varying from 2 to 6 cm, and reduced caliber (residual lumen of 4 mm), alternating with tracts of normal or slightly increased caliber (maximum caliber: 25 mm). These alterations are also associated with hypervascularization, increased density of adipose tissue, and reactive lymph nodes in the mesentery. (b) At the request of the surgeon, the healthy intestine was measured and was approximately 70 cm.

Conflict of interest disclosure

The authors declared no conflicts of interest.

References

1. Limketkai BN, Parian AM, Shah ND, Colombel JF. Short bowel syndrome and intestinal failure in Crohn's disease. *Inflamm Bowel Dis.* 2016;22(5):1209-1218. [\[CrossRef\]](#)
2. Glehen O, Lifante JC, Vignal J, et al. Small bowel length in Crohn's disease. *Int J Colorectal Dis.* 2003;18(5):423-427. [\[CrossRef\]](#)
3. Shatari T, Clark MA, Lee JR, Keighley MR. Reliability of radiographic measurement of small intestinal length. *Colorectal Dis.* 2004;6(5):327-329. [\[CrossRef\]](#)
4. Regan MC, Flavin BM, Fitzpatrick JM, O'Connell PR. Stricture formation in Crohn's disease: the role of intestinal fibroblasts. *Ann Surg.* 2000;231(1):46-50. [\[CrossRef\]](#)
5. Minordi LM, Larosa L, Berté G, Pecere S, Manfredi R. CT of the acute colonic diverticulitis: a pictorial essay. *Diagn Interv Radiol.* 2020;26(6):546-551. [\[CrossRef\]](#)
6. Sinha R, Trivedi D, Murphy PD, Fallis S. Small-intestinal length measurement on MR enterography: comparison with in vivo surgical measurement. *AJR Am J Roentgenol.* 2014;203(3):274-279. [\[CrossRef\]](#)
7. Brouquet A, Rangheard AS, Ifergan J, et al. The accuracy of preoperative imaging in measuring the length of the ileocolic segment affected by Crohn's disease: a prospective cohort study. *Colorectal Dis.* 2017;19(5):437-445. [\[CrossRef\]](#)
8. Wilson NA, Park HS, Lee KS, Barron LK, Warner BW. A novel approach to calculating small intestine length based on magnetic resonance enterography. *J Am Coll Surg.* 2017;225(2):266-273.e1. [\[CrossRef\]](#)