



# Safety and efficacy of flow diverter stents in the treatment of middle cerebral artery aneurysms: a single-center experience and follow-up data

Efe Soydemir   
Cemal Aydın Gündoğmuş   
Derya Türeli   
Nurten Andaç Baltacıoğlu   
Yaşar Bayri   
Feyyaz Baltacıoğlu 

## PURPOSE

This study aims to evaluate the safety and efficacy of flow diverters (FDs) in the treatment of middle cerebral artery (MCA) aneurysms and share the follow-up (F/U) results.

## METHODS

The treatment and F/U results of 76 MCA aneurysms treated with the flow re-direction endoluminal device (FRED), FRED Jr., and pipeline embolization device (PED) FD stents were evaluated retrospectively. The aneurysm occlusion rates were compared between FDs, and the integrated and jailed branches were evaluated through follow-ups. The oversizing of the stent was compared between occluded/non-occluded aneurysms and integrated branches.

## RESULTS

The mean F/U duration was  $32 \pm 6.3$  months, and the mean aneurysm diameter was 4.45 mm. A total of 61 (80.3%) aneurysms were wide-necked; 73 (96.1%) were saccular; 52 (68.4%) were located at the M1 segment; and 36 (45.6%) FREDs, 23 (29.1%) FRED Jr.s, and 19 (24.1%) PEDs were used for treatment. The overall occlusion rates for the 6-, 12-, 24-, 36-, and 60-month digital subtraction angiographies were 43.8%, 63.5%, 73.3%, 85.7%, and 87.5% respectively. The last F/U occlusion rates were 67.6% for FRED, 66.7% for PED, and 60.6% for FRED Jr. ( $P = 0.863$ ). An integrated branch was covered with an FD during the treatment of 63 (82.8%) aneurysms. A total of six (10%) of the integrated branches were occluded without any symptoms at the last F/U appointment. The median oversizing was 0.45 (0–1.30) for occluded aneurysms, and 0.50 (0–1.40) for non-occluded aneurysms ( $P = 0.323$ ). The median oversizing was 0.70 (0.45–1.10) in occluded integrated branches and 0.50 (0–1.40) in non-occluded branches ( $P = 0.131$ ). In-stent stenosis was seen in 22 (30.1%) of the stents at the 6-month F/U and in only 2 (4.7%) at the 24-month F/U. Thus, none of the patients had any neurological deficits because of the in-stent stenosis. Severe in-stent stenosis was seen in two stents.

## CONCLUSION

MCA aneurysms tend to be complex, with integrated branches and potentially wide necks. FD stents are safe and effective in the treatment of MCA aneurysms, and the patency of the side and jailed branches is preserved in most cases. Higher occlusion and lower in-stent stenosis rates are seen with longer F/U durations.

## KEYWORDS

Aneurysm, flow diverter, FRED, MCA, pipeline

From the Department of Radiology (E.S., C.A.G., D.T., F.B.), [feyyazb@amerikanhastanesi.org](mailto:feyyazb@amerikanhastanesi.org), Marmara University Faculty of Medicine, Istanbul, Turkey; Department of Radiology (C.A.G.), Koç University Hospital, Istanbul, Turkey; Department of Radiology (N.A.B., F.B.), VKV Amerikan Hospital, Istanbul, Turkey; Department of Neurosurgery (Y.B.), Marmara University Faculty of Medicine, Istanbul, Turkey.

This study was presented in Annual Congress of Turkish Society of Neuroradiology on 18 February 2021.

Received 19 October 2021; revision requested 29 November 2021; last revision received 27 March 2022; accepted 04 April 2022.



Epub: 02.01.2023

Publication date: 29.03.2023

DOI: 10.4274/dir.2022.211050

You may cite this article as: Soydemir E, Gündoğmuş CA, Türeli D, Andaç Baltacıoğlu N, Bayri Y, Baltacıoğlu F. Safety and efficacy of flow diverter stents in the treatment of middle cerebral artery aneurysms: a single-center experience and follow-up data. *Diagn Interv Radiol.* 2023;29(2):350-358.

**M**iddle cerebral artery (MCA) aneurysms constitute approximately 22% of all cerebral aneurysms. They are generally wide-necked, have accompanying integrated branches, and sometimes have complex anatomy with angulation. Thus, the endovascular treatment of MCA aneurysms is challenging with conventional treatment strategies.<sup>1</sup>

Flow diverter (FD) stents have evolved aneurysm treatment to a different level. They do not just restrict blood flow into the aneurysm sac but also reconstruct the parent artery by remodelling the aneurysm neck. FDs decrease the blood flow into the aneurysm sac with their braided mesh structure. Through this hemodynamic alteration, endothelial remodeling across the neck of the aneurysm enables occlusion of the aneurysm.<sup>2</sup>

Several studies have demonstrated the effectiveness and safety of FDs in the treatment of intracranial aneurysms. Treatment of internal carotid artery (ICA) aneurysms using flow diversion has been widely studied; however, the data intended for cases beyond the circle of Willis, especially MCA aneurysms, is still limited.<sup>3-5</sup>

This study aims to retrospectively evaluate the safety and efficacy of FDs in the treatment of MCA aneurysms and to share the follow-up (F/U) results.

## Methods

This retrospective study was approved by the local ethics committee (protocol no: 09.2020.704). The interdisciplinary consensus among the neuro-interventional radiology and neurosurgery departments was sought in each patient. In addition, written informed consent was given by all the patients for endovascular treatment.

### Patient and aneurysm characteristics

All patients with MCA aneurysms [M1 [(horizontal) and bifurcation (insular)] who were treated with at least one FD stent at a

referral center between May 2013 and December 2019 were enrolled in this study. Most of the M1 aneurysms in this study had integrated branches, and all bifurcation aneurysms had a neck that was hard to by-pass. These were the main factors for choosing FD treatment for the patients. The only exclusion criterion was ruptured aneurysm. One patient with a ruptured blister aneurysm was excluded from the study, and two patients with a total number of three aneurysms were lost during the F/U period. Only procedural and pre-procedural clinical data were analyzed.

In addition to aneurysm location and diameter, the aneurysm morphology (saccular, fusiform, and blister), aneurysm neck size, presence of integrated and jailed branches, and parent artery diameters were recorded. Oversizing was the stent diameter minus the diameter of the proximal parent artery (mm).

### Antiaggregation

All patients were administered with preprocedural dual antiplatelet therapy. Patients under clopidogrel and prasugrel were tested for platelet inhibition using the Multiplate Analyzer (Roche Diagnostics International Ltd, Rotkreuz ZG, Switzerland) before the procedure. The loading doses were 300 mg for clopidogrel 4 days before the procedure, 40 mg for prasugrel 12 h before the procedure, and 180 mg for ticagrelor as a loading dose directly before the operation. This was conducted in both urgent and scheduled procedures without testing. In addition, famotidine was initiated in all patients to prevent possible gastrointestinal tract bleeding, which could potentially lead to the cessation of antiaggregant therapy. Thus, all patients received either dual antiplatelet therapy with 75 mg clopidogrel + 100 mg acetylsalicylic acid (ASA), 180 mg ticagrelor + 100 mg ASA, or 10 mg prasugrel as monotherapy (for  $\geq 6$  months) + ASA (for life).

### Endovascular procedure

All procedures in this study were performed by a single neuroendovascular interventionalist with >10 years of FD experience.

All treatments were performed under general anesthesia. A 6F long introducer sheath was placed to the distal segment of the common carotid artery through femoral access, and a 6F distal access catheter (Navien: Covidien Vascular Therapies, Mansfield, MA, USA or Sofia: MicroVention, Tustin, California, USA) was advanced co-

axially into the ICA as distally as possible. To reveal the anatomy, determine working projections, and measure parent artery diameters, two-dimensional and three-dimensional rotational angiographic images were acquired. Rebar 27 (Covidien Vascular Therapies, Mansfield, MA, USA), Marksman (Covidien Vascular Therapies, Mansfield, MA, USA), or Headway 27 (MicroVention, Tustin, CA, USA) for the pipeline embolization device (PED) (ev3 Neurovascular, Irvine, CA, USA), Headway 27 for the flow re-direction endoluminal device (FRED) (MicroVention, Tustin, CA, USA), and Headway 21 for the FRED Jr. (MicroVention, Tustin, CA, USA) were used in combination with 0.014-inch or 0.016-inch microwires to by-pass the aneurysm neck. The microcatheter was advanced as distally as possible from the neck of the aneurysm. Then, the device was loaded into the microcatheter hub through a hemostatic valve and placed across the target landing zone. The FD device was deployed through a combination of unsheathing, pushing, and maintaining forward tension on the delivery wire of the device, or pulling and loading the microcatheter under continuous fluoroscopy. Simultaneously with the device deployment, stent apposition to the vessel wall was continuously checked. After satisfactory deployment and apposition of the device, a control angiogram was acquired to examine the device lumen and integrated/jailed branch patencies. After device deployment, the perioperative aneurysmal sac filling degree was recorded according to the O'Kelly Marotta (OKM) grading scale.

After the long introducer sheath placement, systemic heparinization was performed with a 5,000 international units intravenous (IV) bolus injection. The target activated clotting time was 2–2.5  $\times$  the baseline. Heparinization was not reversed at the end of the procedures.

### Follow-up treatment

Most of the patients were discharged from the hospital on the second day after the procedure and evaluated clinically on the fifth day. The digital subtraction angiography (DSA) F/U appointments were scheduled at 6, 12, 24, 36, and 60 months after the treatment.

The F/U DSA images were assessed in terms of aneurysm filling, FD stent patency, and integrated/jailed branch patency. The OKM grading scale was used to grade the aneurysmal filling and contrast stagnation

#### Main points

- Middle cerebral artery (MCA) aneurysms tend to be complex.
- Flow diverter stents are safe and effective in the treatment of MCA aneurysms.
- Higher occlusion rates are seen with a longer follow-up time.
- Patency of the side and jailed branches is preserved with flow diverter stents.

phase,<sup>6</sup> and OKM C3 and D grades were accepted as adequate occlusion. The FD stent patency was classified as A: patent; B: <50% stenosis; C: >50% stenosis; D: occluded; and whether the patient was symptomatic or not. Integrated/jailed branch patency was evaluated with regard to the pretreatment images as patent, decreased-caliber, and occluded; it was also determined whether the patient was symptomatic or not.

### Statistical analysis

Descriptive statistics were presented (minimum–maximum) as the median for non-normally distributed variables and as the mean and standard deviation for the normally distributed variables. Categorical variables were reported as frequencies and percentages. The Pearson chi-square test was used to investigate the effect of the FD stent type on aneurysmal occlusion, and the Mann–Whitney U test was used to analyze the effects of oversizing the stent on the aneurysm occlusion and integrated branch patency. The significance level was established as  $\alpha = 0.05$ . The IBM SPSS 21.0 software was used for data analysis.

## Results

### Patient and aneurysm characteristics

A total of 67 patients (52 female; median age, 58 years; age range, 30–75 years) with 76 MCA aneurysms were enrolled in the study. The mean aneurysm diameter was 4.45 mm (range, 1.1–12 mm). Only 5 aneurysms were larger than 10 mm. A total of 61 (80.3%) aneurysms were wide-necked, and 73 (96.2%) were saccular. Furthermore, two aneurysms were blister-like, and one was fusiform in shape. A total of 52 aneurysms (68.4%) were located at the M1 segments, and 24 (31.6%) were located at the MCA bifurcations. The demographics of the treated patients and baseline characteristics of the aneurysms are summarized in Table 1.

### Treatment characteristics

A total number of 79 FD stents were used in this study. The most frequently used device was FRED (45.6%), followed by FRED Jr. (29.1%), and PED (24.1%). Only one aneurysm was treated with Surpass (Stryker Neurovascular, Fremont, CA, USA).

In three cases, a second stent was deployed in a telescopic fashion because of the stent shortening. Coiling was used as an adjunctive technique in four large aneurysms, and an FD stent was used as second-line treatment in four cases (three of them were previously treated with Woven Endo-Bridge (WEB) intra-saccular FD and one with surgical clipping).

### Occlusion rates

A total of 65 patients with 73 aneurysms were followed up with (mean F/U time,  $32.1 \pm 6.3$  months). A total of 63 (86%) aneurysms had  $\geq 12$  months of DSA control, and 45 (62%) aneurysms had  $\geq 24$  months of DSA control. Only 10 (13.6%) aneurysms had a F/U duration of <12 months.

The overall occlusion rates for 6-, 12-, 24-, 36-, and 60-month DSA were 43.8%, 63.5%, 73.3%, 85.7%, and 87.5% respectively.

According to the last F/U time, the mean F/U period was  $24.7 \pm 18.8$  months, and the last F/U occlusion rates were 67.6% for FRED, 66.7% for PED, and 60.6% for FRED Jr. ( $P = 0.863$ ).

Since the flow dynamics differ between side-wall and bifurcation aneurysms, the occlusion rates of M1 and bifurcation aneurysms were compared. A total of 31 (64.6%) M1 aneurysms, and 16 (66.7%) bifurcation aneurysms were occluded on the last F/U ( $P = 0.861$ ) (Table 2).

### Integrated and jailed branches

An integrated branch is any branch arising from the aneurysm sac or neck, while a jailed branch is any branch arising from the parent artery adjacent to the aneurysm and covered with an FD stent. An integrated branch was covered with an FD during the treatment of 63 (82.8%) aneurysms (Figure 1). The most common was the anterior temporal artery, followed by the frontal branches (31.7% and 30.2%, respectively). A percentage of 6.6% (4/60) of the integrated branches at the 6-month F/U and 10% (6/60) at the last F/U were occluded without any symptoms (Table 3).

A total of 12 MCA branches were jailed using an FD. The most common one was also the anterior temporal artery. At the six-month F/U, one jailed branch was occluded without any neurological deficit. A total of 11/12 jailed branches were patent at the 12-month F/U, and 7/8 were patent at the 24-month F/U.

**Table 1.** Demographic data, aneurysm, and treatment characteristics

	n (%)
Age*	57.8 $\pm$ 9
<b>Gender</b>	
Female	52 (77.6)
Male	15 (22.4)
<b>Aneurysm type</b>	
Saccular	73 (96.1)
Blister	2 (2.6)
Fusiform	1 (1.3)
Aneurysm diameter (mm)*	2.5 $\pm$ 2.6
Wide neck	61 (80.3)
Aneurysm neck diameter (mm)*	3.8 $\pm$ 2.8
<b>Aneurysm location</b>	
MCA M1	52 (68.4)
MCA Bifurcation	24 (31.6)
<b>Flow diverter stent</b>	
FRED	36 (45.6)
FRED Jr.	23 (29.1)
PED	19 (24.1)
Surpass	1 (1.3)
Additional coil	4 (5.3)
Integrated branch	63 (82.2)
Jailed branch	12 (15.8)
Follow-up duration (months)*	32.1 $\pm$ 6.3

\*Mean  $\pm$  standard deviation. MCA, middle cerebral artery; FRED (Jr.), flow re-direction endoluminal device (Jr.); PED, pipeline embolization device.

Furthermore, the respective effects of stent oversizing on the aneurysm and integrated branch occlusion were investigated. For both, oversizing was compared between occluded and non-occluded groups. The median oversizing was 0.45 mm (0–1.30 mm) for occluded aneurysms and 0.50 mm (0–1.40 mm) for non-occluded aneurysms ( $P = 0.323$ ). The median oversizing for occluded integrated branches was 0.70 mm (0.45–1.10 mm) and 0.50 mm (0–1.40 mm) for non-occluded branches ( $P = 0.131$ ) (Table 4).

#### FD patency status at F/U

The in-stent stenosis rate was 30.1% at the 6-month F/U and only 4.7% at the 24-month

F/U. Thus, none of the patients had any neurological deficits because of the in-stent stenosis (Figure 2).

Severe in-stent stenosis was seen in two stents at the 24-month DSA.

#### Complications

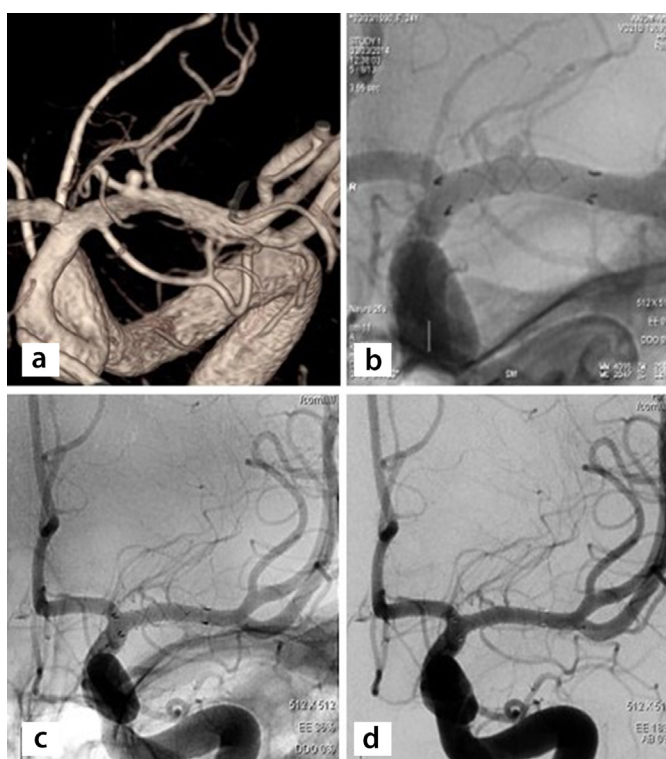
Procedural complications occurred in 10 cases. The overall procedural complication rate was 14.9%; technical failure occurred in 5 cases, thromboembolic complications occurred in 4 cases, and hemorrhagic complications occurred in 1 case. One patient treated with FRED Jr. had a permanent deficit with a Modified Rankin Scale (mRS) score of 4 (Table 5).

#### Thromboembolic complications

In one patient with a left M1 aneurysm at the frontal branch origin, a partial thrombus not obstructing the flow was formed at the proximal end of the stent immediately after deployment of FRED Jr. Furthermore, total occlusion of the aneurysm sac and a slow flow of the frontal branch was seen. Immediately 2 mg of IV bolus tirofiban was injected. Substantial resolution of the in-stent thrombus with a total recovery of the aneurysm sac and frontal branch flow was seen on the control angiography. Postoperative neurological examination was routine. Even so, IV tirofiban infusion was continued for 24 h, and dual antiplatelet therapy was changed from clopidogrel to ticagrelor + ASA. At the 24-month F/U, the aneurysm sac was still filling (OKM B2).

Another FRED Jr. patient with a left M1 aneurysm was awoken from anesthesia with left-sided central facial palsy and right hemiparesis. An immediate control angiogram of the left ICA revealed total occlusion of the aneurysm and frontal branch. A total dose of 3-mg IV bolus tirofiban was administered, and the thrombus resolved completely. The IV tirofiban infusion was continued for 48 h. The antiaggregant therapy with ASA + clopidogrel was changed to ASA + ticagrelor. The patient's mRS score was 0. Entry remnant (OKM grade C2) of the aneurysm was seen at the 36-month control angiography.

A 75-year-old female with a left M1 aneurysm on the lenticulostriate artery origin was treated with FRED. She became right hemiplegic and aphasic 2 h after she was awoken from anesthesia. The control diffusion-weighted imaging and magnetic resonance imaging showed acute ischemia in the left MCA territory. Immediate control angiography of the left ICA revealed that the left anterior temporal artery, superior trunk (jailed with FRED) of the left MCA, and the aneurysm sac were totally thrombosed. Also, partial in-stent thrombosis was evident, and 2 mg of intraarterial tirofiban was administered directly into the stent lumen. At control angiography after intra-arterial tirofiban injection, minimal residual in-stent thrombus without flow deficiency was seen. Balloon angioplasty to the stent lumen was planned, but the balloon catheter could not be advanced into the stent lumen. The IV tirofiban infusion was continued for 48 h, and the patient was discharged with aphasia and right hemiparesis. At the six-month control angiography, total occlusion of the left MCA was seen. Cortical branches of the MCA were



**Figure 1.** Twenty four-years old, female. (a) She had subarachnoid hemorrhage after rupture of a small left MCA M1 aneurysm at the origin of the lenticulostriate artery. (b) The patient is treated with a 3.5 x 17 x 11 mm FRED on the 30<sup>th</sup>-day of bleeding. (c, d) Control angiography on 2<sup>nd</sup>-months shows complete occlusion of the aneurysm and the patent lenticulostriate artery. MCA, middle cerebral artery; FRED, flow re-direction endoluminal device.

Stent	Occlusion n (%)		P
	+	-	
FRED	23 (67.6)	11 (32.4)	0.863
FRED Jr.	14 (60.9)	9 (39.1)	
PED	10 (66.7)	5 (33.3)	
<b>Location</b>			
M1	31 (64.6)	17 (35.4)	0.861
Bifurcation	16 (66.7)	8 (33.3)	

\*Pearson chi-square test, FRED (Jr.), flow re-direction endoluminal device (Jr.); PED, pipeline embolization device. One Surpass patient was excluded.

retrogradely filled via pial collaterals. The patient had an mRS score of 4 (Figure 3).

In the postoperative control Diffusion-weighted Imaging (DWI) of one patient treated with two FRED Jr.s in one session for right MCA bifurcation aneurysm (previously treated with WEB) and right A1–A2 aneu-

rysms, hyperacute infarction at the frontal lobe was detected. There was no major vessel occlusion visible in the immediate control DSA; still, both anterior cerebral artery and MCA flows were sluggish. A total dose of 2 mg IV bolus tirofiban was administered in two turns, with IV infusion for 24 h. Then,

the antiaggregant therapy was changed to ticagrelor + ASA. The patient was discharged without any neurological deficit.

The post-operative DWI of all patients was evaluated for cortical and deep infarcts. Symptomatic patients are discussed above. Among asymptomatic patients, three FRED patients (8.6%) had both cortical and deep millimetric DWI lesions. Two PED patients (10.6%) had both, and one PED patient (5.3%) had only a deep infarct. All FRED Jr. patients had DWI lesions.

#### Technical failures

Technical difficulties occurred in two PED and three FRED patients. In two PED and three FRED patients, the distal landing zone of the stents moved proximally close to the aneurysm neck; hence, a second stent was deployed in a telescopic fashion. In addition, one PED on the right MCA was shortened from the proximal landing zone, and a second stent was deployed.

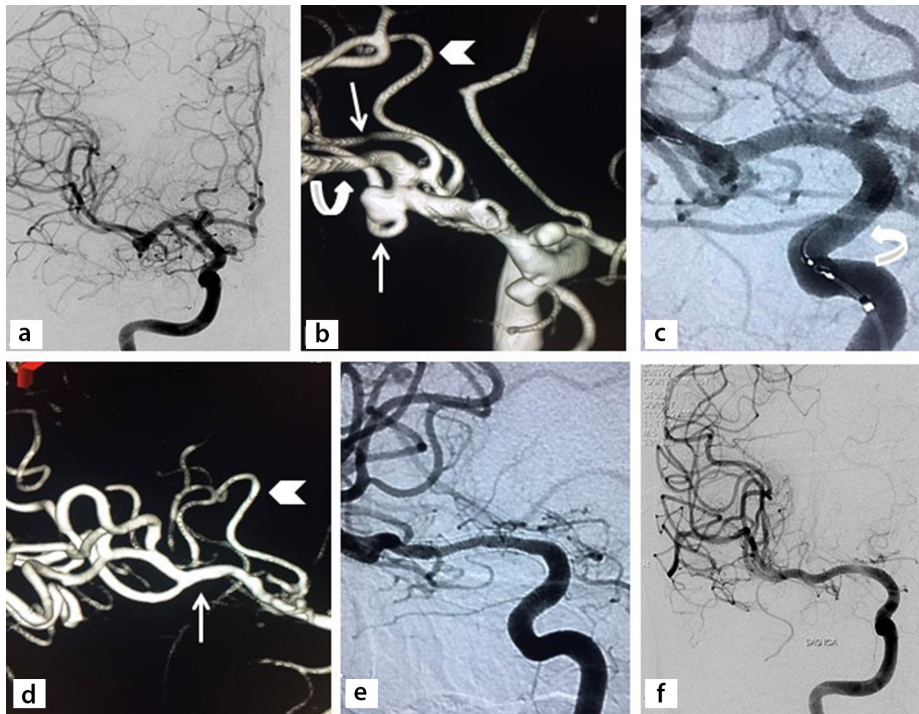
#### Hemorrhagic complications and mortality

One patient with a left frontal branch origin aneurysm (10.7 mm in diameter) who was treated with FRED developed subarachnoid hemorrhage on postoperative day four. No additional treatment was performed other than decreasing the prasugrel dosage from 10 mg to 5 mg. The patient was discharged with an mRS score of 0 after seven days of hospitalization. The first F/U DSA was at the third month; the sac was still filling and had a slightly decreased diameter. Integrated (frontal artery) and jailed (anterior temporal artery and inferior trunk) branches were patent. However, a 5.4-mm nipple was developed on the posterior side of the aneurysm sac. No further action was taken. At the six-month F/U, the sac was occluded with patent integrated and jailed branches (Figure 4).

There were no treatment-related mortalities in this study.

## Discussion

The endovascular treatment of complex MCA aneurysms is not always possible with standard techniques. Even the recurrence rates of stent-assisted coiling are not negligible.<sup>7</sup> FD stents are widely used to treat intracranial aneurysms with a complex anatomy or recurrent aneurysms despite surgical or endovascular treatments. However, the literature data on the safety and efficacy of FD stent treatment of MCA aneurysms with a

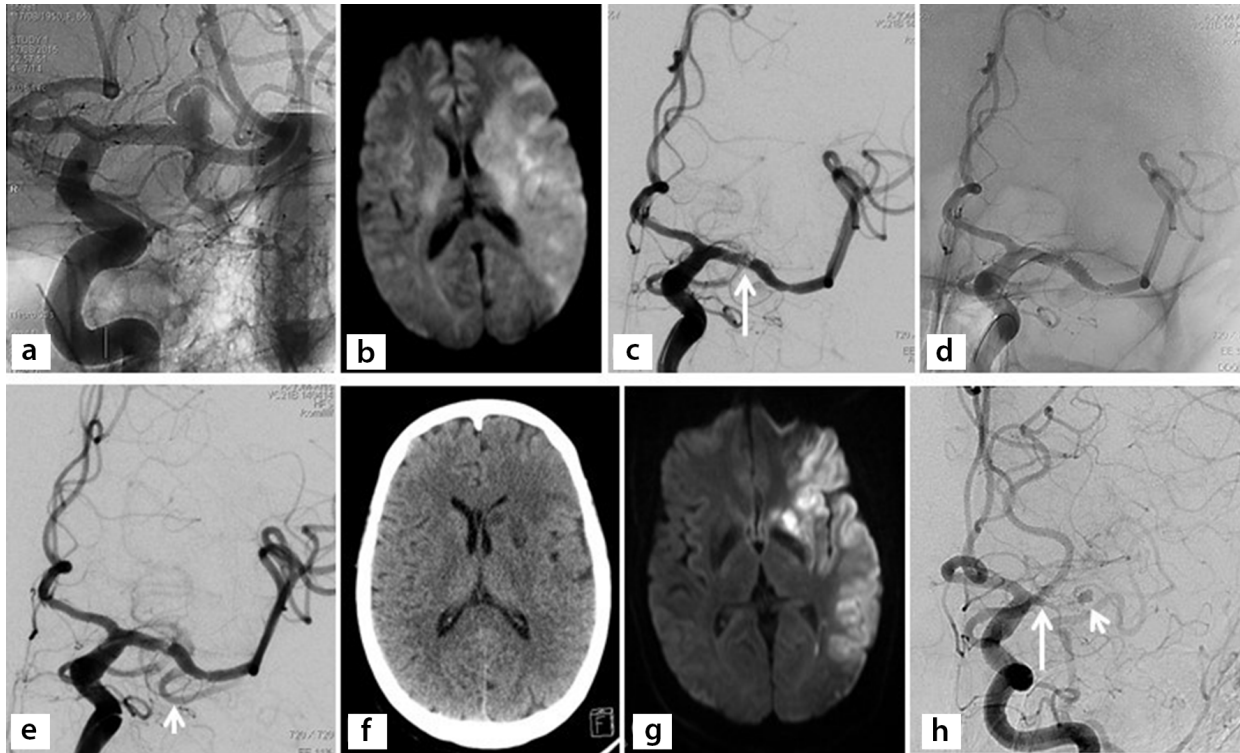


**Figure 2.** Forty five-years old female. (a) Right ICA DSA examination reveals three aneurysms; MCA bifurcation, proximal A1, anterior choroidal artery. (b, c) 3-D angiography shows the inferior trunk as the integrated branch (ascending arrow). All three aneurysms are treated with two successive pipeline stents extending between curved arrows. (d, e) Sixth-month control angiography shows the total occlusion of all aneurysms and the occlusion of the anterior temporal artery and the frontal branch (descending arrow). The patient is neurologically asymptomatic. The other frontal branch jailed by the stent is still patent (arrowhead). There is a medium degree of in-stent stenosis at the level of M1. (f) One-year control DSA examination reveals the total resolution of the stenosis. ICA, internal carotid artery; DSA, digital subtraction angiography; MCA, middle cerebral artery.

**Table 3.** Distributions of integrated and jailed branches and occlusion rates

	n (%)
Integrated branch	n = 63
Anterior temporal artery	20 (31.7)
Frontal branches	19 (30.2)
Superior truncus	8 (12.7)
Lenticulostriate artery	8 (12.7)
Others	8 (12.7)
6. month occlusion	4 (6.6)
The last control occlusion	6 (10)
Jailed branch	n = 12
Anterior temporal artery	5 (41.7)
Superior truncus	2 (16.7)
Inferior truncus	2 (16.7)
Others	3 (25)
Jailed branch occlusion*	1 (8.3)

\*Both six-month and the last F/U; F/U, follow-up.



**Figure 3.** Seventy-five-year old, female. (a) Left M1 frontal branch origin aneurysm is treated with FRED. The stent is seen as entirely normal. (b) Two hours after anesthesia, the patient develops aphasia and right hemiparesis. DWI reveals acute ischemic stroke in MCA territory. (c, d) Immediate angiography shows the occlusion of both the frontal branch and the anterior temporal artery, and the aneurysm. There is also a partial thrombus within the stent lumen (long arrow). Also, note the dysmorphic changes -the fish mouth- in the stent. (e) 2 mg of IA tirofiban only enables the slow perfusion of the anterior temporal artery (short arrow). (f, g) Next day CT and DWI show no bleeding, but the acute ischemic changes despite the IV tirofiban infusion. (h) 6<sup>th</sup>-month follow-up DSA shows the total occlusion of the stent (long arrow). The aneurysm is still filling through collaterals to the lenticulostriate arteries (short arrow). FRED, flow re-direction endoluminal device; DW, diffusion-weighted imaging; MCA, middle cerebral artery; CT, computed tomography; DSA, digital subtraction angiography.

**Table 4.** Effect of oversizing the stent on the aneurysm occlusion and integrated branch patency

Aneurysm	Oversizing (mm) Median (minimum–maximum)	<i>P</i>
Occluded	0.45 (0–1.30)	0.323
Non-occluded	0.50 (0–1.40)	
<b>Integrated branch</b>		
Occluded	0.70 (0.45–1.10)	0.131
Non-occluded	0.50 (0–1.40)	

Mann–Whitney U test.

wide neck, complex anatomy, and integrated branches still seems to be limited.

This study investigated the safety and efficacy of FD stents in treating complex MCA aneurysms and compared the treatment success of PED, FRED, and FRED Jr. The median size of the aneurysms enrolled in this study was 4.45 mm (1.1–12 mm). Of the 76 aneurysms included in the study, 71 were small in size (<10 mm). The treatment indications regarding small intracranial aneurysms have not been clearly defined yet. The general opinion is that the treatment decision should not be based on a single parameter. Although the annual rupture rate of small

intracranial aneurysms is relatively low, morbidity and mortality rates are high in cases of rupture.<sup>8–10</sup> Moreover, small MCA aneurysms have a considerable risk of rupture even if they are smaller than 10 mm. Most of the treated aneurysms in this study either had wide necks or integrated branches. These two characteristics were the main parameters for using FD stents in the treatment.

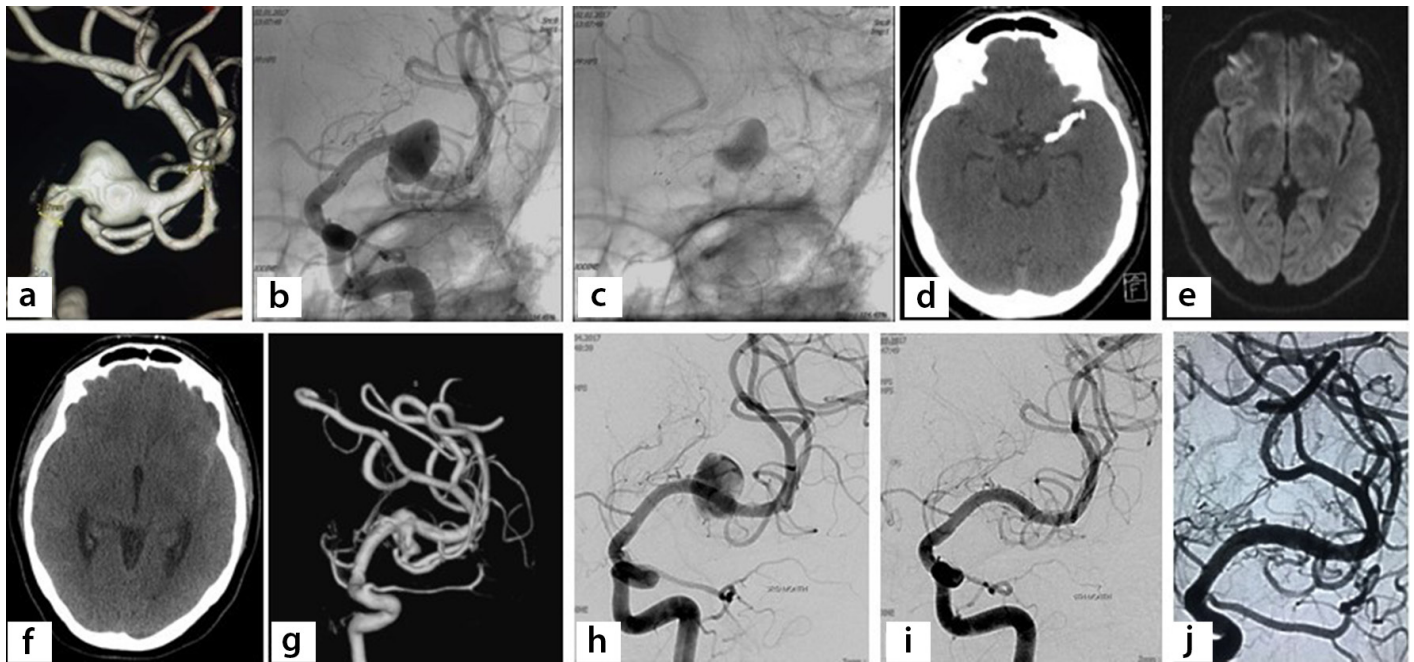
The mean F/U period in this study was 32.1 months. Thus, 86% of the aneurysms had a DSA F/U time of  $\geq 12$  months, and 62% had a DSA F/U time of  $\geq 24$  months.

The total or adequate occlusion (OKM D or C3) rates were 43.8%, 63.5%, 73.3%,

85.7%, and 87.5% for the 6-, 12-, 24-, 36-, and 60-month F/Us, respectively. Excluding an aneurysm from circulation through flow diversion is time-dependent, as mentioned in many studies.<sup>11</sup> Therefore, higher occlusion rates are expected with longer F/U period. A systematic review including 12 studies regarding the treatment of 244 MCA aneurysms with FD stents showed a complete/near-complete occlusion rate of 78.7%, with a mean F/U period of 12 months.<sup>12</sup>

Yavuz et al.<sup>13</sup> reported FD treatment results of 25 aneurysms located at MCA bifurcation and beyond. The study revealed total occlusion rates of 76% and 90% on the 6-month and the last F/U, respectively. In a PED study including 10 complex MCA aneurysms, with a mean F/U period of 7.5 months, a total occlusion rate of 77% was found.<sup>14</sup> Bhogal et al.<sup>9</sup> reported FD treatment results of 15 M1 aneurysms with a median F/U time of 18.7 months. The total occlusion rate was 73%.

In the present study, the 12-month occlusion rate (63.5%) was lower than the occlusion rates in the above-mentioned studies; however, the 24- and 36-month occlusion



**Figure 4.** Forty one-years old female. (a, b) Left fusiform MCA aneurysm treated with FRED. The temporal branch is directly coming out of from sac. (c) The control angiography after the stent deployment shows prominent stagnation within the sac. (d, e) Control CT and DWI images are unremarkable. (f) The patient has a sudden onset of a severe headache on the 4<sup>th</sup>-day. CT examination reveals subarachnoid hemorrhage. (g) 3-D angiography shows partial thrombosis of the sac with irregular contours. The integrated branch is still patent. (h) Residual, but the slow filling of the sac is seen on 3-month control angiography. (i, j) Six and 12<sup>th</sup>-month follow-ups. No residual filling of the aneurysm. The MCA and the integrated branch are patent. MCA, middle cerebral artery; FRED, flow re-direction endoluminal device; DWI, diffusion-weighted imaging; CT, computed tomography

Table 5. Adverse events	
Procedural complications	n = 67 (%)
Technical	10 (14.9)
Thromboembolic	5 (7.5)
Hemorrhagic	4 (5.9)
In-stent stenosis*	1 (1.5)
	n = 76
6 Month	22/8 (30.1)
12 Month	10/4 (15.9)
24 Month	2/0 (4.7)
Last control	8/2 (11)
Morbidity	1
Mortality	0

\*(Sum/symptomatic).

rates (73.3% and 85.7%, respectively) are consistent with the literature. In the EuFRED study, the subgroup analysis showed that the total occlusion rate of intracranial bifurcation aneurysms was 61.5% at 180 days; this is similar to the results of the present study.<sup>3</sup> The majority of aneurysms in the above studies were located in MCA bifurcation or beyond it. In the present study, 68.4% of aneurysms were located at the M1 segment of MCA, and the occlusion rates for sidewall and bifurcation aneurysms were 64.6% and 66.7%, respectively.

FD treatment of bifurcation and sidewall aneurysms should be evaluated separately because of their hemodynamic differences. A recent meta-analysis investigating FD treatment of sidewall and bifurcation aneurysms reported comparable occlusion rates (69.4% and 73.9% respectively).<sup>15</sup> Another recent study investigating FD treatment of proximal MCA aneurysms reported occlusion rates for sidewall and bifurcation aneurysms (75% and 63% respectively).<sup>16</sup> Both of these studies show that the hemodynamic difference may not alter the occlusion rates to the expected extent. The present study also reveals comparable results.

Integrated branches or perforators mostly accompany the M1 segment aneurysms.

In this study, 82% of the aneurysms were accompanied by an integrated branch. It is the authors' opinion that this is the main reason for the lower first control occlusion rates. Also, the patency of the integrated branch is one of the major concerns regarding FD treatment. The oversizing of the FD to avoid technical failure may delay the occlusion of the aneurysm while contributing to the patency of the integrated branches.

Topcuoglu et al.<sup>17</sup> reported corroborative data showing that 11/17 MCA aneurysms with integrated branches remained open; only 2 of these aneurysms with patent in-

tegrated branches were occluded at the F/U. Based on this argument, the Cekirge and Saatci<sup>18</sup> occlusion grading system might be more practical while assessing the F/U occlusion grade of an aneurysm with integrated branches. The OKM grade C1 and C2 aneurysms were classified as class 5 "stable remodeling" according to the Cekirge and Saatci<sup>18</sup> occlusion grading system at the second control DSA. The effect of oversizing on the aneurysm and integrated branch occlusion was analyzed, and there was no significant difference between occluded/non-occluded aneurysms and integrated branches.

There was no statistically significant difference between the last F/U occlusion rates in the FRED, FRED Jr., and PED patients.

A total of 63 integrated branches were covered in 76 aneurysm treatments; 3 of them were lost to the F/U. The 6-month F/U and last F/U occlusion rates were 6.6% and 10%, respectively. None of the occluded integrated branches were symptomatic. Two studies investigating integrated branch patency after FD treatment of MCA aneurysms and a meta-analysis including 174 MCA branches covered with FD stents reported integrated branch occlusion rates of 10.5%, 20%, and 10.1%, respectively, at the last F/U visit.<sup>12,19,20</sup>

A total of 12 MCA branches were jailed by an FD in the study group. The most common one was the anterior temporal artery. At the six-month F/U, one jailed branch was occluded without any neurological deficit. Any of the other 11 jailed branches were occluded at the 12- or 24-month controls.

In this study group, the overall complication rate was 14.9% (10/67), with one hemorrhagic complication, four thromboembolic complications, and five technical failures. A single-center study regarding FD treatment of MCA bifurcation aneurysms reported a thromboembolic complication rate of 15.3%.<sup>9</sup> Another single-center study emphasized a covered branch status after FD treatment of distal bifurcation aneurysms, with a thromboembolic event rate of 17.6%.<sup>19</sup> Finally, Cagnazzo et al.<sup>12</sup> reported a general complication rate of 20.7% and a thromboembolic event rate of 16.3% in their meta-analysis on FD stent treatment of MCA aneurysms.

The present study's overall and thromboembolic complication rates were 14.9% and 7.5%, respectively; this is consistent with the literature. Even though the data is not statistically significant, FRED Jr. was used in three out of four thromboembolic complications; the other stent used was FRED.

An *in vitro* study suggests that FRED had higher thrombin generation and platelet activation than PED.<sup>21</sup> Both FRED Jr. and FRED are dual-layer stents with a higher metal load than PED. Therefore, this type-two error would probably not occur in series with a more significant number of cases. Interestingly, the lower profile FRED Jr. caused more thromboembolic events than FRED. Therefore, it is critical to test all the patients for clopidogrel and prasugrel resistance, and antiaggregation should be conducted as suggested for each drug.

There are several limitations to this study. First, it is a retrospective study with a relatively small study population to compare the safety and efficacy of different FD stents in treating MCA aneurysms. The low number of bifurcation aneurysms is another limitation. This study reflects a single-center and single-operator experience with FRED, FRED Jr., and PED in flow diversion of MCA aneurysms. Since learning curves tend to differ among operators, the comparison of outcomes of devices may not always apply to all potential interventionalists. Even so, a long F/U period and detailed definitions and solutions to complications may have an impact on the literature.

In conclusion, MCA aneurysms tend to be complex, with integrated branches and potentially wide necks. FD stents are safe and effective in the treatment of MCA aneurysms. The patency of the side and jailed branches is preserved in most cases. Higher occlusion and lower in-stent stenosis rates are seen with longer F/U durations. Oversizing the stent was not found to be a contributor to occlusion of the aneurysm or integrated branch.

### Conflict of interest disclosure

The authors declared no conflicts of interest.

### References

1. Zaidat OO, Castonguay AC, Tebeb MS, et al. Middle cerebral artery aneurysm endovascular and surgical therapies: Comprehensive literature review and local experience. *Neurosurg Clin N Am*. 2014;25(3):455-469. [\[CrossRef\]](#)
2. Alderazi YJ, Shastri D, Kass-Hout T, Prestigiacomo CJ, Gandhi CD. Flow diverters for intracranial aneurysms. *Stroke Res Treat*. 2014;2014:415653. [\[CrossRef\]](#)
3. Killer-Oberpflazer M, Kocer N, Griessenauer CJ, et al. European multicenter study for the evaluation of a dual-layer flow-diverting stent for treatment of wide-neck intracranial aneurysms: the european flow-redirection intraluminal device study. *AJNR Am J Neuroradiol*. 2018;39(5):841-847. [\[CrossRef\]](#)
4. Al Kasab S, Guerrero WR, Nakagawa D, Samaniego EA, Ortega-Gutierrez S, Hasan D. Safety and efficacy of the pipeline embolization device use in the outside circle of willis located intracranial aneurysms: a single-center experience. *Interv Neurol*. 2020;8(2-6):83-91. [\[CrossRef\]](#)
5. Fiorella D, Gache L, Frame D, Arthur AS. How safe and effective are flow diverters for the treatment of unruptured small/medium intracranial aneurysms of the internal carotid artery? Meta-analysis for evidence-based performance goals. *J Neurointerv Surg*. 2020;12(9):869-873. [\[CrossRef\]](#)
6. O'Kelly CJ, Krings T, Fiorella D, Marotta TR. A novel grading scale for the angiographic assessment of intracranial aneurysms treated using flow diverting stents. *Interv Neuroradiol*. 2010;16(2):133-137. [\[CrossRef\]](#)
7. Pierot L, Cognard C, Spelle L, Moret J. Safety and efficacy of balloon remodeling technique during endovascular treatment of intracranial aneurysms: Critical review of the literature. *AJNR Am J Neuroradiol*. 2012;33(1):12-15. [\[CrossRef\]](#)
8. Briganti F, Leone G, Marseglia M, et al. Endovascular treatment of cerebral aneurysms using flow-diverter devices: A systematic review. *Neuroradiol J*. 2015;28(4):365-375. [\[CrossRef\]](#)

9. Bhogal P, AlMatter M, Bäßner H, Ganslandt O, Henkes H, Pérez MA. Flow diversion for the treatment of MCA bifurcation aneurysms-A single centre experience. *Front Neurol*. 2017;8:20. [\[CrossRef\]](#)
10. Elsharkawy A, Lehečka M, Niemelä M, et al. Anatomic risk factors for middle cerebral artery aneurysm rupture: computed tomography angiography study of 1009 consecutive patients. *Neurosurgery*. 2013;73(5):825-837. [\[CrossRef\]](#)
11. Ye G, Zhang M, Deng L, Chen X, Wang Y. Meta-analysis of the efficiency and prognosis of intracranial aneurysm treated with flow diverter devices. *J Mol Neurosci*. 2016;59(1):158-167. [\[CrossRef\]](#)
12. Cagnazzo F, Mantilla D, Lefevre PH, Dargazanli C, Gascou G, Costalat V. Treatment of middle cerebral artery aneurysms with flow-diverter stents: a systematic review and meta-analysis. *AJNR Am J Neuroradiol*. 2017;38(12):2289-2294. [\[CrossRef\]](#)
13. Yavuz K, Geyik S, Saatci I, Cekirge HS. Endovascular treatment of middle cerebral artery aneurysms with flow modification with the use of the pipeline embolization device. *AJNR Am J Neuroradiol*. 2014;35(3):529-535.
14. Zanaty M, Chalouhi N, Tjoumakaris SI, Gonzalez LF, Rosenwasser R, Jabbour P. Flow diversion for complex middle cerebral artery aneurysms. *Neuroradiology*. 2014;56(5):381-387. [\[CrossRef\]](#)
15. Abbasi M, Savasatano LE, Brinjikji W, et al. Endoluminal flow diverters in the treatment of sidewall and bifurcation aneurysm: A systematic review and meta-analysis of complications and angiographic outcomes. *Interv Neuroradiol*. 2022;28(2):229-239. [\[CrossRef\]](#)
16. Lauzier DC, Root BK, Kayan Y, et al. Pipeline embolization of proximal middle cerebral artery aneurysms: A multicenter cohort study. *Interv Neuroradiol*. 2022;28(1):50-77. [\[CrossRef\]](#)
17. Topcuoglu OM, Akgul E, Daglioglu E, et al. Flow diversion in middle cerebral artery aneurysms: is it really an all-purpose treatment? *World Neurosurg*. 2016;87:317-327. [\[CrossRef\]](#)
18. Cekirge HS, Saatci I. A new aneurysm occlusion classification after the impact of flow modification. *AJNR Am J Neuroradiol*. 2016;37(1):19-24. [\[CrossRef\]](#)
19. Gawlitza M, Januel AC, Tall P, Bonneville F, Cognard C. Flow diversion treatment of complex bifurcation aneurysms beyond the circle of Willis: a single-center series with special emphasis on covered cortical branches and perforating arteries. *J Neurointerv Surg*. 2016;8(5):481-487. [\[CrossRef\]](#)
20. Michelozzi C, Darcourt J, Guenego A, et al. Flow diversion treatment of complex bifurcation aneurysms beyond the circle of Willis: complications, aneurysm sac occlusion, reabsorption, recurrence, and jailed branch



modification at follow-up. *J Neurosurg.* 2019;131(6):1751-1762. [\[CrossRef\]](#)

21. Girdhar G, Andersen A, Pangerl E, et al. Thrombogenicity assessment of Pipeline Flex, Pipeline Shield, and FRED flow diverters

in an in vitro human blood physiological flow loop model. *J Biomed Mater Res A.* 2018;106(12):3195-3202. [\[CrossRef\]](#)