

RIGHT-SIDED HEMI-HYPOTROPHY RESULTING  
FROM RIGHT-SIDED CONGENITAL SPASTIC  
HEMIPLEGIA, WITH A MORBID CONDITION OF  
THE LEFT SIDE OF THE BRAIN, REVEALED  
BY RADIOGRAMS.

BY F. PARKES WEBER, LONDON.

THOUGH in adult, fully-developed persons, hemiplegia of cerebral origin does not lead to marked wasting of the paralyzed parts, it is well known that congenital spastic hemiplegia leads to imperfect growth of the limbs on the paralyzed side, so that a condition of hemi-hypotrophy results. This is what happened in the present patient, but the chief interest of the case is connected with the *x*-ray examination of the brain.

**On Examination.**—The patient, R. R., is a woman, age 22 years, with right-sided congenital spastic hemiplegia, sexual infantilism, and a very widespread vascular nævus, chiefly of the superficial ‘port-wine-stain’ type (*Fig. 1*). On the back of the trunk this port-wine angioma is almost entirely limited by the median line to the left side (*Fig. 2*); in front the distribution, though very irregular (*Fig. 1*), is more extensive on the left than on the right side. In parts, notably in the left cheek, there is, besides the ‘port-wine-staining’, also a condition of more deeply-seated venous nævus (cavernous angioma). The right limbs are shorter than the left limbs (*see later*). The patient is rather obese and bulky, and in sexual development she is infantile. There is absence of pubic and axillary hair, and she has never menstruated. The mammary regions are bulky, doubtless owing to fat (part of her general obesity). The left eyeball is larger than the right (buphthalmus), owing to congenital glaucoma. Dr. C. Markus, who kindly sent the patient to me, reports that the right eye is normal, but that there is atrophy and glaucomatous excavation of the left optic disc. She is blind in the left eye. The iris of the right eye is grey-blue; the inferior quarter sector of the left iris is similar, but the upper three-quarters sector is brown. In other words, there is a brownish pigment-nævus of the upper part of the left iris, giving rise to a condition of so-called ‘heterochromia iridis’.

*Röntgen-ray Examination of the Head.*—Two skiagrams were taken, so as to obtain a side view, the films being placed on the left side; one of these skiagrams is shown in *Fig. 3*. Another skiagram (*Fig. 4*) gave us an antero-posterior view, the film being placed in front of the face. I have to thank Dr. James Metcalfe for his advice in regard to the taking of the skiagrams and his examination of them. The skull is markedly prognathous—of the ‘simian’ type. The frontal sinuses are very large. The sella turcica is extremely small

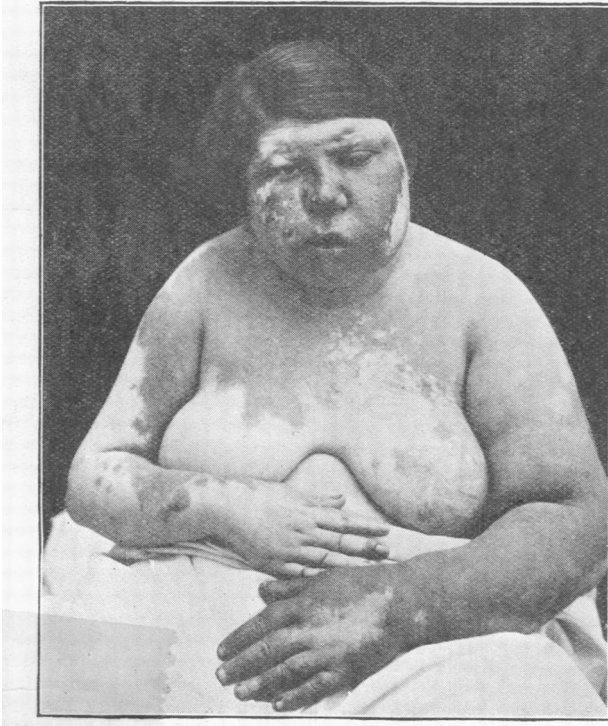

FIG. 1.—Photograph of patient, May, 1922.

—infantile—a feature which should be specially noted in connection with the sexual infantilism and the obesity (*see above*). The left half of the brain appears sclerosed; at all events, it is more opaque and gives a somewhat deeper shadow than the right half of the brain. It seems to occupy only about two-thirds of the left half of the cranial cavity, and to be surrounded by cerebrospinal fluid (external hydrocephalus).

*Physical Development.*—The patient's body-weight (May 13, 1922) is  $70\frac{3}{4}$  kilo. (11 st.  $2\frac{1}{4}$  lb.); her height is 148 cm. (4 ft.  $10\frac{1}{4}$  in.).

From the acromion to the tip of the middle finger her right upper extremity measures 58 cm., whereas her left upper extremity measures  $67\frac{1}{3}$  cm. From the anterior superior iliac spine to the malleolus externus her right lower extremity measures 80 cm., whereas her left lower extremity measures 84 cm. I am indebted to Dr. Scheu for these measurements.

*Rectal Examination* (Dr. Scheu).—By digital rectal examination the vagina seems long, and one can just reach the cervix uteri;

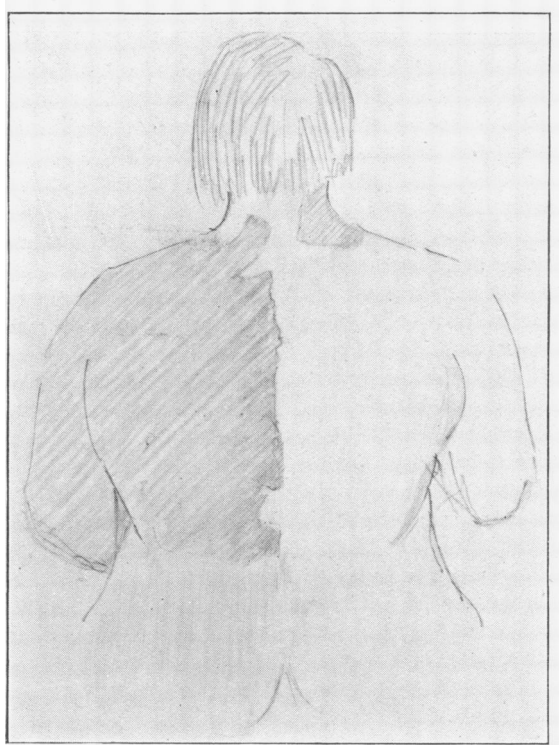


FIG. 2.—From a diagrammatic sketch of the naevus distribution from the back (Dr. Scheu).

probably the uterus is more abdominal than it normally should be, and probably the sexual organs are infantile.

*Mental and Nervous Conditions.*—The patient can speak and understand ordinary things; that is to say, she is fairly intelligent in ordinary conversation; but she has never been to school. On account of the great paresis in her right upper extremity she can only do a little house-work. There is much less paresis in the right lower extremity. The knee-jerks are very active on both sides. The plantar reflex on the left side is of the normal flexor type; that on the right side is of the extensor type (Babinski's sign).

Whilst the patient was under observation in the hospital there were no convulsions—nor was there apparently a history of any kind of fits. There was no fever. Her pulse was 68 to 88, and her respiration 24. Her brachial systolic blood-pressure was 115 mm. Hg. Her blood serum gave a completely negative Wassermann reaction. The blood-count showed a slight excess of white corpuscles. She passed about 1000 c.c. of urine in the twenty-four hours (according to the chart; but perhaps some was passed with the fæces and not charted). The urine, when tested, was of specific gravity 1025; acid; free from sugar; but containing a trace of albumin, probably due to the presence of some discharge from the vagina. No alimentary glycosuria followed the ingestion of 100 gm. of dextrose (which was

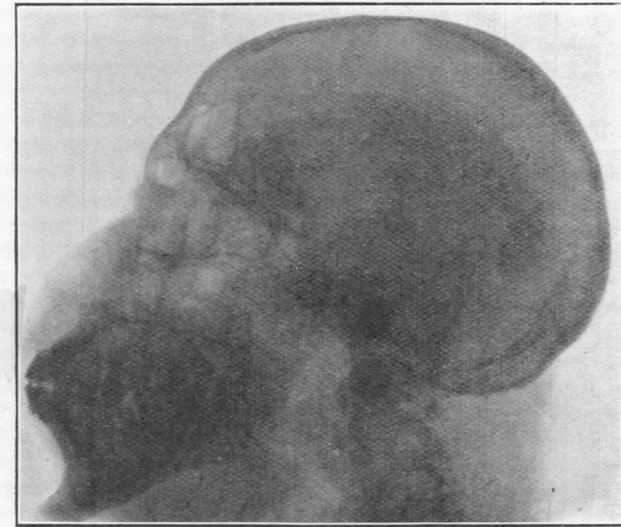


FIG. 3.—Skiagram of the head, lateral view, the film having been placed on the left side.

taken in lemonade); but a trace of sugar was noted in the urine after she was given 200 gm. of dextrose.

In regard to the examination of the patient herself there is nothing further special to note. She is of a Hebrew family. Her mother is an active-looking, well-developed woman, who has a moderate degree of xanthelasma palpebrarum. A sister of the patient is said to have become insane during the war, "after air-raids". Besides these, the mother says she has two healthy children; none have died or were born dead; she has had two or three miscarriages.

**Remarks.**—The case is one of right-sided congenital spastic hemiplegia and right-sided hemi-hypotrophy, due to a lesion on the

left side of the brain, which is partially revealed by  $x$ -ray examination. As far as I know, this is the only hitherto published case in which a lesion of the kind has been demonstrated during life by ordinary  $x$ -ray skiagrams (without the letting out of cerebrospinal fluid, and its replacement by sterilized air or oxygen). This has been possible partly owing to the cranial bones being rather thin, and partly owing to a shrunken condition and abnormal consistence of the brain on the left side and the presence of external hydrocephalus on that side. The abnormal consistence of the left cerebral

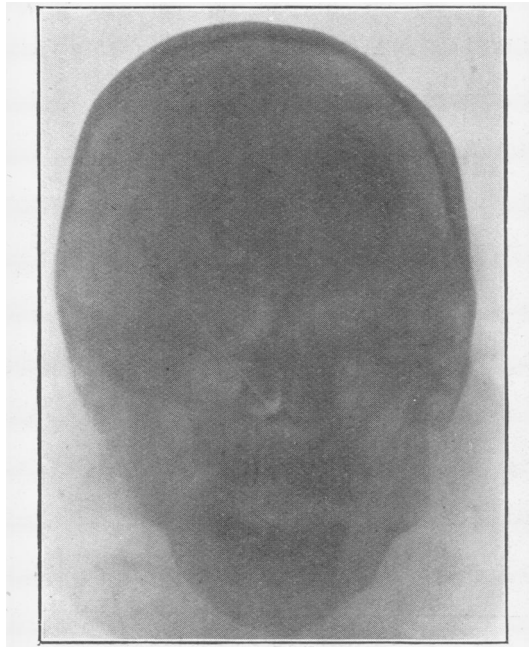


FIG. 4.—Skiagram of the head, antero-posterior view, the film having been placed in front of the face.

hemisphere is doubtless due to sclerotic changes or meningeal abnormalities. It is highly probable that the congenital cerebral disease is in some way connected with the presence of a vascular nævus of the meninges or brain on the left side—of the same nature as the extensive vascular nævus of the patient's body.

D. M. Greig<sup>1</sup> has recently published the case of a boy, age 18, in whom right hemiplegia and right-sided convulsions were caused by a meningeal vascular nævus of the opposite side of the brain. The boy likewise presented the condition of adenoma sebaceum of the face—a condition now admitted by dermatologists to be a form of

cutaneous nævus. H. Campbell and Sir Charles Ballance<sup>2</sup> have published the case of a man, age 23, in whom mild left hemiplegia and occasional left-sided convulsions were due to venous angioma of the cerebral cortex of the opposite side.

In the present case the buphthalmus, due to congenital glaucoma, is probably likewise in some way connected with the nævus condition. One may even think of the possibility that a vascular nævus gave rise, at or before birth, to subarachnoid hæmorrhage on the left side, and that an intra-ocular hæmorrhage was the cause of the congenital glaucoma in the left eye.

The sexual infantilism and obesity are perhaps due to the infantile size of the pituitary fossa, as revealed by *x*-ray examination. But it is impossible to decide whether the hypoplasia of the pituitary gland is or is not in any way causally connected with the congenital disease on the left side of the brain; it is possible that both may be due to meningeal or intracranial vascular nævus-formation.

---

#### REFERENCES.

- <sup>1</sup> GREIG, D. M., "Case of Meningeal Nævus, associated with Adenoma Sebaceum", *Edin. Med. Jour.*, 1922, N.S., xxviii, 105.
- <sup>2</sup> CAMPBELL, H., and BALLANCE, SIR C., "A Case of Venous Angioma of the Cerebra Cortex", *Lancet*, 1922, i, 10.