

CASE REPORT

Frailty and mini dental implants

Dennis Flanagan 

Department of Dental Medicine,
Lugano University of Switzerland,
Lugano, Switzerland

Correspondence

Dennis Flanagan, Department of
Dental Medicine, Lugano University of
Switzerland, Lugano, Switzerland.
Email: dffdds@comcast.net

Abstract

Patients who have been diagnosed as frail and have atrophic jaws may have a dramatic increase of quality of life with mini implant treatment for retention of a mandibular complete denture.

KEYWORDS

atrophic, loading, mini dental implant, occlusion, quality of life, sarcopenia

1 | INTRODUCTION

Many dental implant patients are older and can have atrophic, edentulous, bimaxillary jaws. Along with edentulism many are aged and may be frail. Frailty is typically diagnosed (ICD10 Code: R54) when three of the following five criteria are met: low [physical activity](#), weak grip strength, low energy, slow walking speed, and unintentional weight loss.¹

There can be ancillary diagnoses. Sarcopenia (ICD10-M62.84) is a loss of skeletal muscle that is primarily associated with elderly patients with comorbidities. Frailty and sarcopenia are closely related, but frailty may include cognitive and social issues.¹⁻³

The baby boomer generation is aging, and with that, many of these people will become frail. Many will also be partially or completely edentulous with atrophic jaws. This makes adequate retention and function of dental prostheses unlikely. A denture adhesive may not be adequate for good denture stability and function, especially in the mandible. Minimally invasive mini dental implants may provide adequate to excellent retention of a complete denture for better nutrition and quality of life.

Mini-implants used to retain an overdenture may provide adequate function for the frail patient. Because these patients are frail and can be bimaxillary atrophic, a minimally invasive treatment may be appropriate. Minimally invasive treatment can be instituted to minimize physiologic stress and costs.

2 | CASE REPORT

A 77-year-old male presented for treatment with the chief complaint, "I can't eat with these dentures." Visual and panoramic radiographic examinations revealed bimaxillary edentulism with atrophy and an unstable mandibular complete denture. This polypharmacy patient had been diagnosed as frail and was not able to physically tolerate an extensive surgical or prosthetic procedure. The fit and flat zero-degree occlusal scheme of the existing dentures were adequate. The lower denture was well-fitting, but the residual ridge was inadequate for appropriate retention. The maxillary complete denture did not have excellent retention on the atrophic ridge. The patient's primary care physician was contacted, the procedure was explained, and medical clearance was obtained. Treatment options and a definitive treatment plan were discussed with the patient, and informed consent was obtained.

After local facial and lingual infiltration with 1.6 cc articaine (Septocaine), four mini-implants (IntraLock 2.5×13 mm) were surgically placed in the anterior mandible in type 1 bone density. Proprietary drills and instrumentation were used in accordance with the manufacturer's instructions. The implants were immediately loaded with the retainers embedded by pick-up in the existing complete mandibular denture ([Figures 1 and 2](#)). The attached tissue was adequate for the mini-implants, and no soft tissue flap was raised. The lower denture

This is an open access article under the terms of the [Creative Commons Attribution-NonCommercial-NoDerivs](#) License, which permits use and distribution in any medium, provided the original work is properly cited, the use is non-commercial and no modifications or adaptations are made.

© 2023 The Authors. *Clinical Case Reports* published by John Wiley & Sons Ltd.

immediately had much better retention, which impaired much better function. The maxillary complete denture increased in retention due to the stability of the mandibular denture. The patient functioned uneventfully and was followed for 8 years upon his death. The improved oral function may have prolonged this patient's life.

3 | THE DIAGNOSIS OF FRAILITY

Many elderly patients are diagnosed as frail. This means that these people may be seriously harmed by extensive oral surgery. A fatality may even occur. There are several sets of criteria for a diagnosis of frailty.¹⁻³

Frailty may be defined as an aging-related syndrome of physiological deterioration.^{2,3} This causes the patient to be vulnerable to a variety of old-age disorders and diseases. Symptoms present as weakness and fatigue, complex medical issues, and relative intolerance to medical interventions. There is no standard definition of the diagnosis of frailty. There are frailty screening tests for assessing health risk assessment and epidemiology.

One single parameter for the diagnosis of frailty is the TUG test, which measures the time it takes for a patient to get up from a chair, walk 10 feet (3 m), turn around, and then return to being seated again.⁴⁻⁶ Ten seconds or less is "normal." Fourteen seconds or greater indicates a high risk of falling.

A set of other parameters are: unintentional weight loss of more than 10 lbs., weak hand grip strength, self-reported exhaustion, walking speed slower than 0.8 m/s, and low physical activity.² If a patient has none of these criteria, then there is no frailty. If one or two of these are met, then there is intermediate frailty. A diagnosis

of frailty is met when three or more of these criteria are met.²

Another set of parameters are: self-reported fatigue, inability to climb one flight of stairs, inability to walk one city block, having more than five illnesses, and more than 5% unintentional weight loss.^{5,6} Again, if 1–2 criteria are met, then there is intermediate frailty, and if three or more are met, then there is a diagnosis of frailty.^{5,6} Women with cirrhosis have a higher frailty rate than men with similar disease severity.^{7,8} There are other criteria to be used to diagnose frailty, but there is no agreed-upon standard.

4 | DISCUSSION

Frailty is associated with African American heritage, low education, low income, poorer general health, and comorbid chronic conditions.^{2,3} The frailty phenotype is predictive of the incidence of falls, decreasing mobility, disability, hospitalization, and death.

Patients can be frail at any age depending on their physical condition as a result of age, disease, or disability. Many of these patients cannot financially afford extensive treatment. Nonetheless, they are still in need of nutrition and a decent quality of life for appearance and speech. Mini-implants are generally relatively inexpensive and easy to place at appropriate sites.⁹ Bone density is important. Type 1 and 2 densities are appropriate, but any less dense site may not provide adequate resistance for immediate occlusal loading.⁹ Load resistance immediately depends on the mechanical resistance in dense bone until osseointegration occurs.⁹ Mini-implants for this purpose have a processed, rough surface that is intended to osseointegrate.⁹

The osseous site-dimensional requirements for mini-implants are similar to the requirements for standardized dental implants, except that the bone width can be much smaller. The decreased osseous width is associated with more dense bone.^{9,10}

Atrophic bone in the maxilla may not be dense enough to resist occlusal loading. However, there can be very dense osseous islands that can provide appropriate implant support. Thus, it is incumbent on the clinician to evaluate preoperatively the quality of the maxillary bone. Hounsfield units (HU) on cone beam computerized tomographs can give an indication of bone density, but HU is not completely reliable.¹⁰ HU does provide an approximation of bone density. Intraoperative sensibility by the operator is the ultimate test for bone density. Nonetheless, density is not uniform in bone. Thus, one not-so-dense site may be just a millimeter or two away from a very dense osseous site.¹⁰ This means that if an implant is placed at a less dense site, the surgeon may

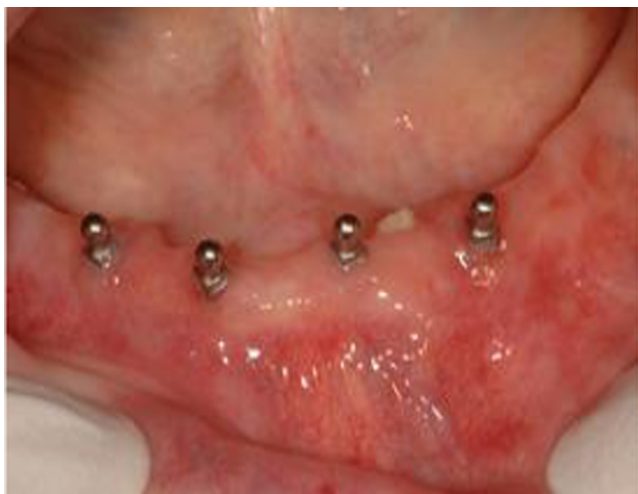

FIGURE 1 The patient presented with an atrophic edentulous ridge that was treated with 2.5-mm-diameter mini-implants and immediately loaded.

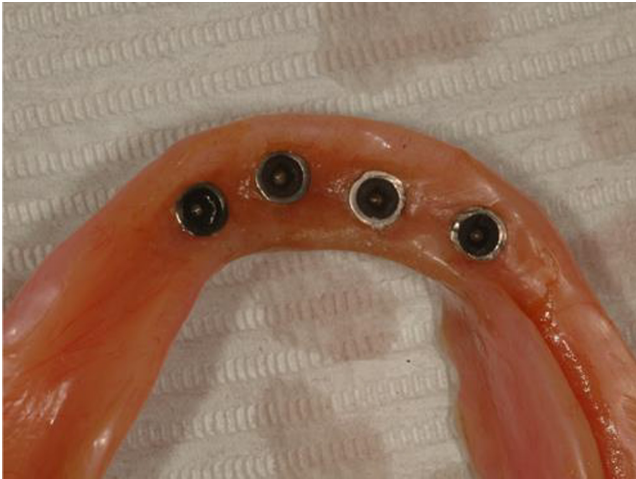

FIGURE 2 The patient was treated with small-diameter, mini-implants to retain the mandibular complete denture.

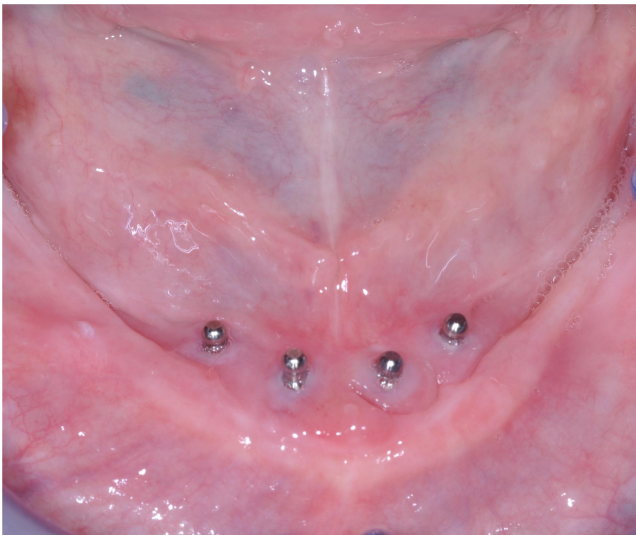


FIGURE 3 Immobile mucosa is adequate for epithelial attachment protection.

elect to relocate the osteotomy 1–2 mm away and find that bone to be very dense.

Bite force capacity may be an important preoperative parameter. A patient with a high bite force capacity may overload the retaining mini-implants. Since these patients are frail, the biting force they generate can be as low as 30 newtons.¹¹ Such a low biting load would not cause a luxation of a properly placed mini-implant.¹¹

Mini-implants that retain a denture should be as long as anatomically possible to prevent overload.⁹ A preoperative cone beam computerized tomogram is appropriate to identify anatomical landmarks to be avoided. Atrophic bone may be thin and needs to be measured so the risk of perforation is minimized.⁹ Even though length does not add as much resistance to loading as width, every bit of

osseous contact is required for a long-term successful outcome.⁹ The long length may contribute enough resistance to tolerate a happenstantial increased load, such as caused by a fall or biting on a seed.

There needs to be adequate attached tissue or soft tissue that is immovable or that may be augmented with a tunnel dermal allograft or porcine collagen xenograft.¹² A donor site-type free gingival or submucosal graft may not be tolerable for the frail patient.¹² Additionally, immovable mucosa may suffice for protection for the epithelial attachment around the implant, be it a mini or standard size (Figure 3). The key factor is the prevention of muscle tension on the epithelial attachment.^{9,12}

The mini-implants can be immediately loaded with retainers embedded in an existing well-fitting, occlusally correct, complete denture by pick-up when the ridge is composed of dense atrophic bone. As the mandibular ridge atrophies, the facial and lingual cortices approach one another. After a time, the intraosseous surfaces of the cortices may be 1–2 mm apart (Figure 4). This allows the placement of a small-diameter mini-implant that engages the facial and lingual dense cortices for excellent initial stability. The dense cortices provide excellent stability, allowing the mini-implants to be immediately loaded.

A lingualized or flat zero-degree occlusal scheme is best to prevent significant lateral or off-axial loads on the retaining implants.^{13–16}

Even though these mini-implants have small diameters, they are very durable and resistant to fatigue.¹³ One study demonstrated that mini-implants can withstand a million laterally directed load cycles without fracture.¹³

An overdenture retained by four mini-implants is generally not as retentive as Locator® retainers.^{14–16} Nonetheless, if there is adequate ridge length, additional implants can provide more retention that can be excellent.^{14–16} Flat zero-degree denture teeth or lingualized occlusal schemes may be most appropriate to minimize lateral loads.^{14–16}

If a mini-implant fails, there is typically only minor bone loss. A larger implant failure may have a much larger volume of bone loss that may present a risk for fracture of a thin atrophic mandible.^{14–16}

Progressive geriatric disorders such as dementia and Parkinson's disease will limit the patient's ability to cooperate and follow instructions. This may put this patient's oral health at risk. Successful dental treatment of frail patients should include an understanding of how the patient is medically, socially, and emotionally functioning.^{14–17}

Frail geriatric patients are a diverse group with multiple disabilities. Their life experiences can complicate clinical dental care. The treatment process should be based on a philosophy that addresses the best interests of the patient.^{14–17}

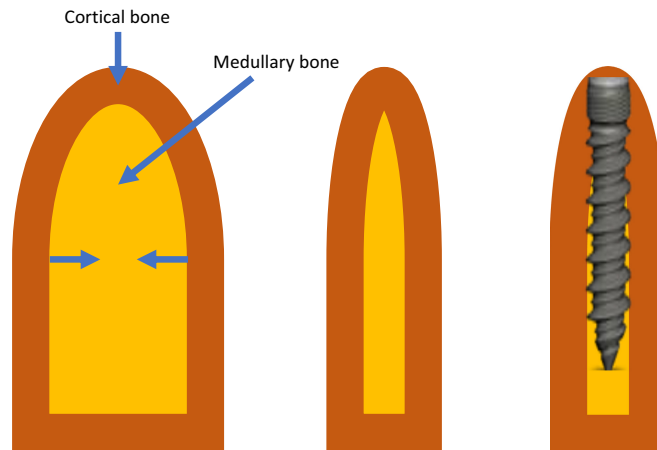


FIGURE 4 As the alveolar ridge atrophies, the facial and lingual cortices approach one another and provide dense facial and lingual bone, which provides excellent stability for the mini-implant. The flukes of the implant engage the cortices for excellent stability.

The patient and clinician working in tandem decide the treatment.^{17–19} The patient is informed of the risks and benefits. The treatment should be determined by the patient's health, functional needs, and quality of life, not their age. Elderly patients heal in the same fashion as younger patients.^{17–19} Patients older than 80 may have less bone loss and fewer implant failures than younger patients.^{18,19}

5 | CONCLUSIONS

Frail patients need adequate nutrition and a decent quality of life. Many of these patients are edentulous and can be bimaxillary atrophic. Improved quality of life may be provided with mini-implant treatment in atrophic jaws, especially in elderly patients in their waning years. A CBCT may be appropriate, to identify anatomical structures to be avoided. Anatomically appropriate long-length mini-implants that are immediately loaded to retain a denture may be an appropriate treatment for the frail patient. A flat zero-degree or lingualized occlusal scheme may be most appropriate. An unlikely high bite force capacity may indicate a contraindication for a denture retained with mini-implants. Post-treatment, careful follow-up is needed to ensure adequate function and outcome. There are advantages for these patients with mini-implant treatment. A failed mini-implant causes much less bone loss than a standard-sized implant failure. Additionally, mini-implant treatment has a relatively low associated cost. Contemporary CBCT enables mini-implants to be placed by general dentists.

AUTHOR CONTRIBUTIONS

Dennis Flanagan: Conceptualization; investigation; methodology; resources; supervision; validation; writing – original draft; writing – review and editing.

CONFLICT OF INTEREST STATEMENT

The author claims no financial, commercial, or political conflicts of interest.

DATA AVAILABILITY STATEMENT

All supporting information contained in this work has been cited in the reference section.

CONSENT

This patient did sign an informed consent and is available on request. Written informed consent was obtained from the patient to publish this report in accordance with the journal's patient consent policy.

ORCID

Dennis Flanagan  <https://orcid.org/0000-0002-6611-2764>

REFERENCES

1. Torpy JM, Lynn C, Glass RM. Frailty in older adults. *JAMA*. 2006;296(18):2280.
2. Fried LP, Tangen CM, Walston J, et al. Cardiovascular Health Study Collaborative Research Group. Frailty in older adults: evidence for a phenotype. *J Gerontol A Biol Sci Med Sci*. 2001;56(3):M146.
3. Kiely DK, Cupples LA, Lipsitz LA validation and comparison of two frailty indexes: the MOBILIZE Boston study. *J Am Geriatr Soc*. 2009;57(9):1532–1539.
4. Greene BR, Doheny EP, O'Halloran A, Anne KR. Frailty status can be accurately assessed using inertial sensors and the TUG test. *Age Ageing*. 2014;43(3):406–411.
5. Abellan van Kan G, Rolland Y, Bergman H, Morley JE, Kritchevsky SB, Vellas B. The I.A.N.A task force on frailty assessment of older people in clinical practice. *J Nutr Health Aging*. 2008;12(1):29–37.
6. Abellan van Kan G, Rolland Y, Houles M, Gillette-Guyonnet S, Soto M, Vellas B. The assessment of frailty in older adults. *Clin Geriatr Med*. 2010;26(2):275–286.

7. Lai JC, Ganger DR, Volk ML, et al. Association of frailty and sex with wait list mortality in liver transplant candidates in the multicenter Functional Assessment in Liver Transplantation (FrAILT) study. *JAMA Surg.* 2023;158(2):130-138. doi:[10.1001/jamasurg.2020.5674](https://doi.org/10.1001/jamasurg.2020.5674)
8. Sheikh SS, Locke JE. Leveraging frailty to mitigate sex-based disparities in access to liver transplant justice in allocation. *JAMA Surg.* 2020;156(3):263-265. doi:[10.1001/jamasurg.2020.5675](https://doi.org/10.1001/jamasurg.2020.5675)
9. Flanagan D. Rationale for definitive mini dental implant treatment. *J Oral Implantol.* 2020;47:437-444. doi:[10.1563/aaid-joi-D-19-00317](https://doi.org/10.1563/aaid-joi-D-19-00317)
10. Di Stefano DA, Arosio P, Pagnutti S, Vinci R, Gherlone EF. Distribution of trabecular bone density in the maxilla and mandible. *Implant Dent.* 2019;28(4):340-348.
11. Flanagan D. Bite force and dental implant treatment: a short review. *Med Devices.* 2017;27(10):141-148.
12. Flanagan D. Stented porcine collagen matrix to treat inadequate facial attached tissue of dental implant supported fixed partial dentures. *J Oral Implantol.* 2016;42(2):209-213.
13. Flanagan D, Ilies H, McCullough P, McQuoid S. Measurement of the fatigue life of mini dental implants: a pilot study. *J Oral Implantol.* 2008;34(1):7-11.
14. Fonteyne E, Van Doorne L, Becue L, Matthys C, Bronckhorst E, De Bruyn H. Speech evaluation during maxillary mini-dental implant overdenture treatment: a prospective study. *J Oral Rehabil.* 2019;46(12):1151-1160.
15. Zygogiannis K, Aartman IH, Wismeijer D. Implant mandibular overdentures retained by immediately loaded implants: a 1-year randomized trial comparing patient-based outcomes between mini dental implants and standard-sized implants. *Int J Oral Maxillofac Implants.* 2018;33(1):197-205.
16. Lemos CA, Verri FR, Batista VE, Júnior JF, Mello CC, Pellizzer EP. Complete overdentures retained by mini implants: a systematic review. *J Dent.* 2017;57:4-13.
17. Etöz O, Bertl K, Kukla E, Ulm C, Ozmeric N, Stavropoulos A. How old is old for implant therapy in terms of implant survival and marginal bone levels after 5-11 years? *Clin Oral Implants Res.* 2021;32(3):337-348.
18. Marchini L, Ettinger R, Hartshorn J. Personalized dental caries Management for Frail Older Adults and Persons with special needs. *Dent Clin N Am.* 2019;63(4):631-651. doi:[10.1016/j.cden.2019.06.003](https://doi.org/10.1016/j.cden.2019.06.003)
19. Ozmeric N, Stavropoulos A. How old is old for implant therapy in terms of implant survival and marginal bone levels after 5-11 years? *Clin Oral Implants Res.* 2020;32:337-348. doi:[10.1111/clar.13704](https://doi.org/10.1111/clar.13704)

How to cite this article: Flanagan D. Frailty and mini dental implants. *Clin Case Rep.* 2023;11:e7982. doi:[10.1002/ccr3.7982](https://doi.org/10.1002/ccr3.7982)