



OPEN ACCESS

EDITED BY

Pasquale Cianci,
Azienda Sanitaria Localedella Provincia di
Barletta Andri Trani (ASL BT), Italy

REVIEWED BY

Jiaxin Li,
People's Hospital of Dafang County, China
Vincenzo Lizzi,
Azienda Ospedaliero-Universitaria Ospedali
Riuniti di Foggia, Italy

*CORRESPONDENCE

Mingming Zhang
✉ mmzhangmd@163.com
Bo Zhang
✉ zhangbo_scu@scu.edu.cn

[†]These authors have contributed
equally to this work and share
first authorship

RECEIVED 22 October 2023

ACCEPTED 10 November 2023

PUBLISHED 28 November 2023

CITATION

Han Y, Yang W, Dai W, Ma Q, Yuan T,
Yang Y, Lu Y, Zhang B and Zhang M (2023)
Case Report: Laparoscopy-assisted
resection for intra-abdominal
gossypiboma masquerading as a
jejunal tumor (with video).
Front. Oncol. 13:1326032.
doi: 10.3389/fonc.2023.1326032

COPYRIGHT

© 2023 Han, Yang, Dai, Ma, Yuan, Yang, Lu,
Zhang and Zhang. This is an open-access
article distributed under the terms of the
[Creative Commons Attribution License
\(CC BY\)](https://creativecommons.org/licenses/by/4.0/). The use, distribution or
reproduction in other forums is permitted,
provided the original author(s) and the
copyright owner(s) are credited and that
the original publication in this journal is
cited, in accordance with accepted
academic practice. No use, distribution or
reproduction is permitted which does not
comply with these terms.

Case Report: Laparoscopy-assisted resection for intra-abdominal gossypiboma masquerading as a jejunal tumor (with video)

Yihui Han^{1,2†}, Wenming Yang^{3†}, Wenshu Dai⁴, Qin Ma³,
Tao Yuan⁵, Yun Yang^{1,6}, Yanrong Lu⁴,
Bo Zhang^{1,2*} and Mingming Zhang^{1,6*}

¹Department of General Surgery, West China Hospital, Sichuan University, Chengdu, China, ²Gastric Cancer Center, West China Hospital, Sichuan University, Chengdu, China, ³Division of Gastrointestinal Surgery, Department of General Surgery, West China Hospital, Sichuan University, Chengdu, China,

⁴Key Laboratory of Transplant Engineering and Immunology, National Health and Family Planning Commission (NHFP), West China Hospital, Sichuan University, Chengdu, China, ⁵Department of Anesthesiology, West China Hospital, Sichuan University, Chengdu, China, ⁶Colorectal Cancer Center, West China Hospital, Sichuan University, Chengdu, China

Introduction: Intra-abdominal gossypiboma, a cotton-based retained foreign body after an abdominal surgery, is associated with various clinical manifestations and complications. Its infrequent occurrence and unpredictability make its early diagnosis particularly challenging. We herein present an atypical case of intra-abdominal gossypiboma mistaken for a jejunal tumor.

Case presentation: A 33-year-old female presented to the emergency room with an acute episode of progressive abdominal pain and distention, nausea, and vomiting for 20 hours. She had undergone an urgent cesarean section due to fetal tachycardia seven years prior. The initial diagnosis of small bowel obstruction (SBO) due to a jejunal tumor was established by computed tomography. Subsequent to successful medical management of the SBO, a laparoscopy-assisted resection of the mass and the adherent jejunal segment was conducted, culminating in a primary side-to-side jejunojunctionostomy. Examination of the excised tissue revealed an approximately spherical fibrous mass, 6 × 6 × 5 cm in dimension, embedded in the jejunal wall, housing a 20 × 20-cm gauze. Postoperative recovery and routine follow-up ensued without complications.

Conclusion: In light of this case, the need for clinicians to maintain an elevated awareness and suspicion of gossypiboma should be accentuated when evaluating an intra-abdominal mass, especially in patients with a prior history of high-risk laparotomy. Laparoscopic surgery stands out as a technically proficient and minimally invasive strategy for diagnosing and treating intra-

abdominal gossypiboma. Besides, it is imperative to emphasize the importance of meticulous surgical procedures and postoperative protocols to prevent such oversights, reaffirming the need for consistent intraoperative counts and checks of surgical items.

KEYWORDS

intra-abdominal gossypiboma, tumor, iatrogenic complication, differential diagnosis, laparoscopic surgery

Introduction

Gossypiboma, derived from “gossypium” (Latin for cotton) and “boma” (Swahili for place of concealment), was first documented by Wilson in 1884 (1). It represents a rare yet entirely preventable iatrogenic complication (2). By definition, a gossypiboma is a cotton-based mass within a body cavity that results from the body’s reaction to a sponge or gauze inadvertently retained post-surgery. In the United States, the incidence varied from 1 in 1,000 – 1,500 to 1 in 8,801 - 18,760 inpatient operations in the past decades (3). Due to malpractice claims and medicolegal consequences involved, the actual incidence of gossypiboma remains unknown and definitely underestimated (4). The gossypiboma formation are reported to be significantly associated with emergency surgery, unplanned changes in procedure, morbid obesity, and multiple major procedures done in a single operation or cases in which multiple surgical teams were involved (3, 5, 6).

The abdominopelvic cavity was the most frequent body cavity where the foreign body left (54%), followed by vagina (22%), thorax (7%), and others (17%; including the spinal canal, face, brain, and extremities) (3). Notably, while gossypibomas are less likely to occur in laparoscopic or robotic procedures, their prevalence is higher in laparotomy (7). Intra-abdominal gossypiboma patients can present to hospital with various clinical manifestations and even significant morbidity, such as ileus, perforation, abscess collection, fistula formation, and sepsis (8, 9). Due to rare and unanticipated, precise preoperative diagnosis of intra-abdominal gossypiboma is extremely challenging (10).

In alignment with the principles of the CAse REport (CARE) guidelines (11), we herein describe an unusual case of intra-abdominal gossypiboma complicated by ileus and masquerading as a jejunal tumor, which was treated successfully by laparoscopy-assisted resection. In light of this case, it is imperative to emphasize the importance of meticulous surgical procedures and postoperative protocols to prevent such oversights, reaffirming the need for consistent intraoperative counts and checks of surgical items.

Case presentation

In November 2022, a 33-year-old Han Chinese female patient was referred to our emergency room with progressive abdominal pain (colicky in nature; sudden onset, continuous, crushing in

character) and distention, nausea, and vomiting for 20 hours. She had undergone an urgent cesarean section because of fetal tachycardia 7 years previously. There were no underlying comorbidities or family history of malignancies with her. On admission, she was subfebrile with slightly abnormal vital signs (Temperature, 37.5°C; Blood pressure, 108/72 mmHg; Heart rate, 102 beats per minute; Respiratory rate, 19 beats per minute). Physical examination showed abdominal distention, slight rebound tenderness in the periumbilical area, and a painless palpable mass in the lower quadrant with metallic bowel sounds. The result of digital rectal examination was unremarkable.

Blood tests indicated a systemic infection with an elevated total leukocyte count ($13.2 \times 10^9/L$; reference range, $3.5 - 9.5 \times 10^9/L$), percentage of neutrophils (91%; reference range, 40 - 75%), and C-reaction protein (36 mg/L; reference range, <5 mg/L). Contrast-enhanced computed tomography (CT) of the abdomen and pelvis demonstrated dilated proximal bowel loops and multiple air-fluid levels due to a 6.1 × 5.7-cm, approximately spherical, well-delineated heterogeneous cystic and hyperdense jejunal mass and mild intestinal volvulus, without indicators of intestinal ischemia or necrosis (Figure 1). There were no metastases to the liver, greater omentum, or peritoneum detectable on radiologic imaging.

The preliminary suspected diagnosis of SBO due to a jejunal tumor and mild intestinal volvulus was established by above clinical findings. The physical condition of the patient was optimized and elective laparoscopic exploration was then scheduled for her (12). Intraoperatively, a solitary jejunal mass was found to be the possible lead point of intestinal volvulus and subsequent SBO. Therefore, laparoscopy-assisted resection surgery was performed according to the following steps (13, 14): (1) adhesiolysis and complete mobilization of the intra-abdominal mass; (2) extracorporeal resection with wide surgical margin of the mass and segmental jejunum (15); (3) primary side-to-side jejunojejunostomy; (4) check for a safe anastomosis and no intestinal volvulus under laparoscopy (16); (5) peritoneal irrigation and drainage placement (Supplementary Material Figure S1; Supplementary Material Video S1). The procedure lasted 115 minutes, with estimated blood loss of 20 ml.

Gross examination of the resected specimen demonstrated a 6 × 6 × 5 cm in dimension, approximately spherical mass of fibrous hyperplasia adherent to the jejunal wall, which contained a 20 × 20-cm surgical gauze (Figure 2). Given potential medicolegal consequences, histopathologic examination was not conducted. Because of the possibility of negative result under effective

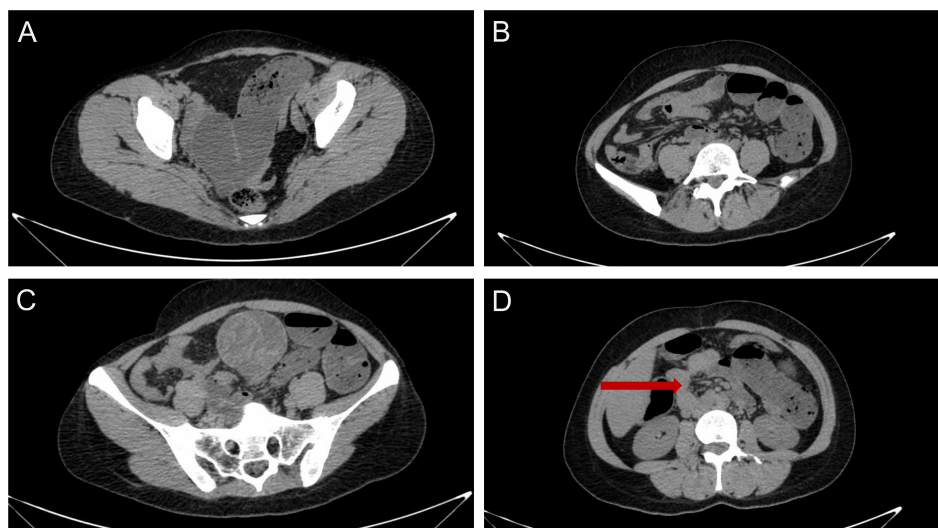


FIGURE 1

Computed tomography of the abdomen and pelvis indicated (A, B) dilated proximal bowel loops and multiple air-fluid levels due to (C) a 6.1 × 5.7-cm, approximately spherical, well-delineated heterogeneous cystic and hyperdense jejunal mass and (D) mild intestinal volvulus, without indicators of intestinal ischemia or necrosis.

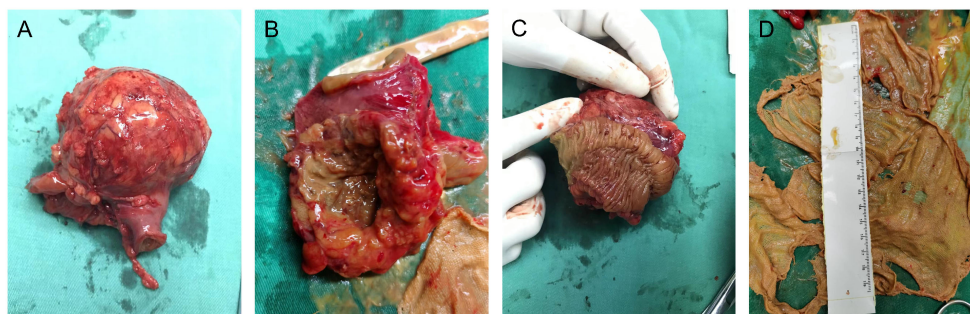


FIGURE 2

Gross examination of the surgical specimen demonstrated a 6 × 6 × 5-cm, approximately spherical mass of fibrous hyperplasia adherent to the jejunal wall (A–C), which contained a 20 × 20-cm gauze (D).

antibiotics treatment preoperatively, the gauze was not sent to bacteriology examination. Postoperatively, the patient was transferred back to the general medical ward. Complying with the pathway of enhanced recovery after surgery, the course of postoperative rehabilitation was uneventful, with first flatus on postoperative day (POD) 1 and oral feeding beginning on POD 2. The patient was discharged on POD 6 without any complications. So far, the regular follow-up of 9 months has been unremarkable. The timeline with corresponding clinical data from the period of care is shown in Figure 3.

Discussion

A systematic literature search was conducted in the PubMed database utilizing medical subject headings and text words related to “intra-abdominal gossypiboma” to acquire relevant case reports

published till October 13, 2023. The search strategy and syntax for PubMed database are shown in Supplementary material Table S1. The studies with initial misdiagnosis as intra-abdominal tumor met the eligible criteria. Systematic reviews, case series with unavailable individual patient data, and articles with non-English languages or animal subjects were excluded. The general characteristics of the enrolled studies were extracted and entered into a preplanned electronic form (Table 1). The pooled data were summarized in a narrative and descriptive way.

As a result, 233 articles were screened for further potential. Then, 20 cases with intra-abdominal gossypibomas which were initially misdiagnosed as tumors in 19 literature (between 1979 to 2023) met the inclusion criteria (17–35). Overall, the relevant case reports focusing on this special population emerged rapidly in the past decade. These events of initial misdiagnosis proved to occur mostly in Asian countries (15/19), especially Turkey. Despite the risk of publication bias, relatively insufficient healthcare resources

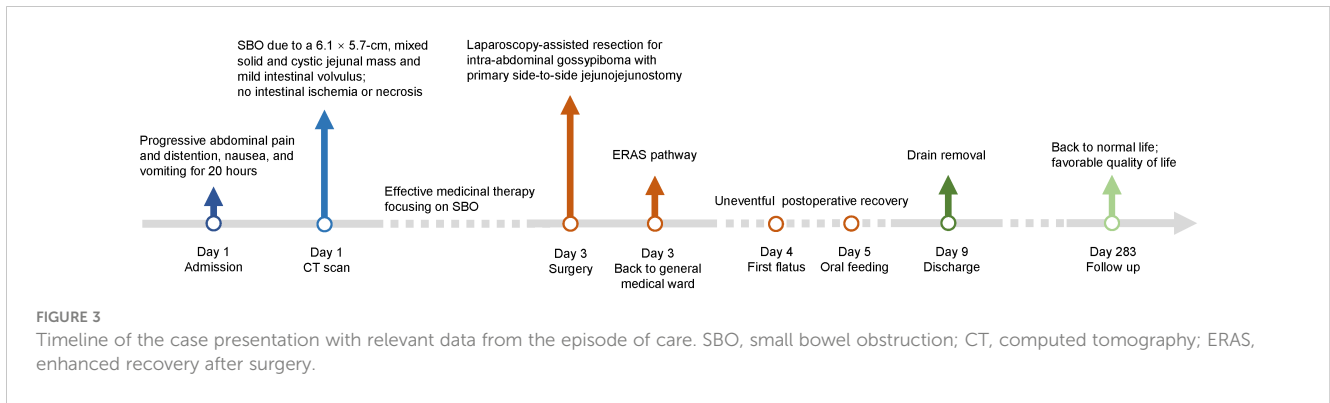


TABLE 1 General characteristics of the included case reports regarding intra-abdominal gossypiboma with initially suspected diagnosis as tumor.

| First author | Year | Country | Age & Sex | Previous operation | Interval | Clinical presentation | Diagnostic method | Initial diagnosis | Treatment |
|-----------------|------|---------|-----------|-------------------------------------|----------|---|-------------------|--------------------------|---|
| Jason RS (17) | 1979 | USA | 39 M | exploratory laparotomy | 12 y | intermittent abdominal pain associated with a firm, non-tender epigastric mass | upper GI series | pancreatic carcinoma | surgical removal of the sponge & cystogastrostomy for the lesser sac cyst |
| Cheng TC (18) | 2007 | China | 61 M | total gastrectomy | 8 y | intermittent right upper abdominal pain | CT | recurrent gastric cancer | surgical resection |
| Yamamura N (19) | 2008 | Japan | 78 M | distal gastrectomy; cholecystectomy | 40/15 y | asymptomatic | CT, EUS, MRI | gastric GIST | surgical resection |
| Akbulut S (20) | 2011 | Turkey | 51 M | laparotomy | 8 y | colicky abdominal pain, intermittent abdominal distention, constipation, nausea, and vomiting | CT | ileal tumor | segmental ileal resection |
| Bulus H (21) | 2011 | Turkey | 67 F | laparotomy for acute cholecystitis | 5 y | recurrent, vague, central abdominal pain | US, CT | small bowel GIST | segmental jejunal resection |
| Cheon JW (22) | 2011 | Korea | 78 F | partial gastrectomy | 30 y | sudden onset epigastric pain | CT, EGD, US | gastric GIST | wedge resection of gastric fundus |
| Kawamura Y (23) | 2012 | Japan | 41 F | cesarean section | 2 y | intermittent abdominal pain | CT, MRI | GIST | resection of the tumor together with adherent small bowel |
| Shen HP (24) | 2012 | China | 68 F | total hysterectomy | 25 y | abdominal fullness, constipation, and a palpable protruding mass from the rectum | colonoscopy, US | adnexal malignancy | surgical resection |
| George AJP (25) | 2014 | India | 46 F | right nephrectomy | 8 y | continuous right flank pain | CT | retroperitoneal tumor | surgical resection |
| Eken H (26) | 2016 | Turkey | 62 F | myomectomy | 20 y | stomachache, distention, and constipation | CT, MRI | mesenchymal malignancy | resection of the bulk together with adherent small bowel |

(Continued)

TABLE 1 Continued

| First author | Year | Country | Age & Sex | Previous operation | Interval | Clinical presentation | Diagnostic method | Initial diagnosis | Treatment |
|---------------------|------|---------|-----------|-----------------------------|----------|---|-------------------|------------------------|---|
| Singla N (27) | 2016 | USA | 75 F | hysterectomy | NA | lower abdominal pain and fullness | CT | urachal tumor | resection of the urachal mass with a cuff of adherent dome of bladder |
| Nishimura N (28) | 2017 | Japan | 67 F | hysterectomy | 24 y | hematochezia | colonoscopy, CT | transverse colon tumor | resection of the mass together with the transverse colon |
| Zhang H (29) | 2017 | China | 32 F | cesarean section | 8 y | intermittent left lower abdominal pain | US, CT | ovarian teratoma | resection of the mass together with adhesive small bowel |
| Oran E (30) | 2018 | Turkey | 28 F | open cholecystectomy | 3 y | abdominal pain | CT, MRI | pancreatic carcinoma | surgical resection |
| Oran E (30) | 2018 | Turkey | 36 F | cesarean section (twice) | 13/15 y | painful mass in the left lower quadrant | US, CT | left ovarian tumor | surgical resection |
| Arikan Y (31) | 2019 | Turkey | 74 M | open pyelolithotomy | 20 y | asymptomatic | MRI | left kidney malignancy | left partial nephrectomy |
| Boghratian AH (32) | 2020 | Iran | 30 F | mini gastric bypass | 2 mo | nausea, non-bloody vomiting, and abdominal pain | CT | small bowel malignancy | endoscopic removal |
| Celik H (33) | 2021 | Turkey | 36 F | ectopic pregnancy operation | 7 y | severe abdominal pain and distension | US, CT | intra-abdominal tumor | resection of the mass together with adherent small bowel |
| Hajri A (34) | 2021 | Morocco | 65 F | open cholecystectomy | 29 y | nausea and vomiting, loss of appetite and weight loss | EGD, CT | GIST | atypical hepatectomy of segment 3 |
| Modrzejewski A (35) | 2023 | Poland | 49 F | myomectomy | 2 y | urinary incontinence | CT | sigmoid colon tumor | NA |

M, male; F, female; y, years; mo, months; GI, gastrointestinal; CT, computed tomography; EUS, endoscopic ultrasonography; MRI, magnetic resonance imaging; GIST, gastrointestinal stromal tumor; US, ultrasonography; EGD, esophagogastroduodenoscopy; NA, not available.

in transitioning economies could definitely contribute to higher incidence rate of intra-abdominal gossypiboma to some extent. Female patients accounted for 75% of the included cases (15/20). Previous obstetrics and gynecology surgery remained the leading cause of intra-abdominal gossypiboma (9/20), followed by open cholecystectomy (4/20), gastrectomy (4/20), urinary operations (2/20), and other laparotomies. The interval between the previous procedures to the present diagnosis of intra-abdominal gossypiboma ranged from 2 months to 40 years. The most common diagnostic tools were CT and ultrasonography (US). In terms of tumor, the predominant misdiagnosis for these patients as well as our reported case was gastrointestinal stromal tumor (GIST).

The optimal approach to dealing with this iatrogenic surgical complication is prevention. For surgeries associated with high risk of retained surgical sponge (RSS) as mentioned above, repeated sponge counting at the key time point (such as beginning and ending of the operation, handover of surgical team, closure of the peritoneum, and every 3 hours) should be advocated and emphasized (2). All the surgeons, assistants, and operating theater

nurses should take a meticulous and responsible attitude towards the patient's life and postoperative quality of life. On the other hand, the application of radiopaque marker and quick response code within the surgical sponge is highly advisable (36–38). However, routinely postoperative plain films to identify RSS is not recommended. Small sponges should be abandoned during laparotomy while surgical compresses should be employed only intraperitoneally and one by one. A thorough intraperitoneal exploration prior to closure of the peritoneum is also crucial to minimize the risk of RSS. In a word, the prevention of RSS requires a high sense of responsibility, standardized clinical practice, diversified knowledge, and shared information.

As mentioned above, intra-abdominal gossypibomas are associated with unpredictable clinical presentations and the possibility of a long interval between the previous surgery and current episode (9). It may be discovered most frequently by a different surgeon rather than the one who did the previous procedure. It is critical for clinicians to hold a high index of suspicion of intra-abdominal gossypiboma when evaluating the

episode of new symptoms in these patients with a distant history of high-risk laparotomy. Radiologic examinations (including CT, US, and MRI) can help establish preliminary diagnosis (10). For intra-abdominal gossypiboma presenting as a mass, the common differential diagnoses include GIST, tumor of the small bowel and colon, retroperitoneal tumor, and intra-abdominal abscess. Noticeably, the gossypiboma and abscess can co-exist in the same patient. The role of percutaneous biopsy under the guidance of US or CT and histopathologic examination in the diagnosis of an intra-abdominal mass should be emphasized, once a malignancy tumor cannot be ruled out (27).

Furthermore, gastrointestinal endoscopy, as well as cystoscopy and ureteroscopy, can be applied to identify transmural migration and sometimes remove the RSS (32, 39). For a long time, redo exploratory laparotomy remains the frequent and vital method to finally confirm the diagnosis and treat this specific patient population. However, with minimal invasion and improved visualization, laparoscopic and robotic-assisted approaches have been placed high hopes in the management of intra-abdominal gossypiboma, especially with preoperatively ambiguous diagnosis (40, 41).

In conclusion, our case report accentuates the need for clinicians to maintain an elevated awareness and suspicion of gossypiboma when evaluating an intra-abdominal mass, especially in patients with a prior history of high-risk laparotomy. Laparoscopic surgery stands out as a technically proficient and minimally invasive strategy for diagnosing and treating intra-abdominal gossypiboma.

Data availability statement

The original contributions presented in the study are included in the article/Supplementary Material. Further inquiries can be directed to the corresponding author.

Ethics statement

The studies involving humans were approved by Biomedical Ethical Committee of West China Hospital, Sichuan University. The studies were conducted in accordance with the local legislation and institutional requirements. The participants provided their written informed consent to participate in this study. Written informed consent was obtained from the individual(s) for the publication of any potentially identifiable images or data included in this article.

Author contributions

YH: Writing – original draft, Project administration. WY: Writing – original draft, Project administration. WD: Writing – original draft. QM: Writing – review & editing, Data curation, Investigation, Visualization. TY: Writing – review & editing,

Formal Analysis, Software. YY: Writing – review & editing, Formal Analysis, Software. YL: Writing – review & editing, Supervision. BZ: Supervision, Writing – review & editing, Conceptualization, Funding acquisition, Methodology. MZ: Supervision, Writing – review & editing, Conceptualization, Funding acquisition, Methodology.

Funding

The author(s) declare financial support was received for the research, authorship, and/or publication of this article. This research was funded by the 1-3-5 Project for Disciplines of Excellence, West China Hospital, Sichuan University (Grant No. ZYJC18034 and ZYJC21021) and Sichuan Provincial Administration of Traditional Chinese Medicine (Grant No. 2023MS173).

Acknowledgments

We would like to thank all the staff from Department of Anesthesiology & Operation Room, West China Shangjin Hospital, Sichuan University for their professional and kind support.

Conflict of interest

The authors declare that the research was conducted in the absence of any commercial or financial relationships that could be construed as a potential conflict of interest.

Publisher's note

All claims expressed in this article are solely those of the authors and do not necessarily represent those of their affiliated organizations, or those of the publisher, the editors and the reviewers. Any product that may be evaluated in this article, or claim that may be made by its manufacturer, is not guaranteed or endorsed by the publisher.

Supplementary material

The Supplementary Material for this article can be found online at: <https://www.frontiersin.org/articles/10.3389/fonc.2023.1326032/full#supplementary-material>

SUPPLEMENTARY FIGURE 1

The flow diagram of the surgical procedure, extracorporeal resection of the mass and segmental jejunum with primary side-to-side jejunojejunostomy.

SUPPLEMENTARY VIDEO 1

Laparoscopy-assisted resection for intra-abdominal gossypiboma masquerading as a jejunal tumor.

References

- Wilson HPC. Foreign bodies left in the abdomen after laparotomy. *Gynecol Tr* (1884) 9:109–12.
- Lauwers PR, Van Hee RH. Intraperitoneal gossypibomas: the need to count sponges. *World J Surg* (2000) 24:521–7. doi: 10.1007/s002689910084
- Gawande AA, Studdert DM, Orav EJ, Brennan TA, Zinner MJ. Risk factors for retained instruments and sponges after surgery. *N Engl J Med* (2003) 348:229–35. doi: 10.1056/NEJMsa021721
- Yakar A, Atacan SÇ, Yakar F, Ziyade N, Gündoğmuş ÜN. Medicolegal consequences of thoracic gossypiboma: a case report. *J Forensic Leg Med* (2016) 42:65–7. doi: 10.1016/j.jflm.2016.05.010
- Bani-Hani KE, Gharaibeh KA, Yaghan RJ. Retained surgical sponges (gossypiboma). *Asian J Surg* (2005) 28:109–15. doi: 10.1016/s1015-9584(09)60273-6
- Lincourt AE, Harrell A, Cristiano J, Sechrist C, Kercher K, Heniford BT. Retained foreign bodies after surgery. *J Surg Res* (2007) 138:170–4. doi: 10.1016/j.jss.2006.08.001
- Gibbs VC. Retained surgical items and minimally invasive surgery. *World J Surg* (2011) 35:1532–9. doi: 10.1007/s00268-011-1060-4
- Ryan G, Kawka M, Gnananandan J, Yip V. Presentation and surgical management of a gossypiboma presenting with small bowel obstruction. *Clin J Gastroenterol* (2021) 14:1067–70. doi: 10.1007/s12328-021-01400-y
- Sozutek A, Colak T, Reyhan E, Turkmenoglu O, Akpınar E. Intra-abdominal gossypiboma revisited: Various clinical presentations and treatments of this potential complication. *Indian J Surg* (2015) 77:1295–300. doi: 10.1007/s12262-015-1280-1
- Manzella A, Filho PB, Albuquerque E, Farias F, Kaercher J. Imaging of gossypibomas: pictorial review. *AJR Am J Roentgenol* (2009) 193:S94–101. doi: 10.2214/AJR.07.7132
- Riley DS, Barber MS, Kienle GS, Aronson JK, von Schoen-Angerer T, Tugwell P, et al. CARE guidelines for case reports: explanation and elaboration document. *J Clin Epidemiol* (2017) 89:218–35. doi: 10.1016/j.jclinepi.2017.04.026
- Liu K, Chen X-Z, Zhang W-H, Zhang D-Y, Luo Y, Yu Y, et al. “Four-Step Procedure” of laparoscopic exploration for gastric cancer in West China Hospital: a retrospective observational analysis from a high-volume institution in China. *Surg Endosc* (2019) 33:1674–82. doi: 10.1007/s00464-018-6605-2
- Hu J, Or BHN, Hu K, Wang ML. Comparison of the post-operative outcomes and survival of laparoscopic versus open resections for gastric gastrointestinal stromal tumors: A multi-center prospective cohort study. *Int J Surg Lond Engl* (2016) 33 Pt A:65–71. doi: 10.1016/j.ijsu.2016.07.064
- Xiong Z, Wan W, Zeng X, Liu W, Wang T, Zhang R, et al. Laparoscopic versus open surgery for gastric gastrointestinal stromal tumors: A propensity score matching analysis. *J Gastrointest Surg* (2020) 24:1785–94. doi: 10.1007/s11605-019-04318-6
- Åhlén J, Karlsson F, Wejde J, Nilsson I-L, Larsson C, Bränström R. Wide surgical margin improves the outcome for patients with gastrointestinal stromal tumors (GISTs). *World J Surg* (2018) 42:2512–21. doi: 10.1007/s00268-018-4498-9
- Hwang RF, Swartz DE, Felix EL. Causes of small bowel obstruction after laparoscopic gastric bypass. *Surg Endosc* (2004) 18:1631–5. doi: 10.1007/s00464-004-8804-2
- Jason RS, Chisolm A, Lubetsky HW. Retained surgical sponge simulating a pancreatic mass. *J Natl Med Assoc* (1979) 71:501–3.
- Cheng T-C, Chou AS-B, Jeng C-M, Chang P-Y, Lee C-C. Computed tomography findings of gossypiboma. *J Chin Med Assoc* (2007) 70:565–9. doi: 10.1016/S1726-4901(08)70063-7
- Yamamura N, Nakajima K, Takahashi T, Uemura M, Nishitani A, Souma Y, et al. Intra-abdominal textiloma. A retained surgical sponge mimicking a gastric gastrointestinal stromal tumor: report of a case. *Surg Today* (2008) 38:552–4. doi: 10.1007/s00595-007-3654-x
- Akbulut S, Arıkanoglu Z, Yagmur Y, Basbug M. Gossypibomas mimicking a splenic hydatid cyst and ileal tumor: a case report and literature review. *J Gastrointest Surg* (2011) 15:2101–7. doi: 10.1007/s11605-011-1592-9
- Buluş H, Şimşek G, Coşkun A, Koyuncu A. Intraabdominal gossypiboma mimicking gastrointestinal stromal tumor: a case report. *Turk J Gastroenterol* (2011) 22:534–6. doi: 10.4318/tjg.2011.0269
- Cheon JW, Kim EY, Kim KY, Park JB, Shin YK, Kim KY, et al. A case of gossypiboma masquerading as a gastrointestinal stromal tumor. *Clin Endosc* (2011) 44:51–4. doi: 10.5946/ce.2011.44.1.51
- Kawamura Y, Ogasawara N, Yamamoto S, Sasaki M, Kawamura N, Izawa S, et al. Gossypiboma mimicking gastrointestinal stromal tumor causing intestinal obstruction: a case report. *Case Rep Gastroenterol* (2012) 6:232–7. doi: 10.1159/000338833
- Shen H-P, Tseng C-J, Lin L-Y, Lin Y-H, Chen H-Y, Ying T-H, et al. Retroperitoneal gossypiboma 25 years after abdominal hysterectomy. *Taiwan J Obstet Gynecol* (2012) 51:460–2. doi: 10.1016/j.tjog.2012.07.030
- George AJP, Mukha RP, Kekre NS. Gossypiboma mimicking a retroperitoneal tumor. *Urology* (2014) 84:e13–14. doi: 10.1016/j.urolgy.2014.06.018
- Eken H, Soyuturk M, Balci G, Firat D, Cimen O, Karakose O, et al. Gossypiboma mimicking a mesenchymal tumor: A report of a rare case. *Am J Case Rep* (2016) 17:27–30. doi: 10.12659/ajcr.896717
- Singla N, Haddad AQ, Cefalu C, Margulis V. Gossypiboma manifesting as urachal mass. *Rev Urol* (2016) 18:239–41. doi: 10.3909/riu0703
- Nishimura N, Mizuno M, Shimodate Y, Doi A, Mouri H, Matsueda K, et al. Gossypiboma with bleeding from fistula to the colon observed by colonoscopy. *Clin J Gastroenterol* (2017) 10:37–40. doi: 10.1007/s12328-016-0699-7
- Zhang H, Jiang Y, Wang Q, Liu J. Lower abdominal gossypiboma mimics ovarian teratoma: a case report and review of the literature. *World J Surg Oncol* (2017) 15:6. doi: 10.1186/s12957-016-1082-3
- Oran E, Yetkin G, Aygün N, Celayir F, Uludağ M. Intraabdominal gossypiboma: Report of two cases. *Turk J Surg* (2018) 34:77–9. doi: 10.5152/turksurg.2017.3147
- Arıkan Y, Ozdemir O, Seker KG, Eksi M, Guner E, Kalfazade N, et al. Gossypiboma: A dramatic result of human error, case report and literature review. *Prague Med Rep* (2019) 120:144–9. doi: 10.14712/23362936.2019.20
- Boghration AH, Al-Taeae AM. Gossypiboma masquerading as small bowel Malignancy. *Middle East J Dig Dis* (2020) 12:123–5. doi: 10.34172/mejdd.2020.172
- Celik H, Akin IB, Altay C, Bisgin T, Obuz F. Giant gossypiboma presenting as a pelvic mass. *Radiol Case Rep* (2021) 16:3308–10. doi: 10.1016/j.radcr.2021.07.075
- Hajri A, Touimi KB, El Berni Y, Erguibi D, Boufettal R, Rifki Jai S, et al. Abdominal textiloma mimicking as gastrointestinal stromal tumor: a case report. *Ann Med Surg* (2021) 70:102795. doi: 10.1016/j.amsu.2021.102795
- Modrzejewski A, Kaźmierczak KM, Kowalik K, Grochal I. Surgical items retained in the abdominal cavity in diagnostic imaging tests: a series of 10 cases and literature review. *Pol J Radiol* (2023) 88:e264–9. doi: 10.5114/pjr.2023.127668
- Fabian CE. Electronic tagging of surgical sponges to prevent their accidental retention. *Surgery* (2005) 137:298–301. doi: 10.1016/j.surg.2004.10.003
- Greenberg CC, Diaz-Flores R, Lipsitz SR, Regenbogen SE, Mulholland L, Mearn F, et al. Bar-coding surgical sponges to improve safety: a randomized controlled trial. *Ann Surg* (2008) 247:612–6. doi: 10.1097/SLA.0b013e3181656cd5
- Cima RR, Kollengode A, Clark J, Pool S, Weisbrod C, Amstutz GJ, et al. Using a data-matrix-coded sponge counting system across a surgical practice: impact after 18 months. *Jt Comm J Qual Patient Saf* (2011) 37:51–8. doi: 10.1016/s1553-7250(11)37007-9
- Enebe JT, Ilo CA, Ofor JJ, Chukwubuike KE, Omeke CA, Udeozor NV, et al. Gossypiboma: Spontaneous trans-urethral migration of a forgotten surgical gauze sponge 5 years post hysterectomy in grand multiparous post-menopausal woman. *Int J Surg Case Rep* (2020) 71:168–71. doi: 10.1016/j.ijscr.2020.04.104
- Tărcoveanu E, Dimofte G, Georgescu S, Vasilescu A, Lupăşcu C, Bradea C, et al. Laparoscopic retrieval of gossypibomas—short series and review of literature. *Acta Chir Belg* (2011) 111:366–9. doi: 10.1080/00015458.2011.11680774
- Soori M, Shadidi-Asil R, Kialashaki M, Zamani A, Ebrahimiyan M. Successful laparoscopic removal of gossypiboma: A case report. *Int J Surg Case Rep* (2022) 91:106799. doi: 10.1016/j.ijscr.2022.106799