



Pleural effusion due to lymphangiomatosis and the role of sirolimus: A case report

Muhammad Riazuddin, MBBS^a, Noha I. Farouk, MBBS^b, Saad S. Ali, MBBS^c, Muhammad I. Butt, MBBS^a, Tarek Z. Arabi, MBBS^{c,*}, Belal N. Sabbah, MBBS^c, Maha S. Ali, MBBS^c, Khaled Alkattan, MBBS^c

Introduction: Lymphangiomatosis is a rare abnormal proliferation of lymphatic vessels involving multiple organs like the brain, lung, heart, spleen, liver, and bones. Lymphangiomas constitute 5.6% of all benign tumors in infancy and adulthood.

Case presentation: We report a case of a young lady who presented with constitutional symptoms and progressive dyspnea. Her medical history is significant for muco-cutaneous albinism, diffuse hemangiomas of the bone and viscera, and consumptive coagulopathy status post-splenectomy. After initial investigations, she was found to have right-sided pleural effusion. Pleural fluid analysis indicated chylothorax. She had multiple drainages of the pleural fluid done, and afterward, ligation of the right thoracic duct was performed with a trial of sirolimus, which improved her chylothorax.

Clinical discussion: Several case reports have reported positive outcomes with sirolimus in the treatment of lymphangiomatosis. However, larger controlled studies are needed to confirm these findings.

Conclusion: Sirolimus is promising as a medical treatment for diffuse pulmonary lymphangiomatosis.

Keywords: chylothorax, lymphangiomatosis, lymphatic vessels, pleural fluid, sirolimus

Introduction

Diffuse lymphangiomatosis is a very uncommon lymphatic disorder. It develops through the lymphatic system, affecting different parts of the human body that contain lymph nodes. It is considered fatal amongst newborns and children because of its aggressive growing compression of the bone^[1,2]. Lymphangiomas can be localized tumors that affect a single organ or multiple organs. It is caused by lymphatic development abnormalities as it proliferates, anastomoses the lymphatic vessels, and makes the tumor uncontrollable. Lymphangiomas commonly affect the lungs, pleura, brain, thorax, back, and neck. When the lungs are involved, they are classified as diffused pulmonary lymphangiomatosis (DPL) and attributed to the organ system with the most deaths.

The survival rate of DPL is low, especially in children younger than 16 years^[3]. The diagnosis of lymphangiomatosis is

HIGHLIGHT

- Diffuse pulmonary lymphangiomatosis (DPL) is a rare proliferation of the lymphatic vessels.
- DPL may present with severe pleural effusion.
- Treatment with sirolimus can effectively relieve the DPL-related symptoms.

challenging owing to the rarity of the disease and the nonspecific presentation, as it is commonly misdiagnosed as different types of respiratory disorders; however, lung function tests can be helpful in determining the diagnosis^[4]. The treatment of lymphangiomatosis is not yet standardized and is usually based on case reports in the literature, the patient's presenting symptoms, and pathology^[2,5]. Therefore, in this article, we report the case of an 18-year-old female with lymphangiomatosis who was successfully treated with sirolimus. This manuscript was reported according to the CARE criteria^[6].

Case presentation

An 18-year-old female was presented to the emergency department with a one-day history of fever, vomiting, and progressive shortness of breath. Her past medical history included muco-cutaneous albinism, diffuse hemangioma of the bone and viscera, consumptive coagulopathy status post-splenectomy 10 years ago, and a history of meningitis in the past. She was non-compliant with her penicillin V prophylaxis therapy. On examination, she was vitally stable on room air, and albinism was noted all over the skin. There was no palpable lymphadenopathy and normal audible first and second heart sounds with no added mummings. Chest examination showed decreased chest expansion over the right side with decreased breath sounds, decreased vocal

^aDepartment of Internal Medicine, King Faisal Specialist Hospital and Research Center, ^bCollege of Medicine, Dar al Uloom University and ^cCollege of Medicine, Alfaisal University, Riyadh, Saudi Arabia

Sponsorships or competing interests that may be relevant to content are disclosed at the end of this article.

*Corresponding author. Address: College of Medicine, Alfaisal University, Takhassusi Street, Riyadh 11533, Saudi Arabia. Tel./fax: +11 215 7777. E-mail: tarabi@alfaisal.edu (T.Z. Arabi).

Copyright © 2023 The Author(s). Published by Wolters Kluwer Health, Inc. This is an open access article distributed under the terms of the Creative Commons Attribution-Non Commercial License 4.0 (CCBY-NC), where it is permissible to download, share, remix, transform, and build up the work provided it is properly cited. The work cannot be used commercially without permission from the journal.

Annals of Medicine & Surgery (2023) 85:6178–6181

Received 10 August 2023; Accepted 28 September 2023

Published online 5 October 2023

<http://dx.doi.org/10.1097/MS9.0000000000001384>

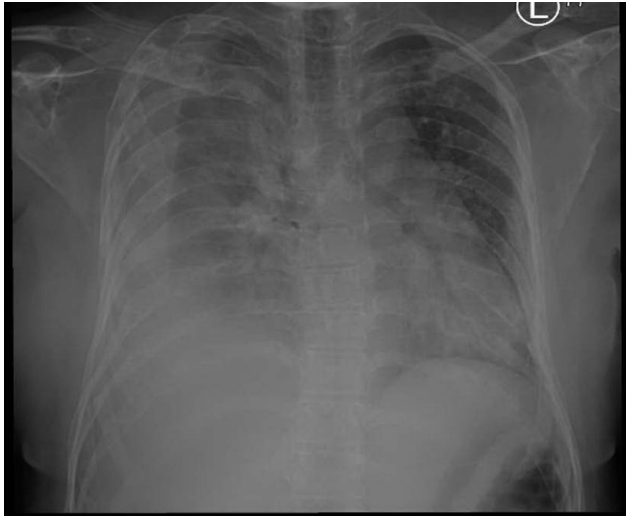


Figure 1. Chest X-ray revealing right-sided pleural effusion and multiple lytic lesions of the ribs and clavicle.

resonance, and dull percussion. Abdomen examination was only remarkable for the splenectomy scar, and nervous system examination was unremarkable. Initial blood results revealed an elevated white blood cell count of $20.31 \times 10^9/l$. Coagulation, renal, and liver profiles were normal.

Her chest X-ray at presentation showed right-sided pleural effusion and multiple lytic lesions with expansion of the ribs and clavicle, as well as the scapula (Fig. 1). Subsequently, the patient underwent ultrasound-guided diagnostic and therapeutic pleural tapping with pigtail insertion for pleural fluid drainage. The results of the pleural fluid analysis can be seen in Table 1.

A high-resolution computed tomography (CT) scan revealed a large right-sided pleural effusion with significant collapse of the right lung (Fig. 2). Mildly enlarged lymph nodes were also seen in the mediastinum and the right axilla. Due to the presence of lymph nodes noted in the CT scan, suspicion of malignancy was raised. A free needle aspiration was performed; however, the results were inconclusive. The patient did not wish to undergo a biopsy of the lesion. Therefore, a positive emission tomography-CT was done and was negative for significant uptake. Pleural fluid was continuously drained from the chest pigtail. The patient was then managed conservatively with octreotide and a low-lipid diet. However, the patient did not improve, and the pigtail was draining between 1000 and 1500 ml of pleural fluid daily.

A multidisciplinary team meeting was arranged, and it was decided to conduct a lymphogram study, which confirmed systemic malformation of lymphatic vessels. Accordingly, the patient

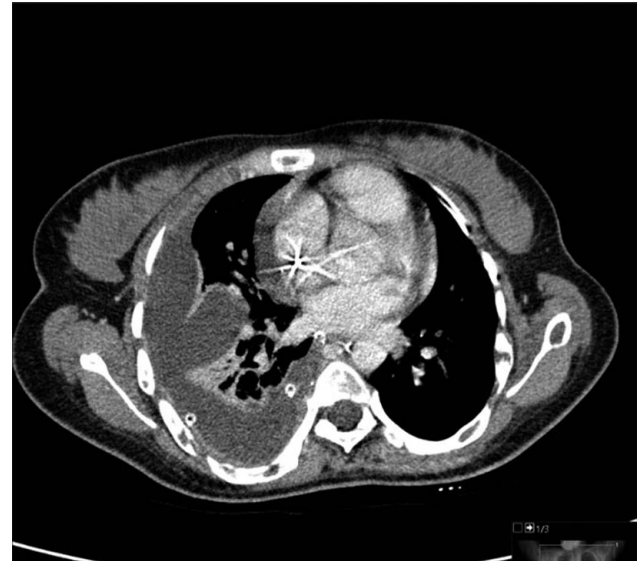

Figure 2. Axial computed tomography scan of the chest demonstrating severe right-sided pleural effusion and right lung collapse.

was started on sirolimus 3 mg orally per day, which was tolerated well, apart from the persistent tachycardia. The patient was also placed on total parenteral nutrition for 4 weeks. The patient had an echocardiogram, demonstrating a large mass in the right atrium attached to the anterolateral wall, measuring 14 mm x 11 mm and showing some independent mobility; the mass was suspected to be a potential thrombus. These findings were then confirmed with a cardiac magnetic resonance imaging scan, and the patient was started on enoxaparin. Her tachycardia improved afterward, and a follow-up chest X-ray showed improvement in her pleural effusion; however, persistent small lobulated effusion and shortness of breath were noted.

The patient was seen by the cardiothoracic team, and thoracoscopic evacuation of pleural fluid and thoracic duct clipping was performed to relieve the remainder of the pleural effusion. She then showed almost complete resolution of her pleural effusion and was continued on sirolimus and discharged home with a dermatology follow-up to monitor the treatment.

Discussion

Lymphangiomas are benign, the congenital proliferation of lymphatic vessels that can occur in any area of the body containing lymphatics^[7]. Upon expanding into the thorax, lymphangiomas may cause symptoms via a field effect, as witnessed in DPL. DPL often presents with vague symptoms and nonspecific radiological findings; hence, the diagnosis remains a challenge^[8]. Progressive DPL may lead to chylous effusions and pulmonary damage, as seen in our patient^[8]. CT mainly reveals attenuation of mediastinal fat with thickening of interlobular septa and bronchovascular bundles^[8]. Furthermore, most patients have patchy areas of ground-glass opacities^[9].

There are no standardized treatment guidelines for DPL, owing to its rarity. However, various pharmacological therapies have been tried, including bevacizumab, sildenafil, thalidomide, propranolol, and sirolimus^[10]. Reports utilizing sirolimus in DPL treatment are extremely limited. In Table 2, we have summarized

Table 1
Results of the pleural fluid analysis

Pleural fluid analysis			
Color	Milky	PH	7.6
White blood cell count	3250	Lymphocytes	57%
Red blood cell count	54 000	Adenosine deaminase	6.7
Lactate dehydrogenase	136	Albumin	22
Proteins	37	Triglyceride	> 3.6
Glucose	5.7	Cholesterol	1.5

Table 2

Summary of case reports on the use of sirolimus in the treatment of diffuse pulmonary lymphangiomatosis.

Number	Title	Authors (et al)	Year of publication	Country	Age and sex of the patient	Study design
1	Diffuse pulmonary lymphangiomatosis with pleural and pericardial involvement: Pediatric case report	Moreno et al. ^[11]	June 2021	Italy	22-month-old female	Case Report
2	Diagnosis and treatment of diffuse pulmonary lymphangioma in children: a case report	Sun et al. ^[12]	April 2023	China	8-year-old male	Case Report
3	The successful management of diffuse lymphangiomatosis using sirolimus: a case report	Reinglas et al. ^[13]	August 2011	Canada	4-month-old male	Case Report
4	Effective initial treatment of diffuse pulmonary lymphangiomatosis with sirolimus and propranolol: a case report	Dimiene et al. ^[10]	December 2021	Lithuania	26-year-old male	Case Report
5	Successful treatment of diffuse pulmonary lymphangiomatosis with sirolimus	Gurskytė et al. ^[8]	2020	Lithuania	27-year-old male	Case Report

Note: The search strategy was conducted on PubMed, Google Scholar, and Embase. The search strategy was as follows: ("Lymphangiomatosis" OR "Diffuse pulmonary lymphangiomatosis" OR "DPL") AND ("Sirolimus" OR "Rapamycin") AND ("Treatment" OR "Therapy") AND ("Pleural effusion" OR "Chylothorax") AND ("Case report" OR "Case series").

several case reports that have explored the use of sirolimus in the treatment of DPL, highlighting the study design and primary authors. Dimiene *et al.*^[10] described the case of a 26-year-old man with progressive dyspnea, hemoptysis, and night sweats due to underlying DPL. The authors reported successful treatment with sirolimus and propranolol, which was used to control tachycardia and support treatment by reducing vascular endothelial growth factor levels. Similarly, Gurskytė *et al.*^[8] reported the case of a 27-year-old man who presented with dyspnea, cough, and hemoptysis due to DPL. At 21 months of sirolimus treatment, their patient reported decreased coughing, and a CT scan revealed decreased interstitial thickening.

The major limitation of the present case is the lack of confirmatory pathological findings. Our diagnosis largely relies on the radiological findings of the patient. Additionally, the diagnosis is supported by the rapid response of the patient to sirolimus. Although the incisions needed for DPL are relatively small, the resulting injury often exacerbates the existing chylothorax^[14].

Conclusion

In this article, we reported the case of a patient with pleural effusion due to underlying lymphangiomatosis. Treatment of lymphangiomatosis is not yet standardized and is widely based on case reports and personal experience. However, several reports in the literature have demonstrated positive outcomes with sirolimus. In the present study, sirolimus effectively reduced lymphatic proliferation and relieved the patient of her pleural effusion. Larger studies are needed to confirm our findings.

Ethics approval

Patient consent was provided for the publication of this manuscript and accompanying images.

Consent

Written informed consent was obtained from the patient for publication and any accompanying images. A copy of the written consent is available for review by the Editor-in-Chief of this journal on request.

Sources of funding

This study did not receive funding from any source.

Author contribution

All authors contributed to the research and/or preparation of the manuscript. All authors read and approved the final manuscript.

Conflicts of interest disclosure

The authors declare no conflicts of interest.

Research registration unique identifying number (UIN)

None.

Guarantor

Dr Muhammad Riazuddin.

Data availability statement

All data analyzed are available in the manuscript.

Provenance and peer review

Not commissioned, externally peer-reviewed.

Acknowledgements

None.

References

- [1] Faul JL, Berry GJ, Colby TV, *et al.* Thoracic lymphangiomas, lymphangiectasis, lymphangiomatosis, and lymphatic dysplasia syndrome. *Am J Respir Crit Care Med* 2000;161(3 Pt 1):1037–46.
- [2] Tazelaar HD, Kerr D, Yousem SA, *et al.* Diffuse pulmonary lymphangiomatosis. *Hum Pathol* 1993;24:1313–22.
- [3] Fukahori S, Tsuru T, Asagiri K, *et al.* Thoracic lymphangiomatosis with massive chylothorax after a tumor biopsy and with disseminated intravenous coagulation – lymphoscintigraphy, an alternative minimally invasive imaging technique: report of a case. *Surg Today* 2011;41:978–82.
- [4] Zhang J, Jin H, Wang Y, *et al.* A case of diffuse pulmonary lymphangiomatosis with unilateral lung invasion. *Oxf Med Case Reports* 2015;2015:346–8.
- [5] Hangul M, Kose M, Ozcan A, *et al.* Propranolol treatment for chylothorax due to diffuse lymphangiomatosis. *Pediatr Blood Cancer* 2019;66:e27592.
- [6] Gagnier JJ, Kienle G, Altman DG, *et al.* the CARE Group. The CARE guidelines: consensus-based clinical case reporting guideline development. *J Med Case Rep* 2013;7:223.
- [7] Kadakia KC, Patel SM, Yi ES, *et al.* Diffuse pulmonary lymphangiomatosis. *Can Respir J* 2013;20:52–4.
- [8] Gurskytė V, Zeleckienė I, Maskoliūnaitė V, *et al.* Successful treatment of diffuse pulmonary lymphangiomatosis with sirolimus. *Respir Med Case Rep* 2020;29:101014.
- [9] Swensen SJ, Hartman TE, Mayo JR, *et al.* Diffuse pulmonary lymphangiomatosis: CT findings. *J Comput Assist Tomogr* 1995;19:348–52.
- [10] Dimiene I, Bieksiene K, Zaveckiene J, *et al.* Effective initial treatment of diffuse pulmonary lymphangiomatosis with sirolimus and propranolol: a case report. *Medicina (Kaunas)* 2021;57:1308.
- [11] Moreno RP, Hernández Y, Garrido P, *et al.* Diffuse pulmonary lymphangiomatosis with pleural and pericardial involvement. Pediatric case report. *Arch Argent Pediatr* 2021;119:e264–8.
- [12] Sun X, Lu C, Huang Z, *et al.* Diagnosis and treatment of diffuse pulmonary lymphangioma in children: a case report. *Exp Ther Med* 2023;25:175.
- [13] Reinglas J, Ramphal R, Bromwich M. The successful management of diffuse lymphangiomatosis using sirolimus: a case report. *Laryngoscope* 2011;121:1851–4.
- [14] Fang X, Huang Z, Zeng Y, *et al.* Lymphangiomatosis involving the pulmonary and extrapulmonary lymph nodes and surrounding soft tissue. *Medicine* 2017;96:e9032.