

SHORT REPORT

Impaired stereoacuity due to a lesion in the left pulvinar

Y Takayama, M Sugishita, T Kido, M Ogawa, H Fukuyama, I Akiguchi

Department of Rehabilitation, Tokyo Metropolitan Institute for Neuroscience, Tokyo, Japan
Y Takayama

Department of Cognitive Neuroscience, Research Institute of Logopedics and Phoniatrics, University of Tokyo, Tokyo, Japan
M Sugishita

Department of Neurology, Faculty of Medicine, Kyoto University, Kyoto, Japan
T Kido
M Ogawa
H Fukuyama
I Akiguchi

Correspondence to: Dr Yoshihiro Takayama, Department of Rehabilitation, Tokyo Metropolitan Institute for Neuroscience, 2-6 Musashidai, Fuchu-shi, Tokyo 183, Japan.

Received 13 April 1993 and in revised form 22 July 1993.

Accepted 10 September 1993

Abstract

A right-handed patient with a haematoma in the left pulvinar showed impaired stereoacuity. In contrast with previous reports, he did not show peripheral visual extinction or prolonged reaction times for targets on the side contralateral to the lesion.

(*J Neurol Neurosurg Psychiatry* 1994;57:652-654)

The pulvinar has reached a great size in the evolution of the primates and yet its role in visual processing remains unclear as patients with lesions in the pulvinar or the posterior thalamus have rarely been reported.¹⁻³ We had an opportunity to examine a patient with a lesion in the left pulvinar.

Case report

A 52-year-old right-handed man was admitted to hospital with a sudden onset of headaches. Computed tomography showed a cerebral haemorrhage. He reported that something was wrong with his vision. He was alert and cooperative, and there were no abnormalities in strength, coordination, nor sensation in his face, arms, or legs. Tendon reflexes were normal; plantar responses were flexor. Stance and gait were normal. The remainder of the neurological examination

was normal. He had no signs of aphasia. One week after the onset of headache, his forward digit span was seven. The score of Koh's blocks was full. Hemiparesis and hemisensory disturbances were absent.

MRI (at seven weeks after onset) showed a lesion in the left posterior thalamus, mainly in the left pulvinar (fig 1). Technetium-99m labelled hexamethyl-propylene-amine-oxime (HMPAO) single photon emission CT (SPECT) was performed one week after onset (fig 2). To evaluate the perfusional state of the cerebral cortex, left-right asymmetry indices were calculated between the left and right side values of the radioisotope counts in the frontal and temporoparieto-occipital regions (asymmetry index = (mean counts on left side - mean counts on right side / mean counts on right side) × 100%). The asymmetry index of the temporoparieto-occipital region was -17.61%, whereas that of the frontal region was 0.75%, which suggests hypoperfusion in the left temporoparieto-occipital region.

EYE POSITION AND OCULAR MOVEMENTS

Three weeks after onset there was no ocular palsy and no displacement of eye position as determined by the Hess test. The cover-uncover test revealed no strabismus.

VISUAL FIELD

No visual field defect was revealed by Goldmann perimetry three weeks after onset.

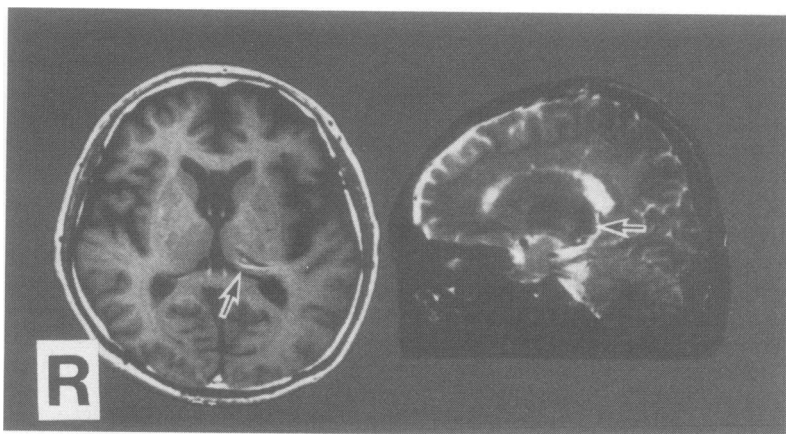


Figure 1 Left panel: T1-weighted axial MRI showing mixed intensity lesion (arrow) in the left pulvinar. Right panel: T2-weighted sagittal MRI showing low intensity lesion (arrow) in the left pulvinar.

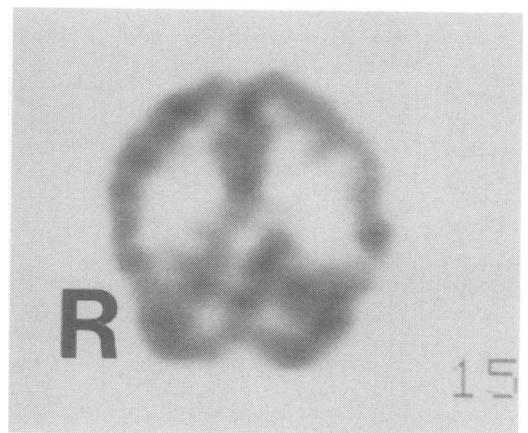


Figure 2 Coronal SPECT images showing hypoperfusion of the left temporal and parietal lobes.

VISUAL ACUITY

Three weeks after onset the patient's distant visual acuity was 1.5 in each eye. Near vision was measured using a single Landolt test card for near point. His near-visual acuity was 0.7 in each eye.

STEREOACUITY

The patient's job was to manipulate a crane. He used to crane blocks to a stand of 1 m width located 20 m away, which needs a stereoacuity of 32 seconds of arc in calculation. He had difficulty in doing the same job with the same accuracy five weeks after the onset of symptoms. Vision for manipulating the crane correctly mainly depends on stereoacuity, though other depth and distance cues may contribute to it. These are movement parallax, linear perspective, texture gradient, overlapping, retinal size, and retinal perspective.⁴ The patient did not notice any impairment when looking at pictures or when looking out from a moving car. There was no evidence of any size or depth impairment other than stereoacuity, indicating that he had a good stereoacuity before the insult and that his impaired stereoacuity is related to the present illness.

Stereoacuity was evaluated using the New Stereo test.⁵ Stereograms with disparity values ranging from 800 to 40 seconds of arc were viewed at a distance of 40 cm. Each stereogram contains four squares. Only one of them has a degree of disparity. When observed through red-green glasses, this square appears in front of or behind the others. Stereoacuity ≥ 200 seconds of arc is considered to be evidence of inadequate stereoacuity.⁶ At least four trials were given at each disparity level and testing continued until two errors were made at one disparity level. At one week after onset the patient's stereoacuity was 800 seconds of arc; at three weeks, 800; at five weeks, 400; at eight weeks, 200; at 10 weeks, 120; at 13 weeks, 80; at 15 weeks, 60 seconds of arc.

VISUAL EXTINCTION

At three weeks after onset the patient was seated 57 cm in front of a screen. Fixation was maintained on a red spot. Targets were presented tachistoscopically for 2 ms at 20° eccentricity in the left or right (unilateral condition) or in the left and right (bilateral simultaneous condition) visual half-field. The patient was instructed to indicate whether he saw one (on the left or right side) or two light stimuli. He successfully completed all 24 trials (unilateral condition, 12 trials; bilateral condition, 12 trials)—he did not show a peripheral visual extinction.

VISUAL SPATIAL ATTENTION

At three weeks after onset the patient was seated 57 cm in front of a 13 in computer screen and keyboard. Using the right hand he was asked to press the space key as fast as possible when an asterisk appeared 4° to the right or left of the fixation point. His reaction time was measured. A total of 40 trials was

performed. The mean (SD) result for his right visual field was 391 (36) ms and for the left visual field 406 (40) ms. There was no significant difference between visual hemifields. He did not show prolonged reaction times for targets on the side contralateral to the lesion.

UNILATERAL SPATIAL NEGLECT

At one week after onset the patient showed no unilateral spatial neglect by line bisection task, cancellation task, and copying task.

JUDGMENT OF LINE ORIENTATION

At one week after onset the patient was required to point to which one of nine lines matched the orientation of a target line presented tachistoscopically to central vision for 17 ms. The line was 2 cm long and the distance to the screen was 57 cm. He performed this task without error (28/28).

COLOUR PERCEPTION

At one week after onset the patient showed a normal pattern on Ishihara tests for colour blindness.

Discussion

Our patient showed an impairment of stereoacuity. Diplopia, eye movement disorders, strabismus, visual field defect, or unilateral spatial neglect may be a contributory factor in impaired stereoacuity⁶⁻⁸; these were not shown, however. It is also required to have a good near-visual acuity for good stereoacuity. Hamsher⁶ stated that subjects should have a near-visual acuity better than 20/70 in each eye; our patient passed this criterion. Depth cues other than horizontal retinal disparity adequately compensate for their defect in stereoacuity, and varying degrees of stereoscopic abnormality are found in a certain proportion of the "normal" population. It is therefore necessary to know the baseline stereoacuity of the patient. Fortunately, our patient had a good stereoacuity before the insult.

Many workers have attempted to study the possible contribution of the various regions of the cerebral hemisphere to stereoacuity.⁶⁻¹¹ Little attention has been focused on the subcortical structures, however. Anatomical studies have shown interconnections between the visual cortical areas and the pulvinar, suggesting that the pulvinar may have some visual functions. The results for our patient indicate that the lesion in his pulvinar is related to impaired stereoacuity. There is some support for this from experimental studies. Casanova *et al*¹² reported that most of the cells in the pulvinar are binocular and sensitive to relative retinal disparity, and these cells may be a substrata for binocular depth perception. Veraart¹³ reported that the pulvinar neurons may intervene in stereoscopic perception in cats. The pulvinar may integrate its inputs and be involved in functions such as stereoacuity which go beyond those of a simple thalamic relay. There are other pos-

sible hypotheses. Analyses of sites of cortical lesions among the reported cases of impaired stereoacuity and experimental studies suggest that lesions within a region centred on the posterior parietal lobe and extending into surrounding occipital and temporal gyri are implicated in the production of impaired stereoacuity.⁶⁻¹¹ Rothstein and Sacks¹⁰ emphasised the importance of the left parietal lobe in stereoacuity. The pulvinar has been suggested to serve as a relay of the extrageniculate pathway to the extrastriate areas such as the parietal or temporal lobe. Extrageniculate information may be necessary for stereoacuity. Impaired stereoacuity may occur because of the disruption of the extrageniculate pathway to these areas. There is another explanation relating to the cortical function. The SPECT images for this patient show low perfusion in the left temporoparieto-occipital region, probably due to the remote effect of the left pulvinar lesion. Whether such low perfusion can be interpreted in terms of impaired stereoacuity remains conjectural; however, hypofunction of the left temporoparieto-occipital region, not damage of the pulvinar itself nor disrupted extrageniculate information, might contribute to impaired stereoacuity. The patient's impaired stereoacuity improved during the course of his illness. An intact right pulvinar may compensate for the function of the damaged left pulvinar. The left temporoparieto-occipital region may use the contralateral extrageniculate information. The hypofunction of the left temporoparieto-occipital region may recover.

Patients with lesions in the pulvinar or posterior thalamus have rarely been reported. Zihl and Von Cramon¹ reported a patient with a lesion incorporating the left pulvinar. The patient's detection performance for bilateral stimuli was decreased beyond 20° peripheral eccentricity. The patient showed a "neglect" for the periphery of the contralateral visual half-field. That was a visual extinction of the peripheral visual field. Rafal and Posner² reported that three patients with posterior thalamic lesions showed prolonged

reaction times for targets on the side contralateral to the lesion. Referring to this and other studies, Robinson and Peterson³ claimed that the pulvinar is implicated in visual attention or salience. Though the tests used here were not identical to those used by Zihl and Von Cramon¹ and Rafal and Posner,² these findings were not demonstrated in our patient. The patient of Zihl and Von Cramon¹ had lesions in the left pulvinar and also in the left temporoparietal region. Two of three patients of Rafal and Posner² had lesions affecting large parts of the thalamus including the pulvinar and the other patient had a lesion in the posterior thalamus but not clearly affecting the pulvinar. Our patient had a relatively restricted lesion in the left pulvinar and he did not show a "neglect" for the periphery of the contralateral visual half-field or prolonged reaction times for targets on the side contralateral to the lesion. Restricted pulvinar lesion may not be enough to produce the peripheral visual extinction or deficits in visual spatial attention.

- 1 Zihl J, Von Cramon D. The contribution of the second visual system to directed visual attention in man. *Brain* 1979;102:835-56.
- 2 Rafal RD, Posner MI. Deficits in visual spatial attention following thalamic lesions. *Proc Natl Acad Sci USA* 1987;84:7349-53.
- 3 Robinson DL, Petersen SE. The pulvinar and visual salience. *Trends Neurosci* 1992;15:127-32.
- 4 Oyama T. Visual perception. In: Tasaki K, Ogawa T, eds. *Handbook of physiological sciences*. Vol.9. *Sensory physiology* [in Japanese]. Tokyo: Igaku-Shoin, 1989:61-76.
- 5 Awaya S. *New Stereo Tests*. Tokyo: Handaya, 1988.
- 6 Hamsher KS. Stereopsis and unilateral brain disease. *Invest Ophthalmol Vis Sci* 1978;17:336-43.
- 7 Danta G, Hikton RC, O'Boyle DJ. Hemisphere function and binocular depth perception. *Brain* 1978;101:569-89.
- 8 Ross JE. Disturbance of stereoscopic vision in patients with unilateral stroke. *Behav Brain Res* 1983;7:99-112.
- 9 Durnford M, Kimura D. Right hemisphere specialization for depth perception reflected in visual field differences. *Nature* 1971;231:394-5.
- 10 Rothstein TB, Sacks JA. Defective stereopsis in lesions of the parietal lobe. *Am J Ophthalmol* 1972;73:281-4.
- 11 Cowey A. Disturbance of stereopsis by brain damage. In: Ingle DJ, Leannero M, Lee DN, eds. *Brain mechanisms and spatial vision*. Boston: Nijhoff, 1985:259-78.
- 12 Casanova C, Nordmann JP, Molotchnikoff S. Le complexe noyau latéral postérieur-pulvinar des mammifères et la fonction visuelle. *J Physiol (Paris)* 1991;85:44-57.
- 13 Veraart C. La perception stéréoscopique. Intervention probable des neurones du pulvinar chez le chat. *Acta Neurol Belg* 1977;77:41-50.