

SHORT REPORT

Benign intracranial hypertension: a cause of CSF rhinorrhoea

D Clark, P Bullock, T Hui, J Firth

Abstract

Four patients undergoing treatment for benign intracranial hypertension presented with spontaneous CSF rhinorrhoea. The four patients, all women, were aged between 33 and 44 years. They had been receiving treatment for benign intracranial hypertension for a period ranging from eight months to 11 years, before developing the CSF leak. There was no history of previous head injury and there were no congenital anomalies of the floor of the anterior fossa. The site of the CSF fistula was localised to the cribriform plate in all four cases. The pathophysiology of the CSF rhinorrhoea and the surgical management of this group of patients are discussed. The authors propose that benign intracranial hypertension should be included in the classification of high pressure CSF leaks.

(*J Neurol Neurosurg Psychiatry* 1994;57:847-849)

Neurosurgical Unit,
University Hospital,
Queen's Medical
Centre, Nottingham,
UK

D Clark
P Bullock
T Hui
J Firth

Correspondence to:
P Bullock, Department of
Neurosurgery, The
Maudsley Hospital,
Denmark Hill, London
SE5 8AZ, United Kingdom.

Received 8 September 1992
and in revised form
28 September 1993.
Accepted 9 November 1993

Ommaya's original classification of high pressure CSF leaks did not include benign intracranial hypertension.¹ He described tumours and untreated hydrocephalus as the most common causes of this condition. He speculated on a third group such as benign intracranial hypertension with chronically raised pressure "placing the fragile roof of the nose at risk" and leading to rhinorrhoea, but he had not witnessed such a case. Since Ommaya's classification, several authors describing the surgical repair of CSF leaks have included patients with benign intra-

cranial hypertension.²⁻⁵ In this paper the mechanisms by which a CSF leak can occur are discussed, as well as the difficulties that may be encountered in securing a direct repair of the CSF fistula. The distinction between high and low pressure CSF leaks is emphasised because it is usually important to treat the underlying cause of the high pressure, before a satisfactory repair of the CSF leak can be effected.

Patients and methods

Four patients who were treated for benign intracranial hypertension at the Neurosurgical Department, University Hospital, Nottingham between 1986 and 1990 are described (table). The four women were aged between 33 and 44 years, and had been diagnosed as having benign intracranial hypertension, receiving treatment for a period ranging from eight months to 11 years, before developing CSF rhinorrhoea. All the patients had complained of the classic symptoms of headache and visual disturbance, and were found to have papilloedema at the time of the original presentation. Neurological examination was normal. Diagnosis was by exclusion with a normal CSF under elevated pressure. All patients had CT and MRI scans as well as cerebral angiography to exclude other disorders.

The initial medical management was by lumbar puncture, weight reduction, diuretics, and steroids. Patients referred for surgery had progressive visual loss or had failed to improve with medical therapy. Once the CSF leak had been diagnosed the site of the fistula was identified in each case by CT scan with fine coronal cuts. The fistulas were all discovered in the region of the cribriform plate and no congenital anomalies of this area were identified.

CASE 1

This 33-year-old female with resistant benign intracranial hypertension developed a CSF rhinorrhoea while on the waiting list for a lumboperitoneal shunt. The CSF leak resolved after insertion of the shunt. Six months later the CSF rhinorrhoea recurred and the shunt was found to be blocked.

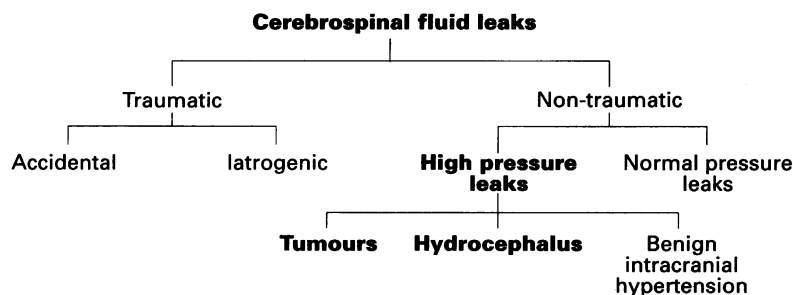


Figure 1 Causes of CSF leaks.

Initial presentation and treatment

Patient no.	Sex	Age (years)	Symptoms and signs	Investigations		
				CT scan	CSF pressure (cmH ₂ O)	Initial treatment
1	Female	33	Headaches Double vision Gross papilloedema Enlarged blind spots	Normal: small ventricles	30	Multiple lumbar punctures Diuretics Steroids Weight reduction
2	Female	44	Headaches Obscuration Papilloedema Dizzy spells	Normal: normal ventricle size	34	Multiple lumbar punctures Steroids
3	Female	42	Papilloedema Enlarged blind spots	Normal: normal ventricle size	34	Multiple lumbar punctures Acetazolamide
4	Female	34	Headaches Blurred vision Enlarged blind spots	Normal: small ventricles	30	Steroids Multiple lumbar punctures Thecoperitoneal shunt

Revision of the shunt has been partially successful with the patient still experiencing intermittent CSF rhinorrhoea and occasional headaches. The patient had no papilloedema or visual disturbance on review at one year follow up, and she has declined any further intervention.

CASE 2

A 44-year-old female had been treated for benign intracranial hypertension for 19 months before developing CSF rhinorrhoea. Primary closure of the CSF fistula by craniotomy was attempted but frustrated by raised intracranial pressure. A lumboperitoneal shunt was inserted producing resolution of both the rhinorrhoea and symptoms and signs of benign intracranial hypertension. However, following the shunt insertion the patient complained of low pressure headaches which persisted, and the shunt had to be occluded. At followup she remained symptom-free with no recurrence of the CSF leak, presumably as a result of spontaneous resolution of the benign intracranial hypertension.

CASE 3

This 42-year-old female had been treated for benign intracranial hypertension for more than four years before developing CSF rhinorrhoea. Primary repair of the CSF fistula was undertaken by a craniotomy using an extradural approach. At operation, the intracranial pressure was high but the repair

was accomplished. After the operation the patient was treated with a lumbar CSF drain which was continued for five days. She has remained symptom-free five years after this procedure.

CASE 4

A 34-year-old patient had a lumboperitoneal shunt inserted as treatment for her resistant benign intracranial hypertension. Six years after this procedure the patient developed a CSF rhinorrhoea, and the shunt was found to have migrated and not be functioning. She subsequently underwent multiple shunt revisions and the CSF rhinorrhoea resolved; she then developed an intracranial aerocele (fig 2). At this point a craniotomy was undertaken to repair the site of the fistula directly. At a six month followup there had been no further CSF rhinorrhoea and the aerocele had resolved.

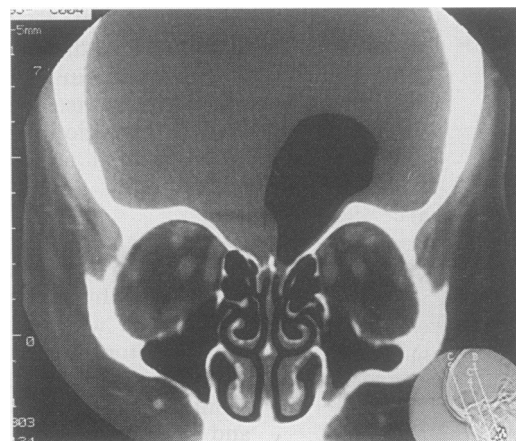
Discussion

Benign intracranial hypertension most commonly affects women of child bearing age and is usually a self limiting condition. Most patients are managed successfully by non-surgical methods. A shunting procedure or optic nerve decompression may be required to control papilloedema in refractory cases.^{6,7} The association between benign intracranial hypertension and spontaneous CSF rhinorrhoea is rare.

These four female patients illustrate the more severe form of benign intracranial hypertension. They had all received maximum medical treatment and two had described symptoms for over four years. There were no other unusual or unique features which could help to identify other patients with benign intracranial hypertension at risk of developing a CSF leak.

It appears that the raised intracranial pressure was the only aggravating condition. Trauma and congenital anomalies had been excluded. The actual mechanism by which benign intracranial hypertension may precipitate a CSF leak is unclear. Locke⁸ proposed that the exaggerated CSF pulsatile flow, seen with all forms of raised intracranial pressure, could lead to expansion and eventual rupture of the arachnoid sleeve surrounding

Figure 2 Intracranial aerocele post lumboperitoneal shunt.



the olfactory filaments which pass through the pits in the cribriform plate.

It could also be speculated that the empty sella syndrome, which has been reported in association with benign intracranial hypertension, may allow the transmission of the increased CSF pulsation through the incompetent diaphragma sellae, thereby eroding the sella and eventually leading to a CSF leak from this site.^{3,9}

Six other patients with benign intracranial hypertension who developed spontaneous CSF leaks have previously been included in surgical reports on the treatment of non-traumatic CSF rhinorrhoea.²⁻⁵ These six patients have a similar age distribution, sex, and mode of presentation to the four patients described here. The cribriform plate was the site of CSF leak in five of the patients and Bejerre *et al*³ described one patient who developed a leak from the sella turcica. From these two groups of patients, it would appear that the cribriform plate and the sella region are the most common sites for the development of a high pressure CSF leak.

In this study the site of the CSF fistula was adequately demonstrated by coronal CT scans in all four patients, but if this investigation is unrewarding, evaluation by metrizamide CT cisternography or CSF radioactive isotope tracer studies has been recommended.^{4,10}

It is of interest that, during this study, no patients' vision deteriorated after development of the CSF leak, but high pressure CSF rhinorrhoea rarely stops of its own accord and places the patient at risk of meningitis. Surgical repair was therefore recommended to prevent this complication.

It is usually important to treat the underlying cause of the high pressure before a satisfactory repair of the CSF leak can be undertaken. A lumboperitoneal shunt has proved useful in controlling the raised intracranial pressure in benign intracranial hypertension. However, the fistula may not heal completely after a shunting procedure alone, and the patient may be exposed to an increased risk of infection because the gradient across the fistula has been reversed. Eljamel and Foy⁴ reported this complication in a patient who developed meningitis after receiving a lumboperitoneal shunt for CSF rhinorrhoea. Indeed, two patients in this study presented with a recurrent CSF rhinorrhoea as a result of shunt failure. One patient (case 4) had an acute exacerbation of her headaches after blowing her nose and was discovered to have an extensive pneumocephalus (fig 2). This is further evidence that

the fistula may not close spontaneously after the shunting procedure.

In practice direct repair of the CSF fistula was found to be difficult, when no shunting procedure had previously been carried out. Two of the four patients who underwent craniotomy as the initial procedure had the intracranial pressure reported as "bursting" at operation, in spite of determined hyperventilation and other measures. One of these operations was abandoned before the repair could be effected; the other was successfully completed following the insertion of an external lumbar CSF drain. Once the intracranial pressure has been controlled by inserting a lumboperitoneal shunt, the site of the fistula can be approached directly and a repair undertaken, using either intracranial or extracranial approaches. Extracranial techniques have, however, been more recently described for repair of both the sella and cribriform regions, and are reported to carry a reduced morbidity in comparison with the intracranial repair.¹¹

In conclusion CSF rhinorrhoea is a rare complication of benign intracranial hypertension. The cribriform plate, followed by the sella turcica, are the most frequent sites of CSF fistula formation. The shunting procedure may control the benign intracranial hypertension and the CSF rhinorrhoea, but to exclude the risk of later meningitis and pneumocephalus, a direct repair of the fistula is also recommended.

- 1 Ommaya AK. Cerebrospinal fluid rhinorrhoea. *Neurology* 1964;27:214-6.
- 2 Brisman R, Hughes JEO, Mount LA. Cerebrospinal fluid rhinorrhoea. *Arch Neurol* 1970;22:245-52.
- 3 Bjerre P, Lindholm J, Glydensted C. Pathogenesis of non-traumatic cerebrospinal fluid rhinorrhoea. *Acta Neurol Scand* 1982;66:180-92.
- 4 Eljamel MSM, Foy PM. Non-traumatic CSF fistulae: clinical history and management. *Br J Neurosurg* 1991; 5:275-9.
- 5 Tolley NS, Brookes GB. Surgical management of cerebrospinal fluid rhinorrhoea. *J R Coll Surg Edinb* 1992; 37:12-5.
- 6 Johnson I, Besser M, Morgan MK. Cerebrospinal fluid diversion in the treatment of benign intracranial hypertension. *J Neurosurg* 1988;69:195-202.
- 7 Kelman SE, Heaps R, Wolf A, Elman MJ. Optic nerve decompression surgery improves visual function in patients with pseudotumour cerebri. *Neurosurgery* 1992; 30:391-5.
- 8 Locke CE. The spontaneous escape of cerebrospinal fluid through the nose. *Arch Neurol Psychiatry* (Chicago) 1926;15:309-24.
- 9 Weisberg LA, Housepian EM, Saur DP. Empty sella syndrome as complication of benign intracranial hypertension. *J Neurosurg* 1977;43:177-80.
- 10 Ahmade J, Weiss MH, Segall HF, Schultz DH, Lee CS, Giennotta SL. Evaluation of cerebrospinal fluid rhinorrhoea by Metrizamide computed tomographic cisternography. *Neurosurgery* 1985;16:54-60.
- 11 Hubbard JL, McDonald TJ, Pearson BW, Laws ER. Spontaneous cerebrospinal fluid rhinorrhoea. Evolving concepts in diagnosis and surgical management from 1970 through 1981. *Neurosurgery* 1985;16:314-21.