

SHORT REPORT

Rest tremor and extrapyramidal symptoms after midbrain haemorrhage: clinical and ^{18}F -dopa PET evaluation

Gilles-Louis Defer, Philippe Remy, Denis Malapert, Frédéric Ricolfi, Yves Samson, Jean-Denis Degos

Abstract

A 25 year old man had an acute sub-arachnoid haemorrhage due to the rupture of a right peduncular subthalamic arteriovenous malformation. Seven months later he developed a left rest tremor associated with mild bilateral extrapyramidal symptoms and responsive to levodopa treatment. Surface EMG recording showed synchronous activity of agonist and antagonist muscles in the left limbs. A PET ^{18}F -dopa study showed a large decrease of the Ki value in the right striatum. One year after the stroke a persistent postural component developed in the tremor.

(*J Neurol Neurosurg Psychiatry* 1994;57:987-989)

A tremor associated with damage to the upper part of the brain stem ("midbrain" tremor) has been noted in head injury¹⁻³ or vascular lesions.⁴⁻⁶ Despite some variability in their clinical presentation, these tremors are mainly postural, often associated with an

intentional component, sometimes prominent,^{2,3} and in some cases with a rest component.^{1,6} The rest component of midbrain tremor, and its sensitivity to levodopa treatment, have led to consideration of the role of a lesion of the nigrostriatal pathway in its occurrence.⁵ We describe here a patient who developed a rest tremor and parkinsonian symptoms after a unilateral midbrain haemorrhage.

Case report

A 25 year old man, without peculiar medical history, presented with a severe headache immediately followed by a left hemiplegia associated with a paresis of the right cranial nerve III. These symptoms were related to a subarachnoid haemorrhage due to rupture of an arteriovenous malformation, shown by angiography to be located within the right peduncular subthalamic and thalamic areas. The patient's neurological state improved, allowing him to start working again. Seven months after his stroke, however, he complained of a worsening left tremor. Examination found slight left pyramidal symptoms and a rest tremor on the left side. This tremor was regular, of large amplitude, and exacerbated by the patient's use of arithmetic. Occasionally he was able to stop it. No tremor occurred during sleep. The tremor was distal and more prominent in the leg, with a movement of flexion-extension of the foot while the patient was seated. During voluntary movement the tremor in the left arm disappeared. The patient was able to take a pen in front of him slowly between the thumb and forefinger without any tremor. Examination disclosed slight bradykinesia and bilateral extrapyramidal rigidity, prevailing on the left side and increased by contralateral voluntary movement; there was no palatal tremor.

Surface EMG recording showed no resting tremor in the left proximal muscles. Tremor recording disclosed synchronous activity of agonist and antagonist muscles in the arm and leg (fig 1). The greatest amplitude was found in the tibialis anterior of the lower limb and in the triceps brachii of the upper limb. Tremor was slightly slower in the arm than in the leg (3.5 Hz *v* 4 Hz). No tremor was detected when the patient stretched out his

Département de Neurosciences, Service de Neurologie, Hôpital Henri Mondor, 9400-Créteil, France
G-L Defer
D Malapert
F Ricolfi
J-D Degos
Service Hospitalier Frédéric Joliot, DRIPP CEA, Orsay 91401 cédex, France
P Remy
Y Samson

Correspondence to: Dr Gilles-Louis Defer, Département de Neurosciences, Service de Neurologie, Hôpital Henri Mondor, 94000-Créteil, France.

Received 23 August 1993 and in revised form 30 December 1993. Accepted 12 January 1994

Figure 1 Surface EMG recording showing synchronous activation of antagonist muscles. (A) Upper trace is biceps brachii, lower trace is triceps brachii; (B) Upper trace is tibialis anterior, lower trace is gastrocnemius. Each trace represents one second of recording. Calibration: upper trace (A) = 0.1 mV; lower trace (A) and upper and lower traces (B) = 0.5 mV

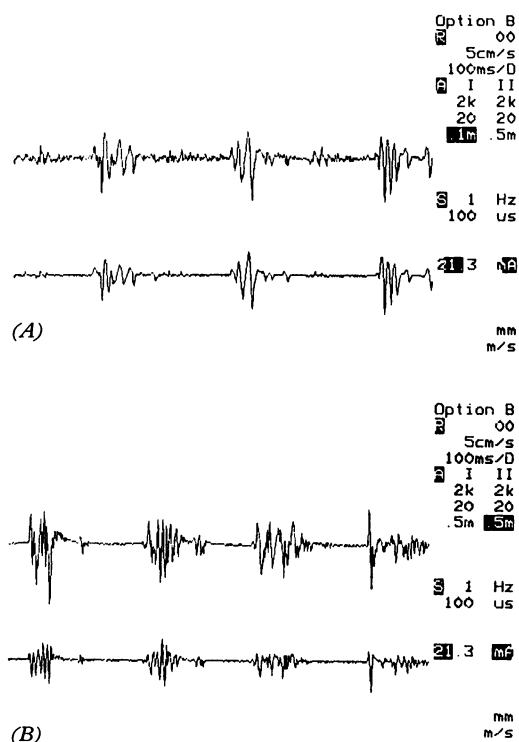
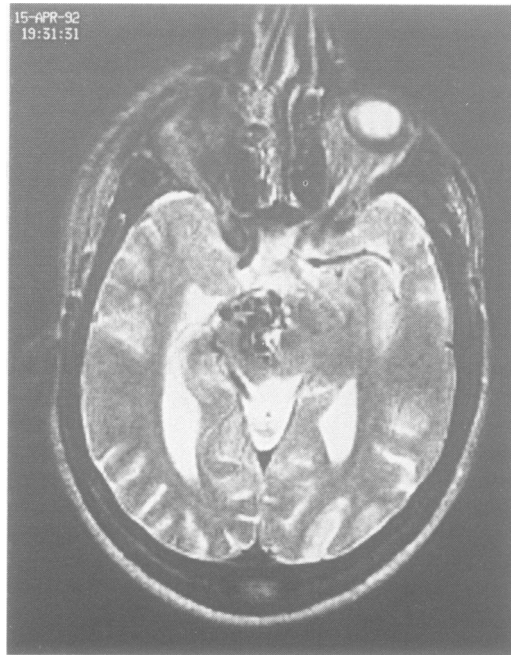


Figure 2 Axial T2 weighted image (TR: 2500 ms/TE: 90 ms): Serpiginous flow signal void of the arteriovenous malformation is located in the right midbrain area. Notice the normal hyposignal intensity of the red nucleus and substantia nigra on the left side.



left arm. A dose of 200 mg of levodopa reduced the tremor after 90 minutes, and improved finger dexterity and pronosupination speed. Improvement of the rest tremor was obtained with levodopa (500 mg/day) and piribedil (300 mg/day) was even more efficient. MRI showed that haemorrhage had involved the right superior cerebellar peduncle, red nucleus, and substantia nigra and had spared these structures on the left side (fig 2). No abnormality was seen at the striatum level.

A PET study was performed after written consent, with a high resolution tomography (ECAT 953B, CTI, Knoxville, TN, USA). The patient took no medication at the time of the PET. The values of the Ki constant, representing ^{18}F -dopa uptake, were determined in the caudate and putamen by a multiple time graphical analysis, with occipital values as input.⁷

The Ki values were lower in the right than in the left caudate (0.0033 v 0.0074 min^{-1} respectively) and in the right than in the left putamen (0.0008 v 0.0091 min^{-1} respectively). The Ki values in the right side were far below the control values (nine males, two females, mean age 36.4 (SD 16) years; caudate 0.0096 (0.0017) min^{-1} ; putamen 0.0100 (0.0014) min^{-1}) and in the range of values of a series of patients with parkinsonism (seven men, four women, mean age 57.3 (6.7); caudate 0.0057 (0.0015) min^{-1} ; putamen 0.0032 (0.0016) min^{-1}) obtained in our institution on the same tomograph and with the same methodology.

During five months while the patient received levodopa treatment, the tremor changed, with the occurrence of a postural component that increased progressively. This component looked like a prolongation of the unchanged rest tremor, that was maintained or increased during movement, resulting in inconvenience in performing activities of daily

living. At this time the patient was treated by multibeam radiation for his arteriovenous malformation and since then the tremor has not changed.

Discussion

Most descriptions of midbrain tremors are related to post-traumatic lesions, often haemorrhagic.^{2,3,6} Post-traumatic tremors are mainly postural and action tremors,^{1-3,6} although in three of the eight patients described by Andrew *et al* an associated rest component was found that disappeared after thalamotomy.¹ Findley and Gresty⁵ described a 51 year old male patient who had a subarachnoid haemorrhage related to an arteriovenous malformation arising from the tip of basilar artery. Six weeks later he developed a severe tremor at rest that persisted and increased during voluntary movement and posture. This tremor was greatly improved by levodopa treatment.⁵ Fahn *et al* reported a 54 year old woman who developed a tremor of the right arm two months after acute right hemiparesis. The tremor was variable in its amplitude at rest and severely exaggerated by postural holding of the arm and the finger to finger manoeuvre. MRI showed a haemorrhage in the left subthalamic area and rostral lateral part of the red nucleus. Levodopa had no effect and lorazepam led to some improvement of the movement disorder.⁴

In our patient a tremor at rest occurred seven months after his stroke. It is interesting that there was a delay between midbrain injury and the occurrence of a tremor in all cases of traumatic and non-traumatic midbrain tremor.¹⁻⁶ This delay was variable but could be compared to the occurrence of delayed dystonia after hemiplegia associated with lesions in the basal ganglia.⁸ In primates motor impairments were found in the postoperative period after unilateral 6-hydroxydopamine lesion of the substantia nigra.⁹ Specifically, significant increases in reaction time and movement time in the contralateral hand were seen from the 10th day and they were maximum between the 20th and 30th days after the lesion.⁹ Direct comparison between such experimental studies and clinical data is difficult. It is interesting, however, that an acute and precise limited chemical lesion of the substantia nigra is able to induce a delayed movement modification that is related to a persistent dopaminergic deficit.⁹ We suggest, therefore, that our patient's diffuse midbrain lesion (haemorrhage not limited to the substantia nigra) was not able to induce immediate extrapyramidal symptoms but that the dopaminergic neuron loss was sufficient to induce delayed parkinsonian manifestations.

The rest tremor had the clinical characteristics of parkinsonian tremor, and was improved by levodopa treatment and piribedil. The clinical efficiency of levodopa on posthaemorrhagic midbrain tremors has been reported.^{3,5} In most cases, however, this kind of treatment was not tried. After five

months of evolution the tremor changed in appearance with the occurrence of a postural component. Levodopa treatment was efficient, however at lessening both resting and postural components of the tremor.

Clinical features make parkinsonian rest tremor and postural cerebellar tremor clearly distinct. In both conditions EMG recordings, however, classically show alternating muscle activity.¹⁰ Although our patient had initially a pure rest tremor, EMG recording showed a simultaneous agonist-antagonist muscle activity. Other workers have found that the pattern of EMG activity in parkinsonian patients could be either synchronous or alternating in both postural and resting tremor.¹¹ Few papers have reported the results of EMG study in postural cerebellar tremor after midbrain injury,³ but by contrast with our case rhythmical alternating activity was found. Therefore midbrain tremor cannot be defined simply by a schematic clinical and EMG presentation.

As well as the resting tremor our patient had mild bilateral extrapyramidal symptoms. MRI showed no lesion of the left substantia nigra (fig 2) and PET data were within the normal range for the left striatum. Crossed nigrostriatal connections have been found in monkeys and rats.¹² Moreover, bilateral interactions between basal ganglia motor systems are now well established.¹³ These data could provide an explanation for the bilateral extrapyramidal symptoms in our patient.

In the discussion of the case of Fahn *et al.*⁴ Koller¹⁸ underlines that "if the resting tremor component is due to nigrostriatal damage, this hypothesis could be tested by a PET quantifying striatal dopamine function." In our patient the PET ¹⁸F-dopa study showed a large decrease in the Ki value in the right striatum. Few reports have described such an investigation after midbrain lesions. Leenders *et al.*¹⁴ showed a decrease of ¹⁸F-dopa uptake in the contralateral striatum of a patient with a progressive right hemidystonia and parkinsonism due to a calcified rostral brainstem-thalamic lesion. Recently De Recondo *et al.*⁶ reported similar PET results in a young

woman who developed a postural tremor increased during voluntary movement, associated with a rest component, two months after a right midbrain post-traumatic haematoma. The PET study in our patient strongly suggests that rest tremor related to midbrain lesions is associated with a contralateral decrease in striatum ¹⁸F-dopa uptake, whatever the aetiology of the tremor.

We thank Drs Philippe Decq and Cecile Le Pêchoux for their technical assistance. We are grateful to Professor Mark Hallett (Bethesda) for reviewing the manuscript and for his enlightened suggestions.

- Andrew J, Fowler CJ, Harrison MJG. Tremor after head injury and its treatment by stereotaxic surgery. *J Neurol Neurosurg Psychiatry* 1982;45:815-9.
- Biary N, Cleaves L, Findley L, Koller WC. Post traumatic tremor. *Neurology* 1989;39:103-6.
- Reza Samie M, Selhorts JB, Koller WC. Post-traumatic midbrain tremors. *Neurology* 1990;40:62-6.
- Fahn S, Koller WC, Hallett M. What is it? *Mov Disord* 1986;1:299-308.
- Findley LJ, Gresty MA. Suppression of "rubral" tremor with levodopa. *BMJ* 1980;281:1043.
- De Recondo A, Rondot P, Loc'h C, *et al.* Etude du système dopaminergique en tomographie par émission de positrons dans un cas de tremblement unilatéral secondaire à un hématome mésencéphalique. *Rev Neurol* 1993;149:46-9.
- Patlak CS, Blasberg RG. Graphical evaluation of blood-to-brain transfer constants from multiple-time uptake data. Generalizations. *J Cereb Blood Flow Metab* 1985;5:584-90.
- Pettigrew LC, Jankovic J. Hemidystonia: a report of 22 patients and a review of the literature. *J Neurol Neurosurg Psychiatry* 1985;48:650-7.
- Viallet F, Trouche E, Nieoullon A, Beaubaton D, Legallet E. Unilateral electrolytic and 6-OHDA lesions of the substantia nigra in baboons: behavioural and biochemical data. In: McKenzie JS, Kemm RF, Wilcock LN, eds. *The basal ganglia: structure and function*. New York: Plenum press, 1984.
- Hallett M. Differential diagnosis of tremor. In: Vinken PJ, Bruyn GW, eds. *Diseases of the basal ganglia. Handbook of clinical neurology*. Amsterdam: North-Holland Publishing Co, 1985:583-95.
- Andrews CJ, Burke D, Lance JW. The comparison of tremors in normal, parkinsonian and athetotic man. *J Neurol Sci* 1973;19:53-61.
- Fass B, Butcher LL. Evidence for a crossed nigrostriatal pathway in rats. *Neurosci Lett* 1981;22:109-13.
- Barbeito L, Girault JA, Godeheu G, Pittaluga A, Glowinski J, Chéramy A. Activation of the bilateral corticostriatal glutamatergic projection by infusion of GABA into thalamic motor nuclei in the cat: an in vivo release study. *Neuroscience* 1989;28:365-74.
- Leenders KL, Frackowiak RSJ, Quinn N, Brooks D, Summer D, Marsden CD. Ipsilateral blepharospasm and contralateral hemidystonia and parkinsonism in a patient with a unilateral rostral brainstem-thalamic lesion: structural and functional abnormalities studied with CT, MRI, and PET scanning. *Mov Disord* 1986;1:51-8.