

SHORT REPORT

Optic nerve sheath decompression for the treatment of visual failure in chronic raised intracranial pressure

J F Acheson, W T Green, M D Sanders

Abstract

The records of all patients undergoing optic nerve sheath decompression for visual failure in chronic raised intracranial pressure performed over a 15 year period have been reviewed. The aim was to study the visual outcome and relation to any shunting procedures. Fourteen patients (20 eyes) were identified in whom follow up information of at least one year was available. Eleven patients had benign intracranial hypertension (idiopathic intracranial hypertension) and three had dural venous sinus occlusive disease. Eight patients had unilateral surgery and six had bilateral surgery. Visual acuity and fields either improved or stabilised in 17 out of 20 eyes and three deteriorated. Of the eight patients undergoing unilateral surgery, the other eye remained stable in seven and deteriorated in one. Four patients required optic nerve sheath decompression despite previous shunting or subtemporal decompression. Five patients required shunts or subtemporal decompression after optic nerve sheath decompression because of persistent headache in three cases and for uncontrolled visual failure in two cases. No patients lost vision as a direct consequence of surgery. It is concluded that optic nerve sheath decompression is a safe and important therapeutic option in the management of chronic raised intracranial pressure complicated by visual loss. Vision can be saved after shunt failure, and in other cases may be maintained without the need for a shunt. Shunts may still be required, however, after optic nerve sheath decompression, especially for persistent headache.

(*J Neurol Neurosurg Psychiatry* 1994;57:1426-1429)

At least 50% of patients with benign intracranial hypertension (pseudotumour cerebri, idiopathic intracranial hypertension) develop visual loss over a period of time and up to 10% may have pronounced field and acuity deficits.¹

It is now established that fashioning a window (fenestration) in the retrolaminar optic

nerve sheath may relieve axoplasmic stasis and protect the optic nerve head from irreversible nerve fibre loss in chronic papilloedema.^{2,3} We report our results of optic nerve sheath decompression performed on a group of patients with chronic raised intracranial pressure and visual failure and the relation between optic nerve sheath decompression, visual outcome, and other CSF diversion procedures.

Materials and methods

Out of 23 identified cases on whom optic nerve sheath decompression had been performed, adequate follow up data of at least one year was available in 14.

All patients were referred by physicians and ophthalmologists to the neuro-ophthalmology clinic at the National Hospital for Neurology and Neurosurgery. Each underwent detailed ophthalmic evaluation including refraction and best corrected Snellen acuity, quantitative kinetic perimetry (Goldmann fields using modified Armaly-Drance strategy for detection of disc related field loss), dilated funduscopy, and fundus photography with fluorescein angiography. Space occupying lesions and hydrocephalus were excluded by CT (and by MRI in the most recent patients). All patients had at least two measurements of CSF opening pressure in excess of 25 cm water, normal CSF constituents, and angiography as appropriate. There were 11 cases of benign (idiopathic) intracranial hypertension, two cases of dural venous sinus thrombosis, and one of bilateral glomus jugulare tumour. Optic nerve sheath decompression was performed after demonstrating progressive peripheral, arcuate, or altitudinal field loss in addition to enlargement of the blind spot or uncontrollable visual obscurations in one or both eyes.

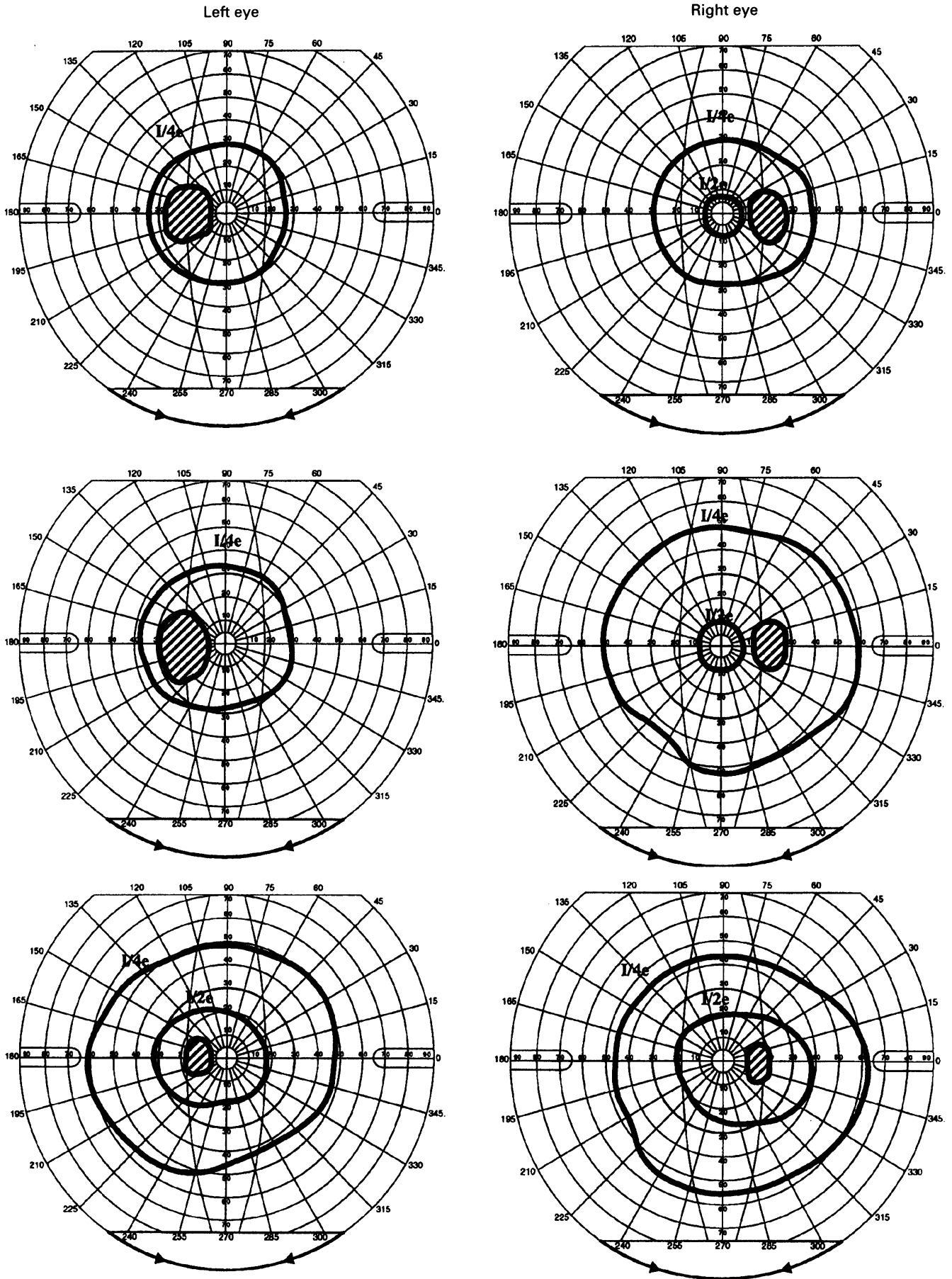
All cases had failed to respond adequately to maximal medical treatment and four had continued to have progressive visual failure after shunting or subtemporal decompression. Maximal medical treatment included supervised weight loss and carbonic anhydrase inhibitor (acetazolamide up to 1 g daily). Five patients were treated with loop diuretics (frusemide) and corticosteroids for short periods. Serial lumbar punctures were not used as a part of treatment.

The more severely affected eye was

Department of Neuro-ophthalmology, National Hospital for Neurology and Neurosurgery, London WC1 and Department of Ophthalmology, St Thomas's Hospital, London SE1, UK
J F Acheson
W T Green
M D Sanders

Correspondence to: Mr J F Acheson, Department of Neuro-ophthalmology, National Hospital for Neurology and Neurosurgery, Queen Square, London WC1N 3BG, UK.

Received 13 December 1993 and in final revised form 19 May 1994.
Accepted 24 May 1994



Summary of visual fields and acuities over follow up period in case 13. Top (March 1988, VAR 6/6, VAL 6/6); shortly before bilateral optic nerve sheath decompression showing pronounced constriction and blind spot enlargement in both eyes. Middle (January 1989, VAR 6/6, VAL 6/6); eight months after right and one day before left optic nerve sheath decompression. Expansion in right field and no change in the left. Bottom (January 1991, VAR 6/6, VAL 6/6); two years after second optic nerve sheath decompression. Expansion of left field and further improvement in I/2e isoptre on right.

Clinical details of patients undergoing optic nerve sheath decompression (ONSD)

Patient	Age at presentation	Diagnosis	Eye	Preoperation acuity	Preoperative field	Obscurements	Postoperative acuity at 6 months	Postoperative field at 6 months	Final acuity
1 Male	41	BIH	Left 1984	6/18	Large blind spot Constriction	Yes	6/6	Blind spot normal Expanded Blind spot normal Enlarged field	6/6
			Right 1989	6/12	Large blind spot Constriction	Yes	6/6		6/6
2 Male	50	BIH	Left 1987	6/18	Large blind spot Constriction	Yes	6/9	Normal	6/9
3 Male	47	BIH	Right 1985	6/5	Large blind spot	Yes	6/5	Normal blind spot	6/5
4 Female	25	BIH	Right 1981	6/6	Severe constriction	No	6/5	Severe constriction	6/5
			Left 1981	6/18	Severe constriction	No	6/5	Severe constriction	6/5
5 Female	26	BIH	Right 1983	6/6	Large blind spot Constriction	Yes	6/6	Large blind spot Constriction	6/9
6 Female	53	BIH	Right 1984	6/9	Large blind spot Constriction	Yes	6/24	Further constriction	6/60
7 Female	23	BIH	Left 1989	6/9	Large blind spot Constriction	Yes	6/6	Normal blind spot Less constricted	6/6
8 Female	32	BIH	Right 1978	6/12	Large blind spot Nasal constriction	Yes	6/9	Less constriction	6/9
			Left 1978	HM	Severe constriction	Yes	CF	Less constriction	CF
9 Male	44	BIH	Left 1990	6/9	Altitudinal defect	Yes	6/5	Improved	6/5
10 Female	24	BIH	Left 1991	6/6	Large blind spot	Yes	6/6	Normal blind spot	6/6
11 Female	43	BIH	Right 1992	6/9	Large blind spot Constriction	Yes	6/12	Further constriction	6/18
			Left 1992	6/6	Large blind spot Constriction	Yes	6/6	Less constriction	6/6
12 Male	58	Sagittal sinus thrombosis	Left 1981	6/9	Large blind spot Constriction	No	6/24	More constriction	NPL
13 Male	34	Lateral sinus thrombosis; otitis media	Right 1988	6/6	Constriction	Yes	6/6	Less constriction	6/6
			Left 1989	6/6	Constriction	Yes	6/6	Less constriction	6/6
14 Male	47	Bilateral glomus tumours	Left 1979	6/6	Large blind spot Constriction	Yes	6/6	Expanded	6/6
			Right 1979	6/12	Large blind spot Constriction	Yes	6/6	Expanded	6/6

Data for patient 13 are illustrated in the figure.

BIH = benign intracranial hypertension; ONSD = optic nerve sheath decompression.

operated on initially, with second eye surgery only performed after the demonstration of further visual failure on that side after the first procedure. Follow up data were available for at least 12 months (mean two years) after optic nerve sheath decompression. Improved visual function was defined as improvement by at least two full lines of corrected Snellen chart acuity and in the Goldmann fields by an expansion of at least 15 degrees in two isopters over two quadrants.

A medial transconjunctival approach was used under general anaesthetic. The medial rectus was disinserted and the globe fully abducted with the help of a traction suture attached to the disinserted muscle tendon. The medial intraconal orbital compartment was visualised directly under the operating microscope and the short posterior ciliary vessels reflected together with fascia bulbi and orbital fat using malleable retractors to

expose the anterior optic nerve sheath. A window of nerve sheath of about 3 × 4 mm was removed allowing free flow of CSF into the orbit. More recently we have created a larger (4 × 6 mm) window in the dura but this was not done in the cases reported here. The medial rectus and conjunctiva were replaced using resorbable sutures.

Results (table)

A total of 20 eyes in 14 cases underwent optic nerve sheath decompression. In the 11 patients with a diagnosis of benign intracranial hypertension, eight were women and the mean age was 37 (range 24–50) years. The remaining three patients with other causes for pseudotumour cerebri were men with a mean age of 46 years.

Eleven eyes had reduced acuity before operation; of these five improved, three remained the same, and three deteriorated

Final field	Final obscurations	Total follow up	Comments
Normal	Ceased	7 years	Lumbar-peritoneal shunt in 1990 for uncontrolled headaches
Normal	Ceased	1 year	Preoperative gaze evoked amaurosis resolved
Normal	Ceased	1 year	No shunt
Normal	Ceased	1 year	No shunt
No change	None	3 years	Lumbar-peritoneal shunt in 1977 failed;
No change	None	3 years	Subtemporal decompression in 1984 for persistent headache
Stable	Persisted	7 years	Disc swelling, obscurations and headache persisted after ONSD Right disc and field remained normal. Shunt in 1984
Further loss	Persisted	2 years	Subtemporal decompression 2 months before ONSD. Lumbar-peritoneal shunt 9 months after ONSD to relieve obscurations
No change	Ceased	1 year	Lumbar-peritoneal shunt 6 months before ONSD: failed
Normal	Ceased	4 years	No shunt
Stable	Ceased	4 years	No shunt
Stable	Ceased	18 months	No shunt
Stable	Ceased	2 years	Other eye developed disc swelling and obscurations after ONSD. Headaches persisted; Lumbar-peritoneal shunt in 1992
Further loss	Ceased	1 year	No shunt
Improved	Ceased	1 year	Cortical venous infarction 2 weeks after ONSD. No shunt
Normal	Ceased	7 years	5 failed lumbar-peritoneal shunts before first ONSD in 1988
Normal	Ceased	2 years	
Stable	Ceased	2 years	No shunt
Stable	Ceased	2 years	

after surgery. In nine eyes with normal pre-operative visual acuity this remained stable after surgery. All 20 eyes had an abnormal visual field before surgery (blind spot enlargement and constriction); 12 of these improved, five remained unchanged, and three deteriorated. Obscurations were prominent in 12 patients and were relieved in 10. In the eight patients undergoing unilateral surgery, the other eye had a normal field and acuity at the time of operation and seven remained stable. In case 10 the operated eye improved but the other eye went on to develop papilloedema and obscurations together with deteriorating headache and the patient required a lumbar-peritoneal shunt.

Four patients came to optic nerve sheath decompression after other surgery for benign intracranial hypertension: three of these had had lumbar peritoneal shunts that had failed (one after four revisions) and the fourth had had a subtemporal decompression that had also failed.

Five patients required subsequent surgery. This was for persistent headache (cases 1 and 4), unrelieved visual failure (cases 5 and 6), or both (case 10). One had a subtemporal decompression and the others were given shunts.

Discussion

Medical measures to control headache and visual symptoms in chronic raised intracranial pressure may be both ineffective and poorly tolerated. These measures include weight loss, carbonic anhydrase inhibitors, corticosteroids, and serial lumbar punctures. Surgical CSF diversion procedures designed to reduce intracranial pressure are more effective but there is a significant long term failure rate.⁴ Furthermore, progressive visual failure in the presence of a functioning shunt may occur. For these reasons, relief of CSF pressure on the distal optic nerve by the direct approach of optic nerve sheath decompression is an attractive option in cases in which visual loss is prominent.

Evidence for the efficacy of optic nerve sheath decompression continues to accumulate. In the series of Corbett *et al.*,² of 28 patients and 40 eyes, there was improved or stabilised acuity in 33 eyes. In the series by Sergott *et al.*⁵ 21 eyes improved out of 29 operated on in 21 patients, and similar results have been reported by others. The procedure is not without risk, and permanent visual loss as a result of intraoperative axonal or vascular damage has been described.⁶

A medial transconjunctival approach is usually preferred to the alternative operation by lateral orbitotomy. This is because the surgical approach to the optic nerve sheath from the lateral side is technically more complex. There are greater risks of damage to the ciliary ganglion resulting in a dilated pupil and accommodation paresis, and to nerve fibres serving central vision, which lie on the lateral side of the retrolaminar optic nerve. In our series there were no instances of optic nerve damage directly attributable to the operation.

In conclusion, we believe that optic nerve sheath decompression can play an important part in the management of patients with visual failure in pseudotumour cerebri. Vision can be restored in patients for whom shunts have been unsuccessful, and other patients may maintain vision with optic nerve sheath decompression without requiring a shunt. Shunts may still be required after optic nerve sheath decompression, however, especially to control headaches.

- Orcutt JC, Page NGR, Sanders MD. Factors affecting visual loss in benign intracranial hypertension. *Ophthalmology* 1984;91:1303-12.
- Corbett JJ, Nerad JA, Tse DT, Anderson RL. Results of optic nerve sheath fenestration for pseudotumour cerebri. *Arch Ophthalmol* 1988;106:1391-7.
- Brouman ND, Spoor TC, Ramocki JM. Optic nerve sheath decompression for pseudotumour cerebri. *Arch Ophthalmol* 1988;106:1378-83.
- Rosenberg ML, Corbett JJ, Smith C, *et al.* CSF diversion procedures in pseudotumour cerebri. *Neurology* 1993; 43:1071-2.
- Sergott RC, Savino PJ, Bosley JM. Modified optic nerve sheath decompression provides long-term visual improvement for pseudotumour cerebri. *Arch Ophthalmol* 1988;106:1384-90.
- Plotnik JL, Kosmorsky GS. Operative complications of optic nerve sheath decompression. *Ophthalmology* 1993;100:683-90.