

LETTERS TO THE EDITOR

Electroconvulsive therapy in Parkinson's disease: 30 month follow up

To examine the long term effects of electroconvulsive therapy (ECT) on the symptoms of Parkinson's disease, we followed up a series of 14 patients. The initial response of the symptoms of 10 of these patients has been reported.¹

Follow up examination was performed up to 36 months after treatment, depending on the date at which the patient was recruited. We devised a retrospective questionnaire based on the motor examination section of the unified Parkinson's disease rating scale² to assist in the determination of the degree and persistence of any change in symptoms. The questionnaire considered tremor, rigidity, speed of hand movements, rising from a chair, and gait. All patients were asked all questions as a means of assisting patients in a comprehensive reflection of their progress. An assessment of benefit was then made. Benefit was rated as nil, mild (clearly discernible and considered to be of value by the patient), and marked (a reduction or removal in symptoms which was clear and highly valued by the patient). A rating of positive benefit could be achieved by great improvement in one particularly distressing symptom, or by lesser improvement across a range of symptoms. We also asked the patients whether they could envisage electing to have a further course of ECT in the future.

All 14 patients were located. Two patients had died; on one of these there was sufficient information to comment on outcome. One patient was excluded as there had been progression to supranuclear palsy. In this patient, however, the spouse reported that although there had not been dramatic benefit, there had been a return from chronic hypertonia to normal tone in the patient's hands. This valued change had persisted to

the time of follow up (32 months).

The table presents the details of age, sex, assessment of benefit, and period of benefit (if any) of the 12 patients with Parkinson's disease about whom full information was available. About one third had either no benefit or mild benefit which lasted two weeks or less, one third had mild benefit which lasted from four weeks to 30 months, and one third had marked benefit which lasted from 10 weeks to 35 months.

Although this is the largest group of people with Parkinson's disease without depression who received ECT yet reported, it is still small for statistical purposes. Parkinson's disease has many clinical variables so that examining statistical correlations between these and outcome with this size sample is not feasible. However, our clinical impression is that older people and those with more severe problems did best. Tremor, akinesia, and rigidity all responded well to ECT in certain patients. Reduction in tremor was particularly noticeable.

Patient 11 remained drug free for 18 months, and then started taking small amounts of antiparkinsonian medication. Patient 12 was able to leave a wheelchair and has been able to walk independently for over three years.

More than half of the patients who could give an opinion stated that they could envisage electing to have a further course of ECT in the future. We conclude that ECT is useful in the management of patients whose symptoms are unresponsive or who have developed intolerable side effects to medication.

SAXBY PRIDMORE

CECILY POLLARD

Department of Psychological Medicine,
Royal Hobart Hospital,
Hobart, Tasmania, Australia

Correspondence to: Professor S Pridmore, Department of Psychological Medicine, Royal Hobart Hospital, GPO Box 1061L, Hobart, Tasmania, 7001, Australia.

- 1 Pridmore S, Yeo PT, Pasha MI. Electroconvulsive therapy for the physical signs of Parkinson's disease without depressive disorder. *J Neurol Neurosurg Psychiatry* 1995;58: 641-2.
- 2 Fahn S, Elton R and members of The UPDRS Development Committee. Unified Parkinson's disease rating scale. In: Fahn S, Marsden C, Calne D, eds. *Recent developments in Parkinson's disease*. Vol 2. New Jersey: Macmillan Health Care, 1987: 153-63.

Details of age, sex, assessment of benefit, and period of benefit (where appropriate) of 12 patients with Parkinson's disease who received ECT and about whom full information was available (see text).

Patient	Age	Sex	Benefit	Period of benefit
1	45	M	Nil	Not applicable
2	61	M	Nil	Not applicable
3	63	M	Nil	Not applicable
4	77	M	Mild	2 weeks
5	65	M	Mild	4 weeks
6	61	F	Mild	10 months
7	78	M	Mild	30 months (ongoing)
8	67	F	Mild	30 months (ongoing)
9	67	F	Marked	10 weeks
10	70	M	Marked	18 months (to death)
11	67	M	Marked	31 months (ongoing)
12	72	M	Marked	35 months (ongoing)

Pretarsal injections of botulinum toxin improve blepharospasm in previously unresponsive patients

Subcutaneous injection of botulinum toxin (BTX) is the first choice symptomatic treatment for blepharospasm. When injected in

the upper and lower eyelids and in the eyebrows BTX causes a chemodenervation of the orbicularis oculi muscle which provides symptomatic relief to about 85% of patients.¹ In some of the patients who have a poor response, increasing the dosage may provide benefit. In a few patients, however,

this approach is of no help: some patients report no benefit after the first treatment (primary non-responders); others report an initial improvement followed by a decline in clinical benefit in subsequent treatments (secondary non-responders).

In recent publications it has been occasionally claimed that injections in the proximity of the pretarsal rather than the orbital portion of the orbicularis oculi muscle provide better results.² It has also been recently shown that combined pretarsal and orbital injections of BTX are more beneficial than just orbital ones.³ There is no study, however, directly comparing orbital and pretarsal BTX treatments in the same patients. We have performed orbital infiltration of BTX since 1989,⁴ as originally done in most other centres. Later, we tried pretarsal sites in patients who did not respond adequately. We report here on those patients.

A series of 143 consecutive outpatients, regularly seen at the movement disorder clinics of Policlinico Gemelli, Rome (94 patients) and of San Raffaele Hospital, Milan (49 patients), was treated in the period 1992-4. The starting total dose of BTX used for blepharospasm was between 20 and 25 U (Botox®, Allergan). This dose was gradually adjusted in each patient, based on diaries completed by the patients and on the examiner's judgement. An efficacious individual dose was found, in most patients, between the second and the fourth treatment session. The patients were instructed to return to the fortnightly clinic for their next treatment soon after the symptomatic benefit had worn off. If they had no benefit, they returned after three months.

The figure shows the standard sites for subcutaneous orbital injections. All patients were injected at points a, b, c, and d. An average total dose of 30 U was sufficient to produce the expected improvement in most patients. From this population we selected nine consecutive patients (6.3% of the total), who were treated at least twice with increasing doses of BTX, but who had never experienced a significant improvement of blepharospasm; this occurred despite a mean (SD) BTX dose higher than average (46.4 (21.4) U) and the occurrence of side effects (for example, ptosis, diplopia).

The pretarsal treatments were performed at three-monthly intervals. All patients were injected at sites e, f, g, and h. The clinical evaluation was performed and severity of the spasms rated before and a fortnight after each treatment session by means of the Burke and Fahn disability rating scale.⁵ The effect of pretarsal treatment was evaluated by Student's *t* test.

The selected patients were three men and six women with a mean age of 57.0 (15.7) years and a mean disease duration of 4.9 (2.7) years. All were affected by idiopathic focal dystonia, blepharospasm being isolated in six patients and associated with lower facial spasm (Meige syndrome) in the other three. Patients 1, 7, and 9 had some improvement only after the first orbital treatment; the remaining patients were primary non-responders. The patients received increasing doses of BTX at pretarsal sites, starting with a total dose of 8.75 U that was subsequently increased as required.

The patients received an average (SD) total BTX dose of 31.4 (10.8) U in 3 (1) subsequent treatment sessions. The disability rating scale before pretarsal treatment scored 3.9 (0.3). A significant improvement after pretarsal injections with BTX occurred

in all patients. The average disability score for blepharospasm after pretarsal treatment was 0.6 (0.5) ($P < 0.001$). The mean duration of the clinical effect was 67.2 (17.2) days.

All the patients complained of a slight, but definite, increase in pain during pretarsal injections (compared with orbital injections); most patients had ecchymoses at the injection sites. Ptosis or diplopia were not seen after pretarsal injections.

This study shows that pretarsal BTX injections resulted in a pronounced symptomatic improvement of blepharospasm in patients who failed to benefit after standard orbital injections.

Lack of efficacy of orbital BTX treatment is not usually related to antibody production.² Our study shows that all the patients responded favourably to BTX when it was injected either at orbital or at pretarsal sites. All these patients had a typical blepharospasm and did not meet the clinical criteria for a diagnosis of apraxia of eyelid opening or of levator palpebrae inhibition; these have been reported to respond to pretarsal but not to orbital treatment.⁶

As pretarsal injections may be effectively used to treat patients affected by blepharospasm who do not improve after orbital injections, this raises the question as to whether all patients with blepharospasm should be regularly treated at pretarsal sites. We think that this technique should be employed in all cases of blepharospasm, either alone or in combination with orbital infiltration. A slight increase in pain during treatment and in the incidence of ecchymoses are counterbalanced by higher clinical efficacy, immediacy of benefit, and reduction of dose and cost.

This study was supported by Comitato Promotore Telethon grant E113 to AA.

A ALBANESE
A R BENTIVOGLIO
C COLOSIMO
Istituto di Neurologia,
Università Cattolica del Sacro Cuore,
Roma, Italy
G GALARDI
L MADERNA
Clinica Neurologica,
Istituto Scientifico San Raffaele,
Milano, Italy
P TONALI
Ospedale CSS IRCCS,
San Giovanni Rotondo, Italy

Correspondence to: Dr Alberto Albanese, Istituto di Neurologia, Università Cattolica, Largo A Gemelli, 8, I-00168 Roma, Italy.

- 1 Jankovic J, Brin MF. Therapeutic uses of botulinum toxin. *N Engl J Med* 1991;324:1186-94.
- 2 Greene P, Fahn S, Brin MF, Blitzer A. Botulinum toxin therapy. In: Marsden CD, Fahn S, eds. *Movement disorders 3*. Oxford: Butterworth-Heinemann, 1994:477-502.
- 3 Aramideh M, Ongerboer de Visser BW, Brans WM, Koelman HTM, Speelman JD. Pretarsal application of botulinum toxin for treatment of blepharospasm. *J Neurol Neurosurg Psychiatry* 1995;59:309-11.
- 4 Albanese A, Colosimo C, Carretta D, Dickmann A, Bentivoglio AR, Tonali P. Botulinum toxin as a treatment for blepharospasm, spasmodic torticollis and hemifacial spasm. *Eur Neurol* 1992;32:112-7.
- 5 Burke RE, Fahn S, Marsden CD, Bressman SB, Moskowitz C, Friedman J. Validity and reliability of a rating scale for the primary torsion dystonias. *Neurology* 1985;35:73-7.
- 6 Aramideh M, Ongerboer de Visser BW, Deviese PP, Bour LJ, Speelman JD. Electromyographic features of levator palpebrae superioris in orbicularis oculi muscles in blepharospasm. *Brain* 1994;117:27-38.

Leucoencephalopathy after inhalation of heroin: a case report

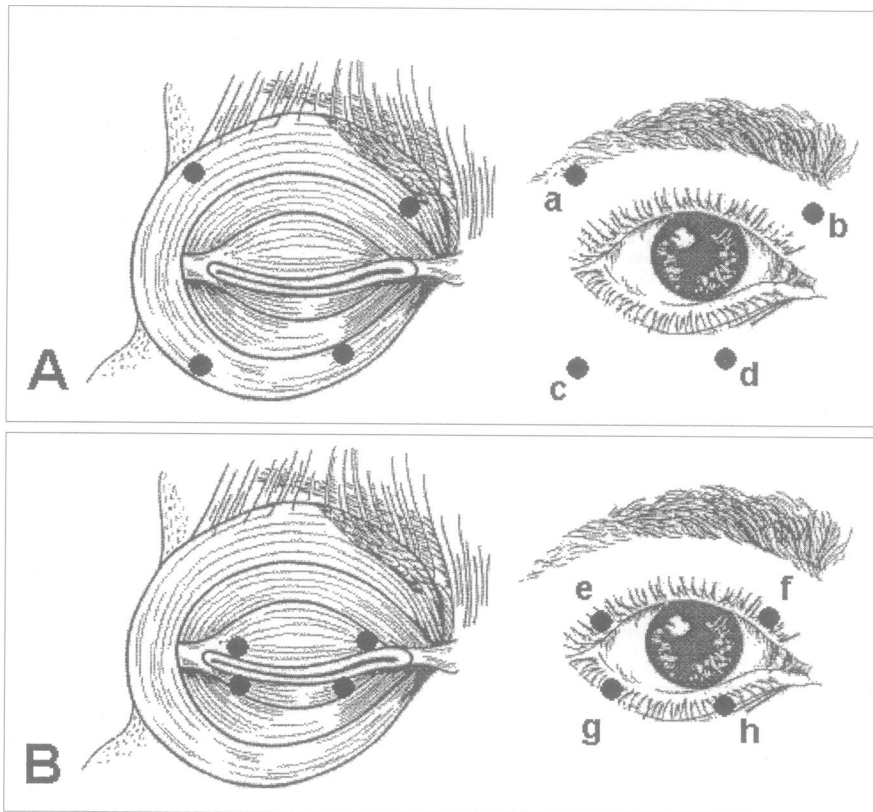
The use of heroin, a diacetyl derivate of morphine, is common among drug addicts. Heroin may be taken in different ways; intravenously, subcutaneously, smoked, sniffed, or inhaled. As well as psychosocial degeneration, common medical complications of heroin addiction are encephalopathy, transverse myelitis, myelopathy, cerebral infarctions, meningitis, cerebral abscesses, mycotic aneurysms, myopathies, and plexopathies. A subacute leucoencephalopathy showing spongiform neuropathological changes has been reported as a rare complication to inhalation of preheated heroin.¹⁻⁷ Clinical, radiological, and neuropsychological findings in a patient with this syndrome are presented here.

A 36 year old Moroccan man living in Norway for 16 years was referred for neurological examination. He had no history of neurological or psychiatric illness. Drug misuse started six years previously with sporadic misuse of cannabis, increasing to daily cannabis in the past two years. Heroin misuse began two years previously. The heroin was most often inhaled as a white smoke (pyrolysate) after preheating on tinfoil, occasionally smoked mixed in tobacco, or sniffed, but never intravenously injected. During the six months before the onset of symptoms he used heroin daily in doses from 250-500 mg; he used no other illicit drugs or medication and alcohol consumption was moderate. Over a few weeks he developed increasing dysarthria and ataxia as major symptoms. Drug misuse was terminated, and his symptoms remained unchanged until he was referred for neurological examination four months later.

The clinical neurological examination disclosed psychomotor retardation, pronounced scanning dysarthria, bilateral cerebellar ataxia, dysidiadochokinesia, intention tremor, and dysmetria. There was a general hyperreflexia with right sided predominance; plantar reflexes were neutral. Apart from retardation of the tongue, the cranial nerves were normal. Motor function showed no abnormalities except for those that could be ascribed to cerebellar dysfunction, and sensory examination was normal.

Cerebral CT showed non-enhancing hypodense areas symmetrically in both cerebellar hemispheres. Cerebral MRI showed corresponding areas with decreased signal intensity on T1 weighted images (figure) and increased signal intensity similar to CSF on T2 weighted images. No lesions were seen in the brain stem or cerebral hemispheres, and there was no contrast enhancement. Somatosensory and brainstem evoked potentials and EEG were normal. Visual evoked potentials were normal on the right side and inconclusive due to an earlier eye lesion on the left. The CSF (cell count, total protein, and agarose electrophoresis) was normal.

The patient was admitted to a rehabilitation unit for physical and cognitive therapy. Neuropsychological examination was performed eight months after onset of symptoms with the Wechsler adult intelligence scale (WAIS), Halstead-Reitan neuropsychological test battery, and other selected tests. The patient showed a pronounced and generalised impairment of cognitive, motor, and sensory-perceptual functions reflected by a Halstead impairment index of 0.9, corresponding to a T score of 13, representing



Common sites for BTX injection into the eyelids. The orbital, preseptal, and pretarsal portions of the orbicularis oculi muscle are shown in the left panels. (A) Orbital injections: a, lateral upper lid; b, medial upper lid; c, lateral lower lid; d, medial lower lid. (B) Pretarsal injections: e, lateral upper lid; f, medial upper lid; g, lateral lower lid; h, medial lower lid.