

roglobulin, antimicrosome, or antiskeletal muscle autoantibodies whereas the generalised type showed a high titre and incidence of autoantibodies including AChR antibody.<sup>5</sup> Seronegative patients or those with low AChR antibody may form a low responder subgroup of myasthenia gravis distinct from the high responders, who show a high titre of AChR antibody.

Twelve patients (37.5%) were of the ocular type, which is higher than the incidence in the report of Confalonieri *et al.*<sup>1</sup> All subjects in Cohen-Kaminsky's report had generalised myasthenia gravis of type IIa or IIb.<sup>2</sup> Chiu *et al.*<sup>6</sup> reported a difference in myasthenia gravis expression between Chinese and Caucasians. The characteristic population pattern in our study may be common to east Asians and may partly cause a different correlation between sIL-2R and disease activity.<sup>1,2</sup> The study of this characteristic population may lead to the elucidation of the pathogenesis of low responder myasthenia gravis.

We thank Ms Ichikawa (SRL, Tokyo, Japan) for technical assistance in detecting sIL-2R. The work was supported partly by Grant in Aid of Scientific Research No 04670604 from the Ministry of Education, Science, and Culture of Japan.

MASATOSHI HAYASHI  
KAICHI KIDA

Department of Pediatrics,  
Ehime University School of Medicine,  
Ehime, Japan  
JUNJI YOSHINAGA  
Department of Neurology,  
Hiroshima City Hospital,  
Hiroshima, Japan

Correspondence to: Dr Masatoshi Hayashi, Department of Pediatrics, Ehime University School of Medicine, Shigenobu-cho, Onsen-gun, Ehime 791-02, Japan.

- 1 Confalonieri P, Antozzi C, Cornelio F, *et al.* Immune activation in myasthenia gravis, soluble interleukin-2 receptor, interferon- $\gamma$  and tumor necrosis factor- $\alpha$  levels in patients' serum. *J Neuroimmunol* 1993;48:33-6.
- 2 Cohen-Kaminsky S, Jacques Y, Aime C, *et al.* Follow-up of soluble interleukin-2 receptor levels after thymectomy in patients with myasthenia gravis. *Clin Immunol Immunopathol* 1992;62:190-8.
- 3 Komp DM, Shapiro E, McNamara J. Soluble interleukin-2 receptor in childhood non-Hodgkin's lymphoma. *Blood* 1988;71:1172-4.
- 4 Mossman S, Vincent A, Newsom-Davis A. Myasthenia gravis without acetylcholine-receptor antibody: a distinct disease entity. *Lancet* 1986;i:116-8.
- 5 Kida K, Hayashi M, Yamada I, *et al.* Heterogeneity in myasthenia gravis: HLA phenotypes and autoantibody responses in ocular and generalized types. *Ann Neurol* 1987; 21:274-8.
- 6 Chiu H-C, Vincent A, Newsom-Davis J, *et al.* Myasthenia gravis: population differences in disease expression and acetylcholine receptor antibody titers between Chinese and Caucasians. *Neurology* 1987;37:1854-7.

#### Decreased magnetisation transfer ratio due to demyelination: a case of central pontine myelinolysis

Conventional T2 weighted MRI has a high sensitivity for detecting multiple sclerosis lesions and is widely used for diagnosis and monitoring the efficacy of new treatments. An important limitation of T2 weighted images is their low pathological specificity: they do not identify the two pathological features that cause functional impairment in multiple sclerosis—namely, demyelination and axonal loss. This lack of pathological

specificity contributes to the weak relation between MRI abnormalities and disability in multiple sclerosis. Magnetisation transfer (MT) imaging indirectly visualises immobile water protons tightly bound to macromolecular structures that have very short T2 relaxation times and are invisible on conventional images. Measurement of MT ratio (MTR) in lesions provides information about structural integrity and by inference, myelin and axons. To explore the hypothesis that demyelination itself has an important effect on MTR, we performed MT imaging of a patient with central pontine myelinolysis—a condition in which demyelination is the predominant pathological feature.

A 50 year old woman presented with memory disturbance and poor balance. There was a long history of alcohol misuse leading to hospital admission with delirium tremens three months previously. There was no other history of note. Since then she had abstained from alcohol, after noticing residual poor balance and memory loss for recent events. Both problems worsened considerably in the weeks leading to her most recent admission. She also developed peripheral paraesthesiae, ankle swelling, and weight loss. Mental state examination showed a specific deficit in recent memory and formation of new memory, although registration was intact. On neurological examination she had a broad based ataxic gait and positive Romberg's test. Cranial nerve examination showed bilateral gaze-evoked non-sustained horizontal nystagmus, but no other abnormalities. Ataxia was present in upper and lower limbs, more pronounced in the legs. Tone was increased in the lower limbs. There was no left ankle reflex and plantar responses were extensor. Vibration sense was absent in both legs and joint position sense was decreased in the toes. Light touch and pinprick sensation were reduced in the hands.

T2 weighted MRI demonstrated a single high signal symmetric lesion confined to the basis pontis which appeared hypointense on T1 weighted images (fig 1). There was no enhancement after intravenous injection of gadolinium-DTPA. Mild cerebral atrophy was also noted. Further imaging was carried out on a 1.5 Tesla GE Signa MRI scanner

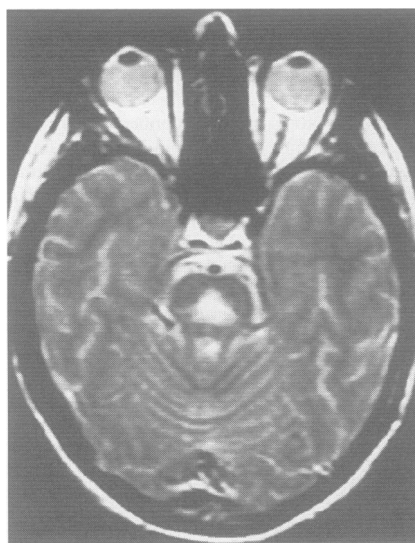


Figure 1 T2 weighted MRI showing high signal symmetric lesion in the centre of the pons, characteristic of central pontine myelinolysis.

with standard quadrature headcoil to obtain calculated MT images (fig 2). A dual spin echo sequence was used (TR 1730, TE 31/80, 28 contiguous 5 mm slices) both with and without presaturation pulses to saturate the broad resonance of immobile macromolecular protons. Results were analysed on a Sun workstation using image display software (Dispimage, DL Plummer, Department of Medical Physics, University College, London, UK). The MTR was greatly reduced in the centre of the pontine lesion with a value of 8.6%, compared with a normal value of 38.2% (obtained from the pons of five normal age matched female controls). Values for MTR in the surrounding rim of intact pontine tissue were normal. The greatest decrease in MTR was at the centre of the lesion, gradually increasing towards the outer edge.

The pathological findings associated with central pontine myelinolysis are remarkably homogeneous: a single large symmetric lesion is found in the basis pontis. There is usually a rim of intact pontine tissue. Microscopically the main abnormality is destruction of myelin, with relative neuronal preservation.<sup>1</sup> Myelin destruction is typically most severe at the centre of the lesion, becoming less pronounced towards the edge.<sup>1</sup> There are no inflammatory changes and oedema is absent.<sup>1</sup> In our patient we were confident that the lesion was due to central pontine myelinolysis, because of the clinical setting (alcoholism along with clinical features of Wernicke-Korsakoff syndrome) and the highly characteristic appearance of the MRI abnormality on the T2 and T1 weighted images. One notable feature was the lack of deficit related to the pontine lesion. Many patients with central pontine myelinolysis become profoundly disabled with bulbar palsy and tetraplegia during the acute phase of the illness. However, typical pathological changes of this condition have also been found at postmortem where there has been minimal neurological deficit referable to the pontine lesion. With the advent of MRI, patients like ours have been seen in whom the characteristic radiological abnormality has been identified in the presence of minimal clinical disability.

To identify specifically the structural

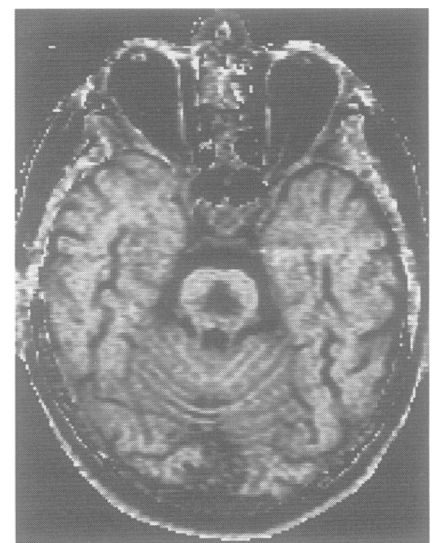

Figure 2 Calculated MTR image showing reduction of MTR in the pons, with preservation of signal in the surrounding rim.

changes caused by axonal and myelin loss in demyelinating lesions, such as occur in multiple sclerosis, there is a need for an in vivo technique that measures macromolecular loss; MT imaging, which is based on the specific interaction between macromolecular and free water protons, has shown promise in this regard. Pronounced reductions in MTR have been found in lysolecithin induced demyelination,<sup>2</sup> chronic experimental allergic encephalomyelitis lesions (in which there is demyelination), and progressive multifocal leucoencephalopathy (a condition in which demyelination predominates with a relative lack of inflammation or axonal loss). On the other hand, in acute experimental allergic encephalomyelitis in which there is inflammation and oedema without demyelination, only mild reductions in MTR are seen.<sup>3</sup> In optic neuritis, reduction of MTR within the optic nerve lesion correlates with the latency of the visual evoked potential,<sup>4</sup> suggesting that a graded relation may exist between MTR reduction and the extent of demyelination. This present patient provides additional evidence in favour of myelin itself being a major contributor to the MT effect.

A wide range of values of MTR is seen in multiple sclerosis lesions, and a correlation exists between lesion MTR and disability.<sup>5</sup> It is uncertain whether MTR measurement will be able to separate demyelination alone from demyelination which occurs as a consequence of axonal loss. The second may be more important for irreversible disability in multiple sclerosis. Further experimental studies are needed to elucidate the quantitative MTR changes that occur in these two processes. Nevertheless, MTR measurement seems a robust, quantitative, and clinically relevant indicator of myelin integrity and may have an important role in monitoring the natural history of multiple sclerosis and its modification by treatment.

The NMR Research Unit is supported by a generous grant from the Multiple Sclerosis Society of Great Britain and Northern Ireland.

NC SILVER  
GJ BARKER  
DG MACMANUS  
DH MILLER  
NMR Research Unit,  
Department of Clinical Neurology,  
Institute of Neurology,  
Queen Square,  
London WC1N 3BG, UK  
JW THORPE  
RS HOWARD  
St Thomas Hospital,  
Guys and St Thomas (Hospital) Trust,  
Lambeth Palace Road,  
London SE1 7EH, UK

Correspondence to: Dr DH Miller.

- Adams RD, Victor M, Mancall EL. Central pontine myelinolysis; a hitherto undescribed disease occurring in alcoholic and malnourished patients. *Arch Neurol Psychiatry* 1959; 81:154-72.
- Dousset V, Brochet B, Vital A, et al. Lysolecithin-induced demyelination in primates: preliminary in vivo study with MR and magnetization transfer. *Am J Neuroradiol* 1995;16:225-31.
- Dousset V, Grossman RI, Ramer KN, et al. Experimental allergic encephalomyelitis and multiple sclerosis: lesion characterisation with magnetization transfer imaging. *Radiology* 1992;18:483-91.
- Thorpe JW, Barker GJ, Jones SJ, et al. Magnetisation transfer ratios and transverse magnetisation decay in optic neuritis: correlation with clinical findings and electrophysiology. *J Neurol Neurosurg Psychiatry* 1995;59: 487-92.
- Gass A, Barker GJ, Kidd D, et al. Correlation of magnetization transfer ratio with clinical disability in multiple sclerosis. *Ann Neurol* 1994;36:62-7.

### Raised plasma polyamine concentrations in patients with severe head injury

Polyamines have been shown to be raised in response to neurological trauma in experimental models.<sup>1,2</sup> There are no reports that a similar process occurs in humans, prompting us to investigate whether plasma polyamines are raised in patients with head injury. Large increases in polyamines occur in the cerebral cortex after neurological trauma,<sup>2</sup> and, if reflected by increased plasma concentrations occurring as a result of disruption to the blood brain barrier, this could be a useful diagnostic and prognostic tool.

Seventeen patients with head injury were studied. The patients varied in the circumstance of injury, the time the sample was taken after the initial injury, and the CT findings, which showed extradural and subdural haematomas and cerebral contusions. One patient sustained an associated cardiac injury and four sustained associated musculoskeletal injuries; the other patients had no obvious organ damage apart from brain injury.

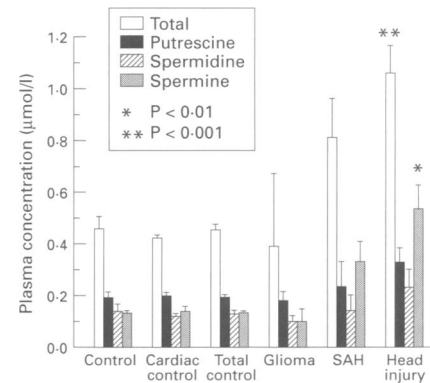
Blood samples were also taken from eight patients who had intracranial pathology unrelated to trauma (five with subarachnoid haemorrhage and three with malignant primary brain tumours). Control samples were taken from seven patients who underwent coronary artery bypass grafts (non-head injury traumatic controls) and seven normal subjects.

Dabsylation of polyamines was carried out as previously described<sup>3</sup> on plasma samples after protein precipitation with diaminoazobenzene sulphonyl chloride. The derivatives were separated by high performance liquid chromatography (HPLC) using a reverse phase C18 column and gradient elution with sodium acetate and acetonitrile. The total plasma polyamine concentration (spermine, spermidine, and putrescine) in  $\mu\text{mol/l}$  was quantified for each patient. Recovery of polyamines from standard mixtures (after dabsylation and HPLC) was >95% and >90% for standards (putrescine, spermine, and spermidine) added after trichloroacetic acid extraction and subjected to normal analytical procedures. The HPLC allowed separation of dabsyl derivatives of polyamines, which were identified using polyamine standards. The retention times were reproducible, showing variation between runs of <0.1 minutes.

A non-parametric analysis of the data was undertaken by Kruskal-Wallis test.

The figure shows the results of the mean plasma concentrations of polyamines in each group. There was a significant ( $P < 0.001$ ) increase in total polyamine in the head injury group ( $n = 17$  mean =  $1.04 \mu\text{mol/l}$ ); spermine was also significantly increased. None of the other subgroups were significantly raised above the normal and cardiac control groups, however, the polyamine concentrations tended to be increased in the subarachnoid haemorrhage group.

The total polyamine concentrations in the head injury group ranged from  $0.34$ – $1.86 \mu\text{mol/l}$ . It was difficult to correlate an increase in the plasma polyamine concentration with the degree of severity in a small group of patients with such diverse mechanisms of head injury, and differences in the time after head injury that the sample was taken. The lowest concentrations were, however, found in patients after evacuation of an extradural haematoma and the highest con-



Plasma polyamines were extracted, fractionated, and quantified by HPLC. Values are means (SEM). Significant differences are v control group.

centrations were found in those patients with the most severe trauma. A time dependent increase in polyamines was noted, a significant correlation being shown by regression analysis between both the total polyamines ( $P < 0.017$ ) and putrescine ( $P < 0.0001$ ) and the time after injury (up to 48 hours).

Both plasma and erythrocyte concentrations of each polyamine were assayed separately. The major pool of polyamines in blood is present in erythrocytes, which account for 80–90% of polyamine content in whole blood. No pronounced differences were detected in the erythrocyte samples between control and trauma groups. This may be because polyamines are synthesised within erythrocytes and therefore this pool would reflect largely locally synthesised polyamines whereas plasma polyamines would reflect concentrations of polyamines arising from an exogenous source more accurately. Erythrocytes do possess the ability to take up polyamines by a transporter but this may not affect internal concentrations of polyamines sufficiently to significantly alter concentration in erythrocytes in most trauma patients.

In animal experiments, the intracellular polyamines, especially putrescine, are raised in neurotrauma but extracellular concentrations are low after cerebral ischaemia.<sup>4</sup> From our own experience the effects of insults to the CNS on the induction of ornithine decarboxylase are enormous with severalfold increases in putrescine occurring. We therefore reasoned that if leakage due to trauma occurred we would be able to detect changes in plasma polyamines. The fact that significant effects are only detected for spermine, spermidine, and total polyamines indicates that extraneuronal transformations have occurred, both spermine and spermidine being derived from putrescine.

In conclusion, polyamines are increased in serious neurological trauma and the increase is detected in the peripheral blood in human subjects. A more detailed study will be necessary to elucidate the pattern of the "polyamine response" in the different head injury groups with a view to understanding the role of polyamines in intracranial trauma.

The work was supported by the special trustees of Charing Cross and Westminster Hospital and Medical School.

We acknowledge A Sofat, M Sharr, J Wickenden, NV Wilson, and SJ Booth.