

Bilateral Freiberg disease in a young female dancer: A case report

SAGE Open Medical Case Reports
Volume 11: 1–3
© The Author(s) 2023
Article reuse guidelines:
sagepub.com/journals-permissions
DOI: 10.1177/2050313X231221464
journals.sagepub.com/home/sco



Shailendra Katwal¹ , Sarad Katuwal²  and Sushmita Bhandari³

Abstract

Freiberg's infarction is the disorder of cartilage degeneration. The second metatarsal head is most vulnerable to Freiberg's infarction due to its longer length and relative immobility. It is exposed to repetitive stress even during normal activity. The multifactorial etiology of Freiberg's infarction is mentioned in the literature. It commonly affects the adolescent female with a female-to-male ratio of 5:1. High prevalence in adolescent females is explained in some literature due to wearing high heels, which leads to repetitive forced dorsiflexion injuries to the metatarsal head. Our case is an adolescent female of 20 years who was participating in dancing for 5 months. On examination, there is swelling and tenderness in the bilateral foot, more on the right side. Plain radiography showed the flattening of the head of the right second metatarsal with increased joint space. Mild sclerosis of the underlying bony cortex was seen. A mild deformity with flattening of the lateral surface of the head of the left second metatarsal was also seen.

Keywords

Freiberg, dancer, orthopaedics, radiology

Date received: 13 April 2023; accepted: 28 November 2023

Introduction

Freiberg's infarction is the osteonecrotic process that was first described in 1914.¹ It predominately affects the second metatarsal head although the third and fourth metatarsal head can also be affected. Incidence is higher in females in their second decade. The exact mechanism is unclear; however, vascular, genetic, and altered biomechanics are possible risk factors.² It is a rare disorder with even rarer bilateral involvement.³ It is usually diagnosed clinically and conventional radiography may be needed for confirmation. Early changes may be diagnosed with the help of magnetic resonance imaging (MRI) showing T1 low signal intensity or photopenic area in bone scans.² Conservative management is considered as a first line of treatment to control pain as well as to halt the progression to the advanced stage. Surgical management is used to correct the possible etiology and to address the advanced stage of the disease.^{4,5}

Case report

A 20-year-old female presented in the outpatient department with a 5-month insidious history of right foot pain, located predominately at the second toe. She also complained of mild pain in the left second toe. She described the pain as a

constant, dull type that exacerbated on walking. She used to go to the dance class every evening since 8 months. No history of trauma is present. She had no history of any systemic illness. On examination, there is swelling and tenderness in the bilateral foot, more on the right side. Plain radiography showed the flattening of the head of the right second metatarsal with increased joint space (Figure 1(a)–(d)). Mild sclerosis of the underlying bony cortex was seen (Figure 1(a)–(d)). Mild deformity with flattening of the lateral surface of the head of the left 2nd metatarsal was also seen (Figure 1(a)–(d)). No obvious soft tissue swelling was seen. MRI showed high signal intensity in the head of the first metatarsal in dorsal and plantar aspects (Figure 2(a) and (b)). The biochemical profile showed normal serum uric acid levels. Based on that clinical and radiological information, Freiberg's infarction was diagnosed. The patient was treated

¹Dadeldhura Subregional Hospital, Dadeldhura, Nepal

²Maharajgunj Medical Campus, Institute of Medicine, Tribhuvan University, Kathmandu, Nepal

³Fatima Jinnah Medical University, Lahore, Punjab, Pakistan

Corresponding Author:

Sarad Katuwal, Maharajgunj Medical Campus, Tribhuvan University, Teaching Hospital, Maharajgunj, Kathmandu 875/4, Nepal.
Email: katuwalsarad@gmail.com



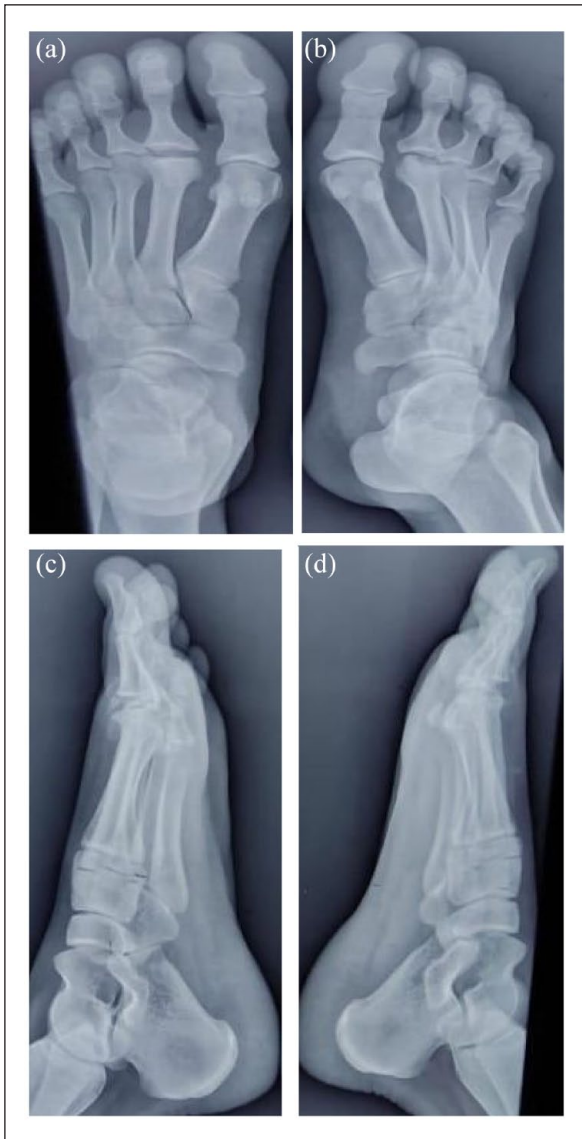


Figure 1. X-ray foot anteroposterior (a and b) and oblique view (c and d) of the bilateral foot shows flattening of the right second metatarsal head with the widening of the joint space. Sclerosis of the articular surface is also noted. No obvious cortical deformity is seen. The rest of the metatarsal and phalangeal bones are normal. There is mild deformity noted in the left metatarsal head with flattening in the lateral surface. Increased joint space is also noted. Sclerosis is noted in the articular surface of the left second metatarsal head.

conservatively with nonsteroidal anti-inflammatory drugs, rest, and modification of activities. She stopped going to her dance classes. She did not participate in any weight-bearing activities. After 2.5 months of her follow-up, she was symptom-free and could walk on the ground without having any pain and her follow-up X-ray findings were similar to old findings. After another 5 months, she was asked to do a follow-up X-ray for further management but she did not come and we called her through phone but she was not compliant

to visit hospital again and had resumed her dancing practice again but with mild pain. She was advised not to practice dance or any other strenuous activities. She was given medication for pain during her discharge.

Discussion

Freiberg's infarction is the disorder of cartilage degeneration which was first explained in six patients with forefoot pain by Freiberg in 1914.² The second metatarsal head is most vulnerable to Freiberg's infarction due to its longer length and relative immobility. It is exposed to repetitive stress even during normal activity.⁴ The multifactorial etiology of Freiberg's infarction is mentioned in the literature. It commonly affects the adolescent female with a female-to-male ratio of 5:1. High prevalence in adolescent females is explained in some literature due to wearing high heels, which leads to repetitive forced dorsiflexion injury to the metatarsal head.⁴ Our case is an adolescent female of 20 years who was participating in dancing for 5 months. Pain in the second metatarsophalangeal joint is the most common symptom of Freiberg's disease. Other clinical features include swelling, deformity, redness, and difficulty in walking. With the advancement of the disease, it shows malalignment and deformity.⁶ Our patient also complained of constant dull aching pain which aggravated on walking. No obvious deformity or malalignment was seen. Radiography is helpful for the confirmation of diagnosis. In radiography, there is a flattening of the metatarsal head with the widening of the joint space.⁴ Fragmentation, sclerosis, and cortical thickening can be seen in the advanced stage.² In the early stage, MRI is more sensitive than radiography. MRI shows marrow edema, collapse, and hypointensity in the metatarsal head.⁴ This case belongs to Stage 2 on Smillie Classification System (Figure 1(a)–(d)). Nonoperative management helps in decreasing foot pressure and unloading the affected metatarsal. According to Smillie, there is the possibility of spontaneous healing at any stage, and restoration of normal function may occur in stages 1–3. As the articular cartilage is nonvascular, it is not affected by the ischemic condition of the underlying bone.⁷ Conservative management reduces foot pain and halts the progression to advanced stages. A variable surgical technique is explained for Freiberg's infarction in literature if conservative management fails. Although all the procedures are associated with a successful outcome, no sufficient evidence is available regarding the superiority of one procedure to the other.⁸

Conclusion

We presented our case due to its bilateral involvement which is of a rare type. Only a few cases of bilateral metatarsal head involvement in adolescent females are explained in the literature. Our case is also associated with dancing activities. It also describes use of conservative management especially in a noncompliant patient.

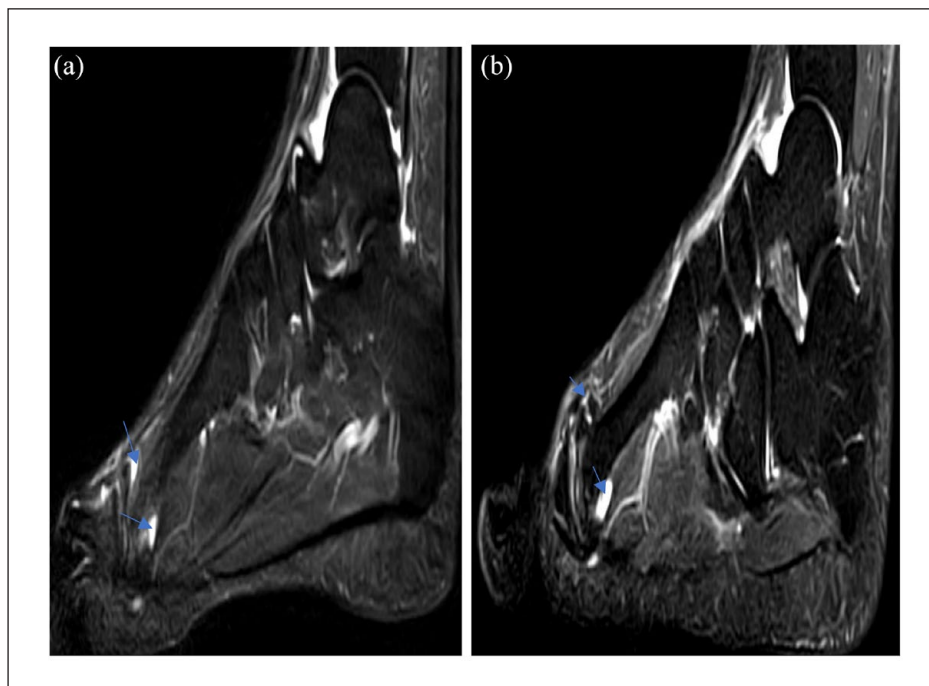


Figure 2. (a) Plain T2 fat-sat MRI of right foot showing high signal intensity in the head of first metatarsal in dorsal and plantar aspects (blue arrow). High signal marrow edema is also noted. (b) Plain T2 fat-sat MRI of the left foot showing high signal intensity in the head of first metatarsal in dorsal and plantar aspects (blue arrow).

Acknowledgements

None.

Author contribution statement

All authors contributed to the conduct of this research and read and approved the final version of the article. Written informed consent was obtained from the patient party to publish this report in accordance with the journal's "patient consent policy" on the title page of the article.

Data availability

The data supporting the findings in this case are available upon request to the corresponding author.

Declaration of conflicting interests

The author(s) declared no potential conflicts of interest with respect to the research, authorship, and/or publication of this article.

Funding

The author(s) received no financial support for the research, authorship, and/or publication of this article.

Ethics approval

Our institution does not require ethical approval for reporting individual cases or case series.

Informed consent

Written informed consent was obtained from the patient for anonymized patient information to be published in this article.

ORCID iDs

Shailendra Katwal  <https://orcid.org/0000-0001-7903-8789>

Sarad Katuwal  <https://orcid.org/0000-0002-4130-3329>

References

1. John Donaldson C, Harb Z, Hussain L, et al. Freiberg's disease of bilateral and adjacent metatarsals. *Case Rep Orthop Res* 2020; 3: 25–33.
2. Talusan PG, Diaz-Collado PJ and Reach JS. Freiberg's infraction: diagnosis and treatment. *Foot Ankle Spec* 2014; 7(1): 52–56.
3. Maresca G, Adriani E, Falez F, et al. Arthroscopic treatment of bilateral Freiberg's infraction. *Arthroscopy* 1996; 12(1): 103–108.
4. Carmont MR, Rees RJ and Blundell CM. Current concepts review: Freiberg's disease. *Foot Ankle Int* 2009; 30(2): 167–176.
5. Cerrato RA. Freiberg's disease. *Foot Ankle Clin* 2011; 16(4): 647–658.
6. Shane A, Reeves C, Wobst G, et al. Second metatarsophalangeal joint pathology and freiberg disease. *Clin Podiatr Med Surg* 2013; 30(3): 313–325.
7. Smillie IS. Treatment of Freiberg's infraction. *Proc R Soc Med* 1967; 60(1): 29–31.
8. Schade VL. Surgical management of Freiberg's infraction: a systematic review. *Foot Ankle Spec* 2015; 8(6): 498–519.