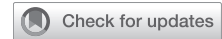

Robotic repair of a large chronic traumatic diaphragmatic hernia



Shubham Gulati, MS,^{a,b} M. Blair Marshall, MD,^c and Ealaf Shemmeri, MD, PharmD,^b New York, NY; Boston, Mass; and Sarasota, Fla

From the ^aIcahn School of Medicine at Mount Sinai, New York, NY; ^bDivision of Thoracic Surgery, Brigham and Women's Hospital, Harvard Medical School, Boston, Mass; and ^cDivision of Thoracic Surgery, Sarasota Memorial Hospital, Sarasota, Fla.

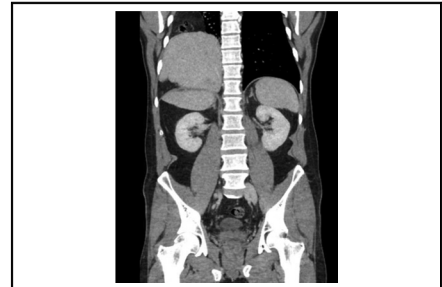Received for publication Aug 25, 2023; revisions received Sept 26, 2023; accepted for publication Oct 3, 2023; available ahead of print Oct 13, 2023.

Address for reprints: Shubham Gulati, MS, Icahn School of Medicine at Mount Sinai, One Gustave L. Levy Place, Box 1255, New York, NY 10029 (E-mail: shubham.gulati@icahn.mssm.edu).

JTCVS Techniques 2023;22:331-3
2666-2507

Copyright © 2023 The Author(s). Published by Elsevier Inc. on behalf of The American Association for Thoracic Surgery. This is an open access article under the CC BY-NC-ND license (<http://creativecommons.org/licenses/by-nc-nd/4.0/>).

<https://doi.org/10.1016/j.jtc.2023.10.002>



A large chronic traumatic diaphragmatic hernia: CT highlights the liver in the chest.

CENTRAL MESSAGE

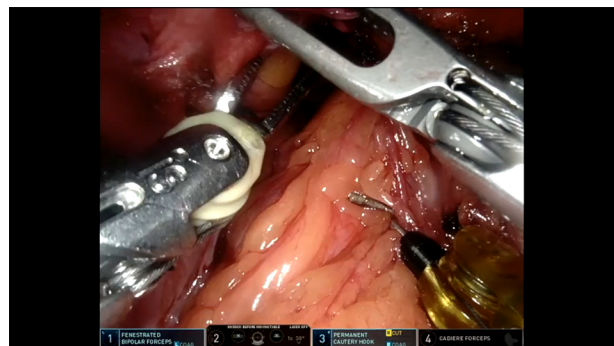
We demonstrate the technical strategies for a large traumatic diaphragmatic hernia repair involving the liver.

Video clip is available online.

Diaphragmatic hernia (DH) represents a rare, potentially life-threatening condition, with traumatic diaphragmatic hernia (TDH) as a result of thoracoabdominal injury accounting for 10% to 30% of cases.¹ TDHs are more rarely localized to the right side because of the protective effect of the liver.² Further, patients may remain asymptomatic for a number of years and can present with nonspecific respiratory and gastrointestinal symptoms.³ Once diagnosed, guidelines recommend surgical repair.³ Laparoscopic, thoracoscopic, and combined approaches have all been described previously.¹ The abdominal approach provides access to the retrohepatic vena cava, whereas the thoracic approach allows better access to pleural adhesions for decortication. While minimally invasive approaches have emerged, reports of robotic DH repair remain limited, with few cases highlighting the robotic repair of congenital DH.³ Two reports highlight the robotic repair of chronic TDH; however, one describes the transthoracic approach, whereas the other describes a transabdominal approach complicated by a gastrobronchial fistula as a result of technical error during TDH repair.^{4,5} We present details for the transabdominal robotic repair of chronic right-sided TDH with technical strategies used to avoid complications (Video 1). We planned a complete abdominal approach, but the right chest was exposed and accessible in case thoracoscopic access became necessary. During the case, we found no pleural adhesions requiring access from the chest. Institutional review board approval was not required; the patient provided informed written consent for the use and publication of deidentified information.

A 36-year-old male patient with a history of a motor vehicle accident at age 18 years presented to the emergency department with complaints of right-abdominal pain. A computed tomography scan demonstrated a large right-sided diaphragmatic hernia, with a significant portion of his liver, right colon, appendix, gallbladder, omentum, and associated mesentery in the chest without obstruction (Figure 1).

The patient was referred to thoracic surgery. In the emergency department, the patient's pain resolved, and he was scheduled for semielective robotic repair. In the operating room, the patient was placed in a right modified decubitus position with a bump under the right chest wall, ensuring access to the chest in case of an additional thoracoscopic approach.



VIDEO 1. Comprehensive case video. Video available at: [https://www.jtcvs.org/article/S2666-2507\(23\)00381-4/fulltext](https://www.jtcvs.org/article/S2666-2507(23)00381-4/fulltext).

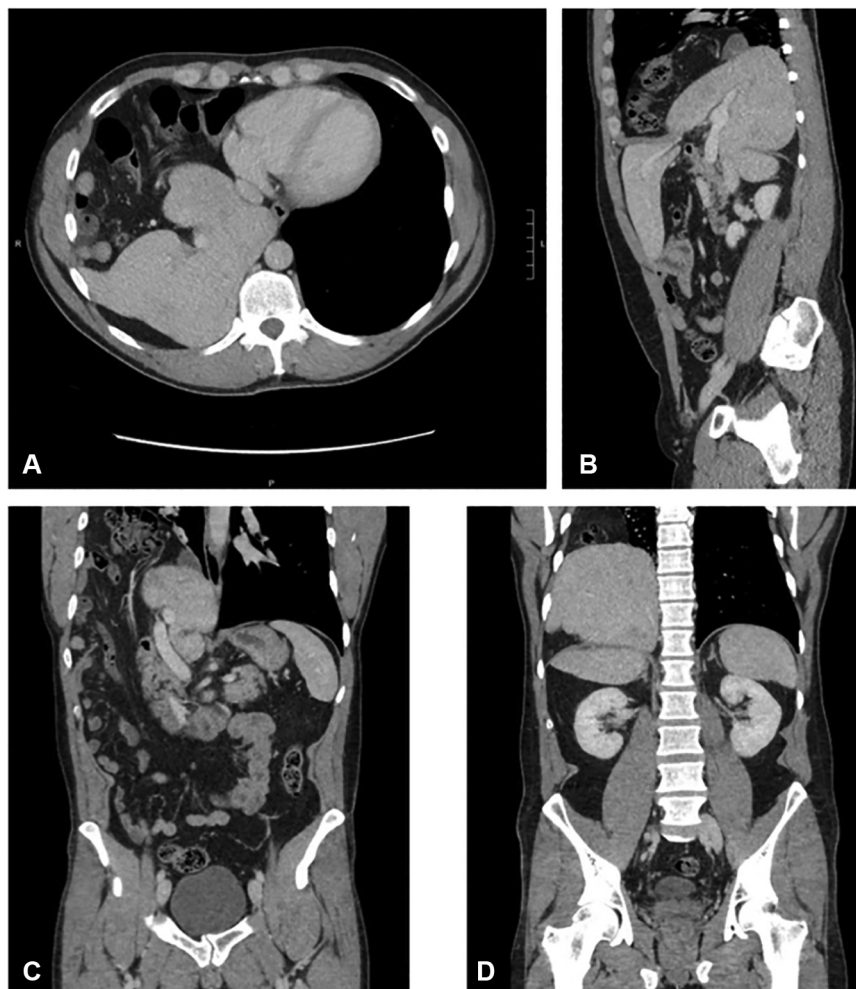


FIGURE 1. (A) Axial, (B) sagittal, and (C, D) coronal computed tomography images demonstrate the herniation of abdominal organs into the chest: a case of large traumatic diaphragmatic hernia. (C) Abdominal contents, including the portal vein, are herniated into the chest. (D) The liver can be seen above and below the diaphragm.

We placed 4 robotic ports across the mid-abdomen (Figure 2, A): from right to left, this included fenestrated bipolar forceps, 30° camera, hook cautery, and Cadière forceps. An assistant port was placed in the left-lower quadrant. Capnothorax was achieved with CO₂ pressures of 5 to 8 mm Hg with no hemodynamic issues. We began by careful reduction of the omentum and then dissection of adhesions along the anterior rim of the diaphragmatic defect, allowing improved visualization. Eversion of the diaphragm and limited lysis of adhesions on the thoracic side was performed, providing improved mobility of the remainder of omentum and colon. The dissection allowed for atraumatic reduction of the right colon and appendix with its associated mesentery. Because of the fragility of the hepatic parenchyma, reduction of the liver was done delicately. We were able to grasp the gallbladder mesentery and reduce part of the herniated liver. However, the remainder of the liver was reduced with a Valsalva maneuver from our anesthesia colleagues. Once the

liver was returned to the anatomic position, we dissected the posterior diaphragmatic defect away from the middle hepatic vein as it went from the patient's right to its junction with the suprahepatic inferior vena cava. A small portion of attenuated diaphragm was resected, given concern for its strength. Next, the 9-cm defect was primarily repaired with figure-of-eight 0-Ethibond (Ethicon) sutures with pledgets. The capnothorax was resolved using a red rubber catheter and a second Valsalva maneuver. A 15- × 20-cm reinforcing polypropylene/polyglycolic acid dual-sided mesh (Ventralex ST; Bard Davol) was added using the ProTack 5-mm device with helical titanium tacks (Medtronic) via the assistant port and VICRYL (Ethicon) sutures, based on surgeon preference and for added support. On postoperative day 1, the patient had mild pleural pain due to residual capnothorax. This was drained with a pigtail catheter to provide relief. The patient was discharged to home on postoperative day 2 and told to avoid heavy lifting for 1 month. Postoperative follow-up

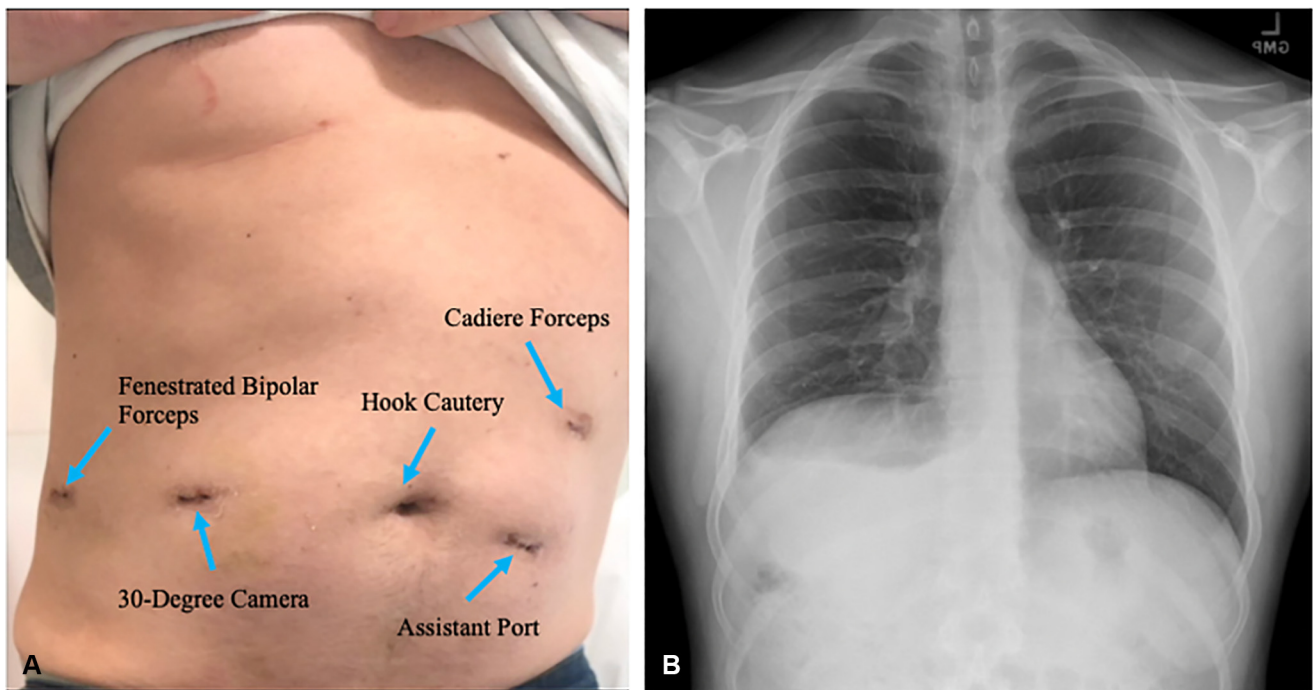


FIGURE 2. (A) Postoperative image highlighting the abdominal incisions made for port placement and instruments used in each port (B) Postoperative radiograph demonstrates resolution of the hernia.

demonstrated resolution of the hernia on radiograph (Figure 2, B). At 6-month surveillance screening, patient was asymptomatic, and radiograph showed no recurrence.

This case provides technical strategies for a transabdominal robotic approach for the correction of a large traumatic hernia, highlighting eversion of the diaphragm and use of Valsalva maneuvers for atraumatic reduction of herniated organs. Although the literature is lacking on the robotic approach for correction of TDH, we demonstrate that this approach is both feasible and safe.

Conflict of Interest Statement

Dr Marshall has received honoraria and grant funding from Intuitive Inc. and honoraria from Siemens Inc. All other authors reported no conflicts of interest.

The *Journal* policy requires editors and reviewers to disclose conflicts of interest and to decline handling or reviewing manuscripts for which they may have a conflict of

interest. The editors and reviewers of this article have no conflicts of interest.

References

1. Fernández-Moreno MC, Barrios Carvajal ME, López Mozos F, Garcés Albir M, Martí Obiol R, Ortega J. When laparoscopic repair is feasible for diaphragmatic hernia in adults? A retrospective study and literature review. *Surg Endosc.* 2022; 36:3347-55. <https://doi.org/10.1007/s00464-021-08651-3>
2. Guner A, Ozkan OF, Bekar Y, Kece C, Kaya U, Reis E. Management of delayed presentation of a right-side traumatic diaphragmatic rupture. *World J Surg.* 2012; 36:260-5. <https://doi.org/10.1007/s00268-011-1362-6>
3. Giuffrida M, Perrone G, Abu-Zidan F, Agnoletti V, Ansaloni L, Baiocchi GL, et al. Management of complicated diaphragmatic hernia in the acute setting: a WSES position paper. *World J Emerg Surg.* 2023;18:43. <https://doi.org/10.1186/s13017-023-00510-x>
4. Counts SJ, Saffarzadeh AG, Blasberg JD, Kim AW. Robotic transthoracic primary repair of a diaphragmatic hernia and reduction of an intrathoracic liver. *Innovations (Phila).* 2018;13:54-5. <https://doi.org/10.1097/imi.0000000000000455>
5. Tung JT, Lucero LM, Davis JW, Sue LP. Gastrobronchial fistula after robotic repair of traumatic diaphragmatic hernia. *Case Rep Surg.* 2020;2020:8085425. <https://doi.org/10.1155/2020/8085425>