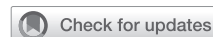

The hemi-commando procedure



Jose L. Navia, MD, FACC, and Rene Aleman, MD, Weston, Fla

From the Heart, Vascular, & Thoracic Institute, Cleveland Clinic Florida, Weston, Fla.

Received for publication July 30, 2023; revisions received Sept 20, 2023; accepted for publication Oct 3, 2023; available ahead of print Oct 10, 2023.

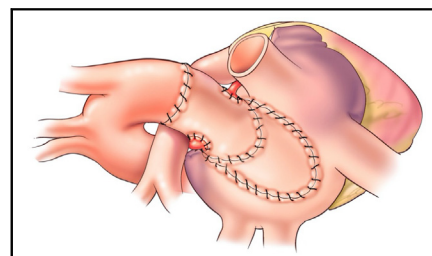
Address for reprints: Jose L. Navia, MD, FACC, Heart, Vascular & Thoracic Institute, Cleveland Clinic Florida, 2950 Cleveland Clinic Blvd, Weston, FL 33331 (E-mail: NAVIAJ@CCF.ORG).

JTCVS Techniques 2023;22:88-9

2666-2507

Copyright © 2023 The Author(s). Published by Elsevier Inc. on behalf of The American Association for Thoracic Surgery. This is an open access article under the CC BY-NC-ND license (<http://creativecommons.org/licenses/by-nc-nd/4.0/>).

<https://doi.org/10.1016/j.jtc.2023.10.005>



Hemi-commando procedure with homograft replacement of the AV and MV preservation.

CENTRAL MESSAGE

Inherently, the advantage of the hemi-commando procedure is that of significant native mitral valve preservation. We herein describe an auspicious technique for multiple-valve infective endocarditis.

Video clip is available online.

A 64-year-old woman with a history of mechanical aortic valve repair was referred for surgical evaluation. The patient presented with fever, weight loss, and shortness of breath. Preoperative assessment revealed a positive blood culture with *Escherichia coli* and complete atrioventricular block. A left heart catheterization evidenced normal-functioning coronary arteries and a dehiscence mobile prosthetic aortic valve (AV). Preoperative transesophageal echocardiography showed multiple mobile echo-densities attached to the AV prosthesis, a large echo-lucent space around the aortic root, thickening of the intervalvular fibrous body (IVF), and a moderate +2 mitral valve regurgitation.

The patient underwent an elective hemi-commando procedure due to bivalvular infective endocarditis and involvement of the IVF. Upon median sternotomy, large vegetations were noticed around the aortic prosthesis, IVF and MV, and large abscesses around the aortic root. The prosthetic valve was removed and was followed by a thorough excision of the infected tissues. An aortic homograft including the aortomitral membrane, the ascending aorta, and the anterior leaflet of the MV was transplanted intact as a unit. Subsequently, an annuloplasty ring was placed around the MV. Before closure of the median sternotomy, intraoperative transesophageal echocardiography showed normal AV homograft function and trivial mitral valve regurgitation, with preserved hemodynamics. The procedure was well tolerated, with no immediate complications reported in the postoperative period (Figure 1).

DISCUSSION

In the presence of extensive multivalvular infection, the hemi-commando procedure has shown commendable outcomes on account of its native MV-preservation principle. This procedure is reserved for patients with root pathology requiring repair and involvement of the aortomitral continuity and IVF body.¹ Although the prerequisites are an intact posterior MV leaflet and free edge on the anterior leaflet, its performance on prioritizing MV preservation is associated with improved early- and mid-term outcomes.^{2,3} The exposure of the left atrium conveys optimal exposure of the MV, facilitating infected tissue resection. The integrity of the left heart is restored with an aortomitral homograft. Furthermore, a MV ring or band is necessary to stabilize the intertrigonal area connected to the new IVF, thus avoiding hypermobility of the anterior leaflet into the left ventricular outflow tract. Ultimately, the innate preserving nature of said procedure spares valvular dynamics despite its high complexity.

Conflict of Interest Statement

The authors reported no conflicts of interest.

The *Journal* policy requires editors and reviewers to disclose conflicts of interest and to decline handling or

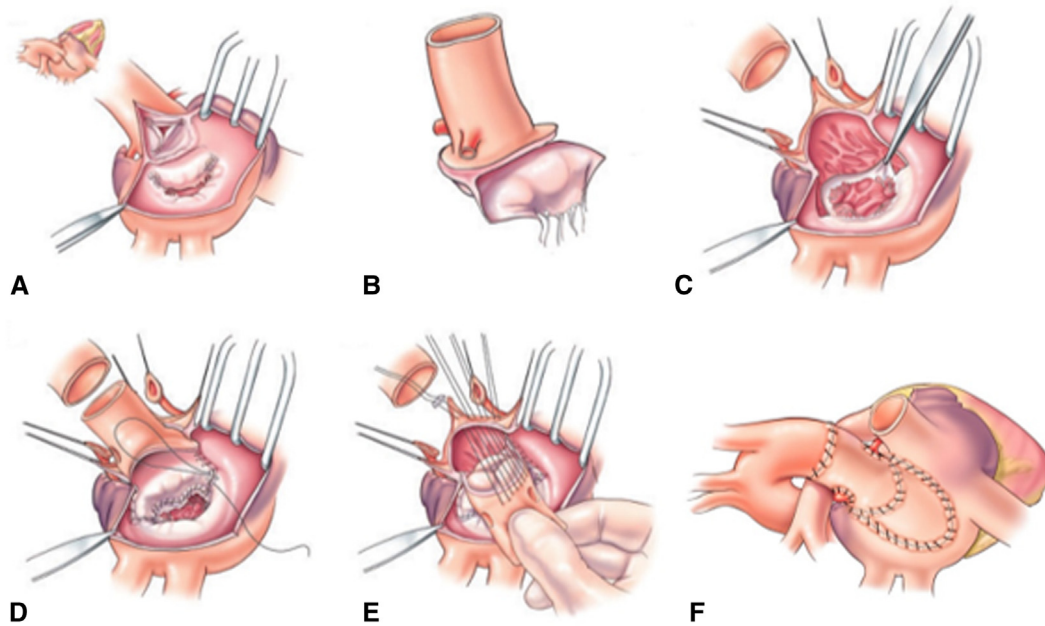
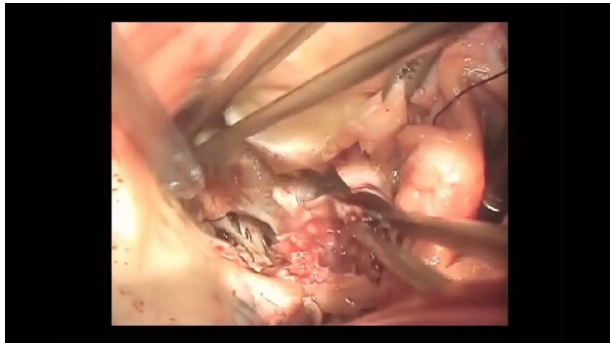


FIGURE 1. A-C, Resection of the aortomitral continuity and IVF prior to aortic homograft placement including the aortomitral membrane, ascending aorta, and anterior leaflet of the MV. D-F, MV annuloplasty ring placement and closure.



VIDEO 1. Stepwise approach of the hemi-commando procedure. Video available at: [https://www.jtcvs.org/article/S2666-2507\(23\)00383-8/fulltext](https://www.jtcvs.org/article/S2666-2507(23)00383-8/fulltext).

reviewing manuscripts for which they may have a conflict of interest. The editors and reviewers of this article have no conflicts of interest.

References

1. Vojacek J, Zacek P, Ondrasek J. Multiple valve endocarditis: a hemi-commando procedure. *Ann Cardiothorac Surg.* 2019;8:705-7. <https://doi.org/10.21037/acs.2019.07.07>
2. Navia JL, Elgharably H, Hakim AH, Witten JC, Haupt MJ, Germano E, et al. Long-term outcomes of surgery for invasive valvular endocarditis involving the aortomitral fibrosa. *Ann Thorac Surg.* 2019;108:1314-23. <https://doi.org/10.1016/j.athoracsur.2019.04.119>
3. Elgharably H, Hakim AH, Unai S, Hussain ST, Shrestha NK, Gordon S, et al. The incorporated aortomitral homograft for double-valve endocarditis: the 'hemi-Commando' procedure. Early and mid-term outcomes. *Eur J Cardiothorac Surg.* 2018;53:1055-61. <https://doi.org/10.1093/ejcts/ezx439>